

Managing Hand Fractures: 15 Years Experience from a Tertiary Care Hospital from Pakistan

Fahad Hanif Khan*, Mirza Shehab Afzal Beg

Department of Plastic Surgery, Liaquat National Hospital, Pakistan

***Corresponding author:** Fahad Hanif Khan, Department of Plastic Surgery, Liaquat National Hospital, National stadium road, 74800, Karachi, Pakistan. Tel: +922134140014; Fax: +923333032360; Email: dr.fhkhan@hotmail.com

Citation: Khan FH, Afzal Beg MS (2017) Managing Hand Fractures: 15 Years Experience from a Tertiary Care Hospital from Pakistan. J Surg: JSUR-196. DOI: 10.29011/2575-9760.000096

Received Date: 12 December, 2017; **Accepted Date:** 18 December, 2017; **Published Date:** 24 December, 2017

Abstract

Background: Fractures of hand bones predisposes a man to great disability by restricting daily working ability. We want to share our experience of dealing with hand fractures and its outcome in hand injuries.

Methods: 15 years of data was retrieved from a tertiary care hospital and analyzed for age, gender, comorbidities, etiology, fractures involved, management and outcome in terms of days to return to daily activities.

Results: We managed 969 patients with hand bones fractures, which had total of 1764 bones involved. Median age of presentation was 41 years. Carpal bones accounted for 187 (10.6%), metacarpals 627 (35.5%) and phalanges 950 (53.8%). Most were managed with K-wires (63.2%) and screws (3.9%) with return of daily activity was within 45 ± 10 days. Most common complication was soft tissue infections followed by osteomyelitis due to nature of injuries.

Conclusion: Early surgical management and mobilization of hand after fractures fixation remains vital for good functional outcome of hand. Close follow up is required for timely intervention of associated complications.

Keywords: Carpal Bones; Fractures; Hand Injuries; Surgical Options

Introduction

Hand fractures contribute to major disability for a man. Being third eye of the body, injuries of hand not only hampers function but also disturb earning of a home. Though many fractures of hand can be treated non-operatively but most, if not intervened, will result in hand deformity or stiffness [1,2]. Multidisciplinary team interventions are required for maximum functional return of hand, with most important role played by hand surgeon whose skills are paramount in early phase of management. In United States there was bimodal pattern of distribution of age in patients with hand fractures with majority had meta-carpal bones involvement [3]. Another retrospective study from Saudi Arabia, over a period of 6 years, showed that among the age group of 13-18 years most hand fractures occurred in home [4]. In an Indian study on patients attending in accident and emergency department with fractures, 5.4% had hand fractures [5]. Many authors have presented

rationale and principles of managing hand fractures [6-8], with majority emphasize on surgical management in the initial phase of fractures for stabilization. Phalanges and metacarpal fractures account for most of hand fractures [9,10]. Surgical options ranges from Krischner (K-) wiring, metallic plates, external fixation or screw fixation [11,12]. Study from Pakistan showed good post-operative range of motion after K-wire placement in phalangeal and meta-carpal fractures [10]. We aim to share our 15 years of experience in managing hand fractures including carpal bones in a tertiary care center with multidisciplinary team.

Methods

This is a retrospective observational study over a period of 15 years (May, 2000 to January, 2016), conducted at the department of plastic surgery, at a private hospital in Karachi, Pakistan. This department is unique as it is the only unit in the city with two hand surgeons, who offers training in hand fellowship. This is a private tertiary care hospital with 700 beds and serving for more than 50 years. Due to this specialized department, this hospital has

privilege of dealing with referrals for hand injuries not only from this country but also from neighboring countries like Afghanistan, especially over the last one decade. It is departmental policy to inform patients about the use of data for future research purposes ensuring their anonymity. The institutional ethical review board has approved this study. We have retrieved 15 years of data and reviewed them for injuries specifically looking for fractures of hand bones, its management and outcomes. The data was analyzed for age, gender, etiology of injury, comorbidities, fracture sites, management opted and outcome in terms of days to return of daily activities. The data was analyzed for mean and frequencies using Statistical Package for Social Sciences (SPSS) version 19.0. Chi-square test with confidence interval of 95% was used for significant co-relations.

1. Results

In the last 15 years we managed 1859 patients with hand injuries, in which 969 had underlying bone fractures. Male (608; mean age 31.5 ± 8 years) to female (361; mean age 38 ± 6 years) ratio was 1.6:1, with median age of 41 years (range: 6 - 58 years). Most patients had right hand dominance, 930 (92%), with 459 (47.3%) patients had skilled jobs. Four hundred and ninety-two (81%) men had addiction to smoking, while 141 (39%) of women had systemic joint diseases (osteoporosis: 26.9%, osteoarthritis: 43.2%, rheumatoid disease: 29.7%). In our observation motor vehicle accidents dominated the etiology of hand fractures (Figure 1).

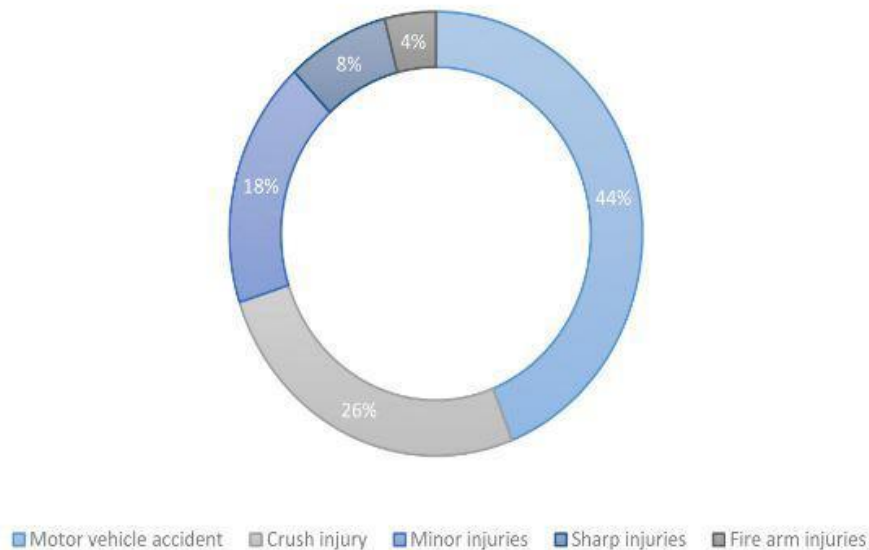


Figure 1: Motor vehicle accident accounting for 426 (44%) of the cases, followed by crush injuries 251 (26%; trap door injury: 12%), minor injuries 174 (18%; punching: 6%, slip down: 12%) and sharp cut injuries 77 (8%).

Two-dimensional X-ray views were used to diagnose the fractures, however computed topography (CT) scan was also used in selected carpal bone injuries.

Table 1 shows distribution of 1764 fractures in different bones of hand, with majority involved phalanges of 3rd and 4th digits (528), meta-carpals of 3rd (145), 4th (128), and 5th (156). One hundred and eighty-seven (10.6%) of carpal fractures, 42 (22.4) had scaphoid fractures, 29 (15.5) had lunate fractures and 28 (14.9%) had crush injuries of carpal rows. Sum of open fractures were 524 (29.7%), in contrast to 1240 (70.1%) closed fractures. An additional 274 (22%) closed fractures were reduced via open approach (Table 2).

SITES		n (%)
Carpals	Scaphoid	42 (22.4)
	Lunate	29 (15.5)
	Trapezium	19 (10.1)
	Pisiform	13 (6.9)
	Trapezoid	20 (10.6)
	Triquetrum	18 (9.6)
	Capitate	28 (14.9)
	Hamate	18 (9.6)
Metacarpals 627 (35.5%)	1 st	106 (16.9)
	2 nd	92 (14.6)
	3 rd	145 (23.1)
	4 th	128 (20.4)
	5 th	156 (24.8)
Phalanges 950 (53.8%)	1 st	131 (13.7)
	2 nd	200 (21.0)
	3 rd	219 (23.0)
	4 th	275 (28.9)
	5 th	42 (22.4)

Table 1: Fracture sites (n=1764).

BONE	SITE	INVESTIGATION	MANAGEMENT	UNION RATE	COMPLICATION
Phalanges (950)	Distal (425)	X-rays only	K-wire	95%	Fibrous union (96)
			Conservative	83%	
	Middle (210)		K-wire	95%	DIPJ arthrodesis (13)
	Proximal (315)		K-wire	96%	Fibrous union (16)
External fixator		72%			
Metacarpals (627)	Head (285)	X-rays only	K-wire	98%	Non-union (6)
			Conservative	84%	
	Shaft (305)		K-wire	91%	Fibrous union (12)
			Plate	98%	
			External fixator	68%	
	Base (237)		K-wire	94%	
			Screws	98%	
Carpals (187)		X-rays (120)	Conservative	65%	Tender screw site (12)
		CT-scan (67)	K-wire	92%	
			Screw	98%	

Table 2: Management of fractures according to site (n=1764).

Table 2 shows details of our patient’s management in which 1061 (60.1%) fractures were dealt with K- wires, 69 (3.9%) screw fixations (mostly for carpal fractures), external fixation in 48 (2.7%), 35 (19.8%) with plates and row carpectomy in 28 (2.8%) patients. Three hundred and sixty patients (37.1%) had early or late amputation of a digit. 163 (9.2%) were managed conservatively as discussed.

Outcomes

Nine hundred and ten (94%) patients were followed for once per week for a minimum of 8 weeks. Post-operative splints were removed at 4 weeks (6 weeks for conservatively managed) and patients were advised night splints for 2 more weeks with physiotherapy to improve range of movements of joints. Sutures were removed at 10-14 days and K-wires at 6 weeks post-operatively, after getting a follow-up X-ray film. Three hundred and seventy-five (21.2%) patients had secondary procedures (Table 3).

COMPLICATIONS	n (%)
Soft tissue infection	152 (40.5)
Osteomyelitis	84 (22.4)
Delayed necrosis of digit	74 (19.7)
Arthrodesis	34 (9)
Non-union	15 (4)
Mal union	16 (4.2)

Table 3: Post-operative complications (n=345).

Mostly 52 (13.8%) requiring out-patient based wound debrided and 87 (23.2%) had late amputation of digit (after 24 hours of intervention). Mean days to return to daily activity was 45 ± 10 (p-value: 0.04), with light weight bearing (2 pounds). Mean day for finger to palm distance to reach ≤1 cm for phalangeal fractures was 18±7 days. At 8 weeks follow up mode flexion angles at meta-carpo-phalangeal joint (MCPJ) was 50° (p-value: 0.06), proximal inter-phalangeal joint (PIPJ; p-value: 0.10) was 70° and at distal inter-phalangeal joint (DIPJ; p-value: 0.08) was 10°.

Discussion

Hand fractures are common injuries, which poses difficulties for hand surgeons. The treatment has to be individualized depending on site and pattern of fracture, with goals to restore congruity, stability and alignment thus allowing early range of motion and preventing stiffness and arthritis. Occurring most commonly in males in their thirties to forties [13,14], as seen in our observation too. Up to 34% of fractures are secondary to trauma or industrial injuries (crush and machine sharp cut) [15], while other causes include trivial injuries. The complex anatomical arrangement of the eight carpal bones, maintained by ligaments, makes it difficult for fractures to be seen in simple radiographs, thus requiring Computed Topography. About 8 to 19% of hand injuries results in

carpal bones injuries, with 90% damaging proximal row [16,17]. We observed 22.4% scaphoid, 15.5% lunate, 14.9% capitate fractures as compared to a study, evaluating carpal bones involvement in distal radius fractures, showed triquetrum, lunate and scaphoid in decreasing frequencies [17]. We managed scaphoid using AO lag screws (2mm mini fragment) with change in trend to cannulated compression screws (2.4mm) in our unit over the past few years. Indication of intervention included greater than 1 mm of displacement, lateral intrascaphoid angle greater than 35 degrees, bone loss or comminuted fracture, perilunate fracture or dislocation and proximal pole fractures. Metacarpal fractures account for the most of hand fractures, as in literature it makes up 40% of all hand fractures as compared to our observation of 35.5% [18]. Even than phalangeal fractures make up 53.8% in our study. ‘Boxer’s fracture’ as labelled by many authors [18-20], 5th metacarpal bone fracture, comprises of 24.8% of all metacarpal fractures in our series. Phalanges were managed with K-wires, but those with undisplaced, incomplete or those stable after closed reduction were managed conservatively.

Surgical options were chosen for open, intra-articular, unstable (oblique, comminuted, transverse), irreducible fractures and those with angulation more than 30 degrees, however closed fractures, with angulation <30 degree and <10-degree rotation were managed conservatively. Surgical options range from placing K-wires to intraosseous wires, tension wire bands, compression screws, open reduction and internal fixation with plates and screws or external fixation [21], especially for phalanges fixation. From our study we managed most fractures with K-wires, both for phalanges and metacarpals, however compression screws were used for carpal fracture fixation especially in scaphoid fractures. Many patients required nail bed repair especially those having underlain distal phalangeal fracture. Conservative management comprised close reduction and splint in intrinsic plus position of James (70-degree flexion at metacarpo-phalangeal joint and 90-degree extension at distal and proximal inter-phalangeal joints) for at least 4 weeks [7,22]. Early mobilization is needed for good functional outcome of hand, irrespective of conservative or surgical management. Outcomes after hand fractures fixation has been assessed by objective, subjective or with radiologic improvements, however not a single measure has been accepted as the gold standard for accurately assessing functional improvement [13,15,23]. We assessed functional outcomes in terms of return to daily activities and angle of joint flexion on follow-up. As a team work with occupational and physiotherapists we observed early compliance to at least 2lb of weight bearing and house hold activities, with statistical significance as compared to joints mobility angles. We managed cases with soft tissue and bone infections, even after recommended initial washout, debridement and antibiotic coverage, which were related to nature of etiology [24].

Conclusion

With a number of modalities for surgical management, early intervention results in good and prompt return of hand functions, reducing joint stiffness and traumatic arthritis. Though vigilant team work and follow up is required in initial period for timely management of associated outcomes.

References

1. Swanson AB (1970) Fractures involving the digits of the hand. *OrthopClin North Am*: 261-274.
2. Giddins GE (2015) The non-operative management of hand fractures. *J Hand Surg Eur* 40: 33-41.
3. Immerman I, Livermore MS, Szabo RM (2014) Use of emergency department services for hand, wrist, and forearm fractures in the United States in 2008. *J SurgOrthop Adv* 23: 98-104.
4. Al-Jasser FS, Mandil AM, Al-Nafissi AM, Al-Ghamdi HA, Al-Qattan MM (2015) Epidemiology of pediatric hand fractures presenting to a university hospital in Central Saudi Arabia. *Saudi Med J* 36: 587-592.
5. Kumar K (2013) Scenario of hand fractures in a tertiary hospital: a prospective study. *Musculoskelet Surg* 97: 57-60.
6. Sammer DM, Husain T, Ramirez R (2013) Selection of appropriate treatment options for hand fractures. *Hand Clin* 29: 501-505.
7. Tang JB, Blazar PE, Giddins G, Lalonde D, Martinez C, et al. (2015) Overview of indications, preferred methods and technical tips for hand fractures from around the world. *J Hand Surg Eur* 40: 88-97.
8. Gaulke R, Spies M, Krettek C (2007) Fractures of the wrist and hand. Principles of conservative treatment. *Unfallchirurg* 110: 833-844.
9. Kamath JB, Harshvardhan, Naik DM, Bansal A (2011) Current concepts in managing fractures of metacarpal and phalanges. *Indian Journal of Plastic Surgery: Official Publication of the Association of Plastic Surgeons of India* 44: 203-211.
10. Shafiq M, Khan MJ, MW S (2016) Treatment of phalangeal and metacarpal fractures with k-wire. *Gomal J Med Sci* 14: 46-48.
11. Henry MH (2008) Fractures of the proximal phalanx and metacarpals in the hand: preferred methods of stabilization. *J Am Acad Orthop Surg* 16: 586-595.
12. Windolf J, Rueger JM, Werber KD, Eisenschenk A, Siebert H, et al. (2009) Treatment of metacarpal fractures. Recommendations of the Hand Surgery Group of the German Trauma Society. *Unfallchirurg* 112: 577-588.
13. Shimizu T, Omokawa S, Akahane M, Murata K, Nakano K, et al. (2012) Predictors of the postoperative range of finger motion for comminuted periarticular metacarpal and phalangeal fractures treated with a titanium plate. *Injury* 43: 940-945.
14. Omokawa S, Fujitani R, Dohi Y, Okawa T, Yajima H (2008) Prospective Outcomes of Comminuted Periarticular Metacarpal and Phalangeal Fractures Treated Using a Titanium Plate System. *Journal of Hand Surgery* 33: 857-863.
15. Baldwin PC and Wolf JM (2013) Outcomes of Hand Fracture Treatments. *Hand Clinics* 29: 621-630.
16. Raghupathi AK and Kumar P (2014) Nonscaphoid carpal injuries - Incidence and associated injuries. *Journal of Orthopaedics* 11: 91-95.
17. Heo YM, Kim SB, Yi JW, Lee JB, Park CY, et al. (2013) Evaluation of Associated Carpal Bone Fractures in Distal Radial Fractures. *Clinics in Orthopedic Surgery* 5: 98-104.
18. Haughton DN, Jordan D, Malahias M, Hindocha S, Khan W (2012) Principles of Hand Fracture Management. *The Open Orthopaedics Journal* 6: 43-53.
19. Weum S, Millerjord S, de Weerd L (2016) The distribution of hand fractures at the university hospital of north Norway. *J PlastSurg Hand Surg* 50: 146-150.
20. Kollitz KM, Hammert WC, Vedder NB, Huang JI (2014) Metacarpal fractures: treatment and complications. *Hand* 9: 16-23.
21. Meals C and Meals R (2013) Hand fractures: a review of current treatment strategies. *J Hand Surg Am* 38: 1021-1031.
22. Markiewitz AD (2013) Complications of Hand Fractures and Their Prevention. *Hand Clinics* 29: 601-620.
23. Novak CB, Williams MM, Conaty K (2015) Evaluation of the Patient-Specific Functional Scale in hand fractures and dislocations. *Hand (NY)* 10: 85-87.
24. Ruta D and Ozer K (2013) Open fractures of the hand with soft tissue loss. *Hand Clin* 29: 551-567.