

Case Report

Industrial Solvents: Underlying Potential Risks of Left-Sided Po-tal Hypertension Associated with Positive JAK2-V617F Gene

Zhong Jia^{1*}, Jun Lu¹, Jie Zhang¹, Chao-Jun Kong², Meng-Qi Chen²

¹Hangzhou First People's Hospital, Nanjing Medical University Affiliated Hangzhou Hospital & Zhejiang, China

²Chinese Medical University Fourth Affiliated Clinical Hospital, Hangzhou, Zhejiang, China

***Corresponding author:** Zhong Jia, Department of Hepatopancreatobiliary Surgery, Huansha Road No.261, Hangzhou First People's Hospital, Nanjing Medical University Affiliated Hangzhou Hospital, Hangzhou, Zhejiang 310006, China. Tel: +8613958114181; Fax: +86057187914773; Email: jiazhong20058@hotmail.com

Citation: Jia Z, Lu J, Zhang J, Kong C, Chen M (2017) Industrial Solvents: Underlying Potential Risks of Left-Sided Portal Hypertension Associated with Positive JAK2-V617F Gene. J Surg: JSUR-178. DOI: 10.29011/JSUR-178.000078.

Received Date: 15 October, 2017; **Accepted Date:** 30 October, 2017; **Published Date:** 06 November, 2017

Introduction

Left-sided portal hypertension is a rare disease, which is characterized as splenic vein occlusion, with presences of increasingly enlarged spleen and gastric varices and normal liver function [1-4]. Consequently, its clinical manifestation may be life-threatening blood vomiting due to undesired rupture of dilated upper gastrointestinal vessels. Regarding the causes of left-sided portal hypertension, ample evidence has shown that thrombotic occlusion of the splenic vein and portal vein is generally the primary one [5-7]. Meanwhile, pancreatic diseases like pancreatitis or pancreatic neoplasms are the main sources of such thrombosis, because the splenic vein traverses the pancreatic surface and the inflammatory or neoplastic pathologies can affect this vessel by a contiguity process [5]. In fact, non-pancreatogenous factors, such as idiopathic splenic vein stenosis and iatrogenic splenic vein injury, should also draw our attention [8]. Herein, a patient with positive JAK2-V617F gene met with left-sided portal hypertension. So, we could not help thinking whether there are any underlying connections between JAK2-V617F gene and left-sided portal hypertension. Now let us go further to unveil the conundrum.

Case Description

The most recently, we encountered a 51-year-old woman who suffered from her first episode of fresh blood vomiting and early satiety after 2 years work on spray paint in a private furniture factory. She highly suspected her disease was associated with her working environment because she had no abnormal medical history before working on spray paint with no safeguard measures against the paint solvents. Further abdominal computed tomography examination showed these specific findings including main portal vein thrombosis, splenic vein thrombosis, splenic vein stenosis, splenomegaly and gastric varices (Figure 1).

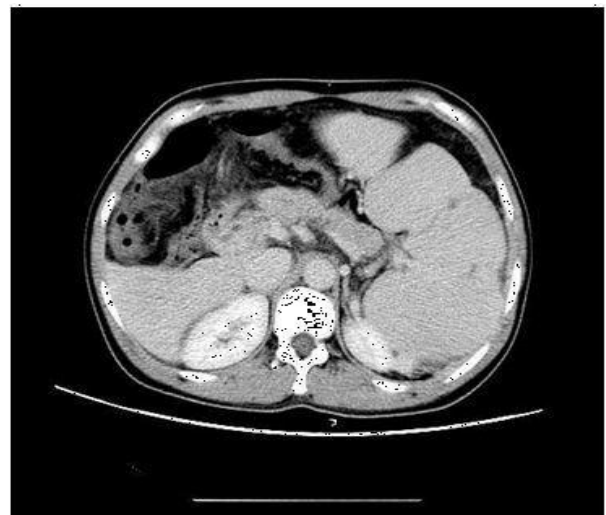


Figure 1: CT found the stenosis spleen vein and major portal vein thrombosis.

Thus, it was well-grounded to give the diagnosis of left-sided portal hypertension. Interestingly, the expression of JAK2-V617F in her peripheral blood was found positive. If these outcomes can be considered under a single roof, we may find the inner connections between these appearances.

Discussion

In reality, JAK2-V617F has been proved in connection with Myeloproliferative Neoplasms (MPNs) [9-10]. As we all know, MPNs are a group of hematopoietic stem cell disorders characterized by clonal proliferation of myeloid-lineage cells [11]. Classic MPNs include Polycythemia Vera (PV), Essential Thrombocythemia (ET), Primary Myelofibrosis (PMF), and Chronic Myeloid Leukemia (CML). The prevalence of a venous throm-

boembolism at the time of MPN diagnosis is estimated to be approximately 11–39% for PV, 8–29% for ET, and 3–7% for PMF [12–13]. Besides, MPNs are the most common underlying prothrombotic disorder found in patients diagnosed with Splanchnic Vein Thrombosis (SVT), which refers to thrombosis formation in the portal venous system, splenic venous system, hepatic venous system, or mesenteric venous system, in the absence of local inciting factors such as liver cirrhosis or nearby malignancy [14]. In a Korean study, 11.5% patients were detected positive JAK2-V617F gene among 26 patients with SVTs [15]. It is also possible that SVT patients with JAK2 V617F, but no overt clinical features of MPN, may represent a distinct subtype of MPN or an early phase of the disease. Interestingly, up to 70% of patients presenting with SVTs do not carry a prior diagnosis of MPN [16]. Not surprisingly, our patient was also in the absence of overt MPNs but with JAK2-V617F and SVTs.

Some studies have pointed out that JAK2-V617F mutation itself may have local effects on the splanchnic venous system in that blood flow velocity is much slower, leading to prolonged interactions between blood and endothelial cells [17,19]. The JAK2 mutation can work on the hematologic system as well. For example, JAK2-mutant megakaryocytes display hypersensitive signaling and increased mobility and aggregation [18, 19]. It is also believed that JAK2-positive patients have high level of leukocyte activation, which can lead to further platelet activation and aggregation [19]. Besides, some studies have identified the JAK2 mutation in spleen endothelial cells and circulating endothelial progenitor cells, so that these cells act out increased adherence to normal mononuclear cells [20]. These findings confirm the magnificent effects JAK2-V617F have on the formation of SVTs. Therefore, it's not hard to understand that the splenic and portal thrombosis can emerge on the patient with JAK2-V617F mutation. Consequently, the left-sided portal hypertension may also happen accordingly.

Up to date, the exact mechanism of JAK2-V617F mutation is still unclear, and the overwhelming majority of the patients with positive JAK2-V617F gene are still unable to find a particular incentive. Radiation, certain contrast agents and some industrial solvents (such as benzene, diethyl nitrosamine) may increase the risk of mutation. One study suggests that chronic exposure to chemicals plays a role in the formation of non-radiation associated RET/PTC rearrangements [21]. In this case, long-term working on spray paint was potentially dangerous as she had no safeguards to avoid direct contacts with industrial solvents. Her suspicion was not unnecessary and there was basis for such concern.

Conclusions

Generally, physicians suggest that non-surgical management is appropriate, otherwise, splenectomy may result in uncontrollable thrombocytosis; while surgeons think that they should take

adventure to resolve the life-threatening risk of bleeding by splenectomy first. Based on our previous experience, for patients with myeloid fibrosis, spleen arterial embolization or splenectomy is safe option despite of temporary sharply elevation of platelet number emerging. As long as proper steps including antiplatelet therapy and immune modulator drugs are taken in time, the increasing trend of platelet number can be ultimately controlled to normal range. In this case, the patient received laparoscopic splenectomy plus devascularization of gastric varices and wedge liver biopsy. The histopathology confirmed non-cirrhotic liver and congestive splenomegaly (Figure 2,3).

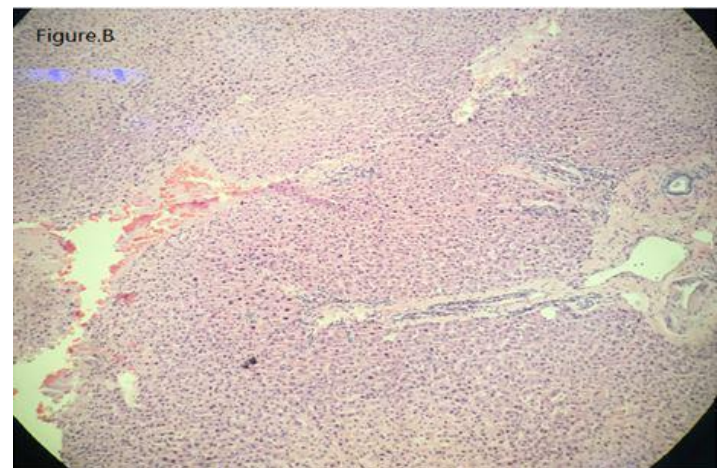


Figure 2: Liver biopsy sample confirmed a normal liver without cirrhotic features.

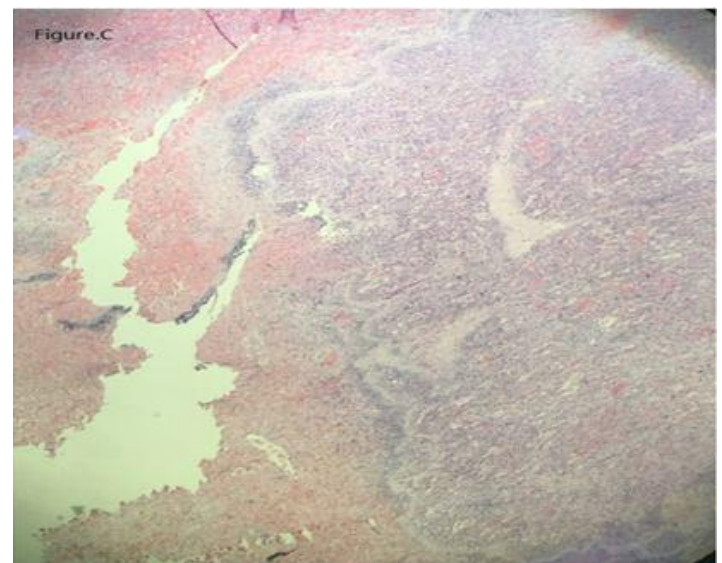


Figure 3: Spleen specimen unveiled a congestive spleen along with few point infarction.

As physicians had expected, the value of platelet climbed to the peak with 162, 4000/UL at the postoperative day 21, and

then declined gradually. On review, 3 months after surgery, the platelet count was within normal limits and no evidence of complications including rebleeding was found. This case was unique but instructive. For example, left-sided portal hypertension should be suspected in patients with upper gastrointestinal bleeding as well as unexplained splenomegaly with normal liver function, and surgical intervention such as splenectomy may offer a good out-come. Moreover, JAK2-V617F mutation is a high-risk factor of SVTs, which can lead to left-sided portal hypertension directly. As a result, safeguards are necessary to protect the workers from dangerous industrial solvents so that the possibility of JAK2-V617F mutation can be minimized.

References

1. Köklü S, Coban S, Yüksel O, Arhan M (2007) Left-Sided Portal Hypertension. *Dig Dis Sci* 52: 1141-1149.
2. Köklü S, Yüksel O, Arhan M, Coban S, Başar O, et al. (2005) Report of 24 Left-sided Portal Hypertension Cases: a Single-center Prospective Cohort Study. *Dig Dis Sci* 50: 976-982.
3. Hakim S, Bortman J, Orosey M, Cappell MS (2017) Case Report and Systematic Literature Review of a Novel Etiology of Sinistral Portal Hypertension Presenting with UGI Bleeding: Left Gastric Artery Pseudoaneurysm Compressing the Splenic Vein Treated by Embolization of the Pseudoaneurysm. *Medicine (Baltimore)* 96: e6413.
4. Hasan Ergenc, Ahmet Tarik Eminler, Ceyhan Varım, Cengiz Karacaer, Mustafa Ihsan Uslan, et al. (2015) Gastric Variceal Bleeding Related with Sinistral Portal Hypertension Occurring Secondary to Splenic Vein Thrombosis Developed as a Complication of Acute Pancreatitis. *Int J Adv Med* 2: 419-422.
5. Fernandes A, Almeida N, Ferreira A M, Casela A, Gomes D, et al. (2015) Left-Sided Portal Hypertension: A Sinister Entity. *GE Port J Gastroenterol* 22: 234-239.
6. Koklu S, Coban S, Yuksel O, Arhan M (2007) Left-sided Portal Hyper-tension. *Dig Dis Sci* 52: 1141-1149.
7. Wang L, Liu GJ, Chen YX, Dong HP, Wang LX (2012) Sinistral Portal Hypertension: Clinical Features and Surgical Treatment of Chronic Splenic Vein Occlusion. *Med Princ Pract* 21: 20-23.
8. Wong HK, Kuo HT, Tsai SL, Uen YH, Tzeng WS (2004) Isolated Gastric Varices Due to Focal Splenic Vein Stenosis. *J Formos Med Assoc* 103: 640-643.
9. Erba, B G, Gruppi C, Corada M, Pisati F, Rosti V, et al. (2017) Endothelial-to-Mesenchymal Transition in Bone Marrow and Spleen of Primary Myelofibrosis. *Am J Pathol* 187: 1879-1892.
10. Desterke C, Bilhou-Nabera C, Guerton B, Martinaud C, Tonetti C, et al. (2011) FLT3-mediated P38-MAPK Activation Participates in the Control of Megakaryopoiesis in Primary Myelofibrosis. *Cancer Res* 71: 2901-2915.
11. Tefferi A and Vardiman J (2008) Classification and Diagnosis of Myeloproliferative Neoplasms: the 2008 World Health Organization Criteria and Point-of-care Diagnostic Algorithms. *Leukemia* 22: 14-22.
12. Barbui T, Carobbio A, Cervantes F, Vannucchi A, Guglielmelli P, et al. (2010) Thrombosis in Primary Myelofibrosis: Incidence and Risk Factors. *Blood* 115: 778-782.
13. Kreher S, Ochsenreither S, Trappe R, Pabinger I, Bergmann F, Petrides P, et al. (2014) Prophylaxis and Management of Venous Thromboembolism In Patients with Myeloproliferative Neoplasms: Consensus Statement of the Haemostasis Working Party of the German Society of Hematology and Oncology (DGHO), the Austrian Society of Hematology and Oncology (OGHO) and Society of Thrombosis and Haemostasis Research (GTH e.V.). *Ann Hematol* 93: 1953-1963.
14. Ageno W, Dentali F, Squizzato A (2014) How I Treat Splanchnic Vein Thrombosis. *Blood* 124: 3685-3691.
15. Yoo E H, Jang J H, Park K J, Gwak G Y, Kim H J, et al. (2011) Prevalence of Overt Myeloproliferative Neoplasms and JAK2 V617F Mutation in Korean patients with Splanchnic Vein Thrombosis. *Int J Lab Hematol* 33: 471-476.
16. Hoekstra J, Bresser EL, Smalberg JH, Spaander MC, Leebeek FW, et al. (2011) Long-term Follow-up of Patients with Portal Vein Thrombosis and Myeloproliferative Neoplasms. *J Thromb Haemost* 9: 2208-2214.
17. Aird WC (2007) Phenotypic heterogeneity of the endothelium: II. Representative Vascular Beds. *Circ Res* 100: 174-190.
18. Hobbs CM, Manning H, Bennett C, Vasquez L, Severin S, et al. (2013) JAK2-V617F Leads to Intrinsic Changes in Platelet Formation and Reactivity in a Knock-in Mouse Model of Essential Thrombocythemia. *Blood* 122: 3787-3797.
19. How J, Zhou A, Oh S T (2017) Splanchnic Vein Thrombosis in Myeloproliferative Neoplasms: Pathophysiology and Molecular Mechanisms of Disease. *Ther Adv Hematol* 8: 107-118.
20. Teofili L, Martini M, Iachininoto MG, Capodimonti S, Nuzzolo ER, et al. (2011) Endothelial progenitor Cells are Clonal and Exhibit the JAK2(V617F) Mutation in a Subset of Thrombotic Patients with Ph-negative Myeloproliferative Neoplasms. *Blood* 117: 2700-2707.
21. Lehman C E, Dillon L W, Nikiforov Y E, Wang Y H (2017) DNA Fragile Site Breakage as a Measure of Chemical Exposure and Predictor of Individual Susceptibility to Form Oncogenic Rearrangements. *Carcinogenesis* 38: 293-301.