

## Arthroscopic Repair of Complete Tear of Rotator Cuff

Hamidreza Aslani\*, Fateme Mirzaee, Seyed Taghi Nourbakhsh, Mahmoud Reza Fayyaz, Zohreh

Zafarani Department of Orthopedic Surgery, Knee and Sport Medicine Research Center, Milad Hospital, Iran

\*Corresponding author: Hamidreza Aslani, Shahid Beheshti University of Medical Sciences, Knee and Sport Medicine Education Center, Milad Hospital, Tehran, Iran. Tel: +98-2188621147; Email: hraslani1342@gmail.com

Citation: Aslani H, Mirzaee F, Nourbakhsh ST, Fayyaz MR, Zafarani Z (2017) Arthroscopic Repair of Complete Tear of Rotator Cuff. J Surg: JSUR-188. DOI: 10.29011/2575-9760.000088

Received Date: 14 November, 2017; Accepted Date: 14 December, 2017; Published Date: 21 December, 2017

### Abstract

**Background:** Rotator cuff tear is one of the most common causes of shoulder complaint in the older age group. Tear and deficiency in this muscle group may be caused by a variety of reasons which may develop problems such as pain, movement restriction and shoulder joint arthropathy in the long term. Moreover, movement restriction is one of the main problems of these patients. Treatments differ depending on the severity of tear and patient's condition. Surgery is one of the important treatment options which may be done arthroscopically or by open technique. In this study we would like to report a short-term result of arthroscopic repair of complete tears of rotator cuff.

**Methods:** A cross-sectional study was done in 3 hospitals in Tehran, Iran. 183 patients were treated for their rotator cuff disease by arthroscopic technique from January 2013 to August 2017. 107 cases that had complete tears, and had at least one-year follow-up were considered for the study. 89 patients (56 male, 33 female) attended the assessment sessions and were evaluated by UCLA (University of California, Los Angeles) Shoulder and Elbow scoring system. The scores were compared with the preoperative UCLA scores. Acromioplasty was performed in 83 patients.

**Results:** With a mean age of 53.2 (32-71) years, the average UCLA score was 11.3 before surgery and 31.4 in follow-ups. There were 11 patients with excellent, 62 good, 11 fair and 5 poor scores. Nine of the 11 cases with excellent scores and 34 of the good scores were younger than 55 years of age. Out of the 16 fair or poor results, 13 were older than 60 years of age.

**Conclusions:** A significant improvement in UCLA scores is possible after arthroscopic repair of complete rotator cuff tear, in short term. The treatment results are better in younger patients.

**Keywords:** Arthroscopy; Complete Tear; Rotator cuff; Shoulder

### Introduction

Rotator cuff composed of four muscles: Supraspinatus, Infraspinatus, Teres minor, and Subscapularis, which play an important role in the movement and also the stability of the shoulder joint. Tear and deficiency in the above-mentioned set may be caused by a variety of reasons which may develop problems such as pain, movement restriction and shoulder joint arthropathy in the long term. Most patients suffering from rotator cuff tear complain from a gradual progressive pain that develops to the Deltoid region which also occurs at nights. Moreover, movement restriction is one of the main problems of these patients. Since most cases

are degenerative tears and occur at older ages, patients often do not remember the onset of the problem and the disease is often chronic [1,2]. There are various types of cuff tear which include acute and chronic, traumatic and degenerative, complete and incomplete. Non-surgical treatments including pharmacotherapy and physiotherapy are usually advised, however, when these treatments are not responded which means pain is not improved and movement restriction is continued, the surgical treatment should be employed. Surgical treatment can be performed by open and arthroscopic methods. Nowadays, the tendency to perform the arthroscopic repair is continuously increasing. The type of treatment varies according to the patient's age, activity level and type of tear. Debridement and decompression are employed in wide tears that cannot be treated [3,4].

In several articles, the surgical results were satisfactory especially in cases of small tears (2-3 cm) and, in general, there was no significant difference between arthroscopic and open surgical procedures in terms of long-term follow-up [5,6]. Elman et al., at the University of California reported a 1-5-year follow-up of arthroscopically treated patients (rotator-cuff tear repair) demonstrating an 86% improvement in the University of California and Los Angeles (UCLA) shoulder grade score compared to the before surgery as well as 88% satisfaction in pain relief. Results in case of extensive tear in terms of improvement in the movement range and shoulder joint strength were not satisfactory [7]. performed a comparison between the open method (29 cases) and arthroscopic method (35 cases) for the rotator cuff tear repair. The long-term results were approximately the same in both procedures with less fibrous ankylosis and faster range of movement start in the arthroscopic repair. The results were published in Arthroscopy journal [8]. compared 50 cases of arthroscopic repair of cuff tear and 50 open treatment. The follow-up period was at least 18 months and the UCLA criteria were utilized. In small to medium thickness tears (less than 3 cm), 97% improvement was achieved in arthroscopic while it was 94% for open treatment.

In wide tears (more than 3 cm), 82.4% recovery in arthroscopic method and 76.9% recovery in open method was observed. In general, there was no significant difference between the two methods but typically, the results of the rotator cuff tear repair was desirable [9] reported a 12-month follow-up based on the pain score and increase of shoulder movement area. Concerning these criteria, a significant improvement was observed after the arthroscopic repair of the rotator cuff tear [10]. In a study conducted by Ozbaydar et al., a considerable improvement was achieved in the UCLA standard after the arthroscopic repair of the rotator cuff tear. The average UCLA score was 11.7% and 11.4% before and after surgery respectively [11]. In Iran, the arthroscopic surgical procedure for rotator cuff tear is relatively new, and its results have not been studied so far. In this study, the results of arthroscopic repair of full thickness rotator cuff tear with short-term follow-up of at least one year are reported.

## Materials and Methods

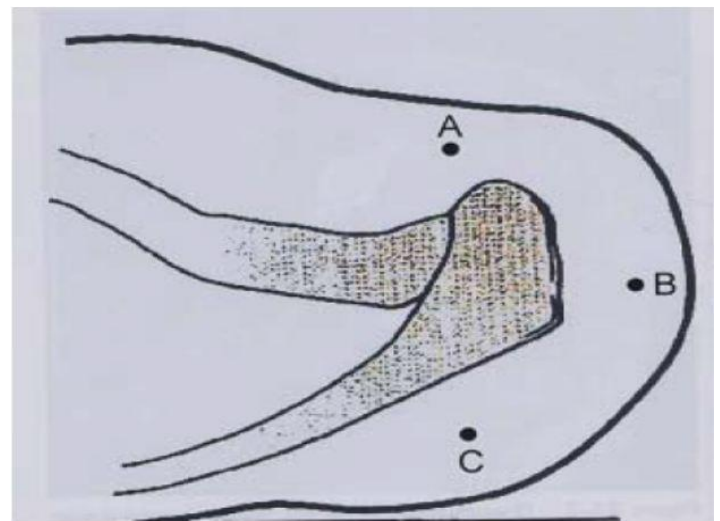
In this prospective descriptive study, 183 patients who had undergone arthroscopic surgery due to Rotator Cuff tear from 2013 to 2017 in Ayatollah Taleghani, Milad, and Pars hospitals in Tehran,

107 cases were subject to review. All these cases had full thickness rotator cuff tear and had at least one-year follow-up. However, only 89 patients (56 males and 33 females) were available for examination, which are reported here. All patients were evaluated using UCLA criteria in terms of pain and shoulder function before surgery and in the follow up, the same criteria were re-evaluated.

In addition to simple radiography, all patients had undergone MRI. The criterion was regular one-year follow-up, and patients who were followed up for one year were studied. The improvement level in shoulder joint performance and reduction of pain in patients before surgery and after one year after were evaluated based on UCLA criteria. In most similar articles, the UCLA criteria have been utilized. This criterion evaluates the amount of pain, joint strength and movements and the degree of satisfaction. In this study, all measurements were performed by one person.

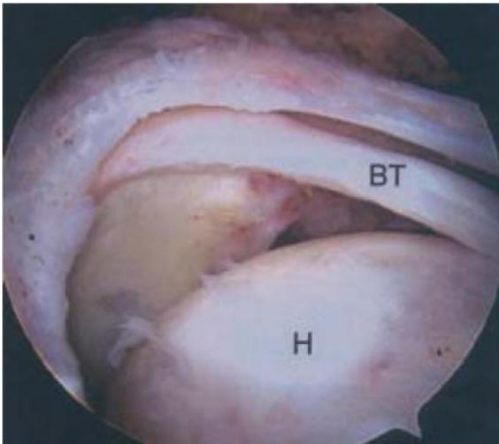
## Treatment Method

At first, diagnostic arthroscopy was performed using standard portals in beach chair (Figure 1).



**Figure 1:** Required portals for rotator cuff tear repair. Front portal is used for repair and if it is required, for the Mumford procedure as an inflow (A). Back and lateral portal are utilized for repair and observation.

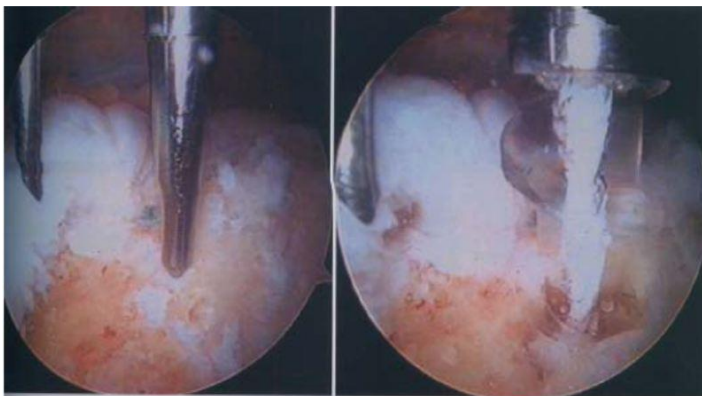
The initial evaluation of the shape and range of motion was performed (Figure 2).



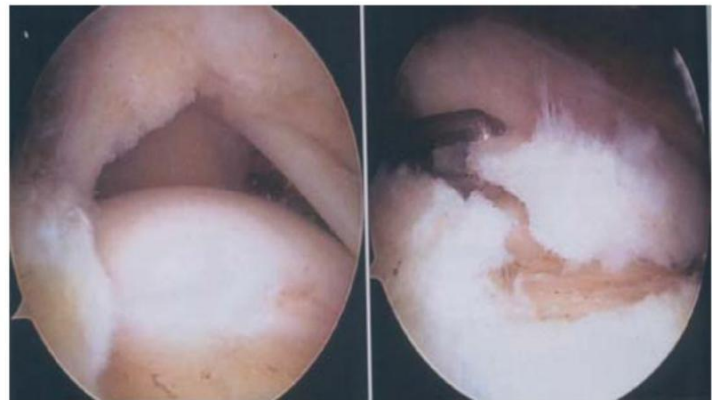
**Figure 2:** Arthroscopic view of back portal illustrates the rotator cuff extensive tear.

Then the tear edge debridement was performed followed by acromioplasty in the next stage. Acromioplasty is almost an essential part of rotator cuff surgery. Since most cases of rotator cuff tears are accompanied with Impingement syndrome, acromio-plasty is necessary to relieve pain in patients and also to create a suitable bed for the tendon repair, except in certain individuals, especially in young people. The reason for this exception is rather traumatic since these patients have no problem concerning sub ac-romial space.

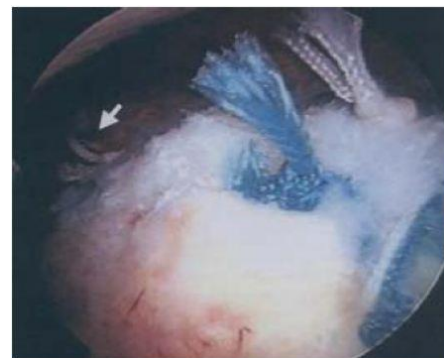If it was required, subacromial decompression was performed and after that based on the type of tear (Crescent, L, and U shape) a metal suture anchor repair or absorbable repair was performed (Figures 3-5).



**Figure 3:** Arthroscopic view and the Suture Anchor placement.



**Figure 4:** Arthroscopic view of L-shaped rotator cuff tear from, lateral portal.



**Figure 5:** Arthroscopic view of a full thickness repair in L-shaped rotator cuff tear.

The shoulder sling was used for six weeks after surgery. During this time, the elbows, wrists, and finger movements, as well as gentle of passive forward bending and external rotation were carried out. After six weeks, the active motions without abduction were performed and after 12 weeks, the deltoid muscles and rotator cuff strengthening as well as Omni-directional motions were recommended.

## Results

The mean age of the patients was 53.2 years (32-71). The mean score of UCLA before surgery was 11.3 and one year after surgery was 31.4. Among 183 rotator cuff surgery, only 107 patients had full thickness tear. However, only 89 patients were available by the end of one year after surgery and were subject to the study. MRI from 89 patients before surgery demonstrated full

thickness tear in 73 patients, partial thickness tear in 14 cases, and no tears in two cases. In shoulder arthroscopy, 89 patients had full thickness tear in shoulder. This significant error in MRI diagnosis is likely due to lack of experience and common knowledge of radiologists. In addition, MRI was performed in different centers and interpreted by different people. Acromioplasty was performed in 83 patients (93.2%).

According to the UCLA criteria, the results were as follows: excellent in 11 patients, good in 62 cases, poor in 11 patients, and bad in five cases. Nine patients out of 11 with excellent results aged below 55 years. Among the patients who achieved good results, 34 patients (47%) aged below 55 years old, 63 (87%) were under 60 years old while of 16 patients with poor results, 13 patients (84%) were over age of 60 (Table 1).

Average age	53.2 year
Gender	11 Male, 5 Female
Mean duration of symptoms before surgery	5 Month
Trauma history	3 Patients
Background Disease (Rheumatoid arthritis)	2 Patients
Sub acromial Injection History	11 patients
After surgery shoulder forward flexion mean	70 degrees
Acromioplasty	16 patients
Acromioclavicular joint removal	11 patients

Table 1: Patients specifications who are reported with poor results after arthroscopic surgery in full thickness rotator cuff tear based on UCLA criteria.

The comparison of UCLA scores before and after surgery in 73 patients (82%) was good and excellent, and in 77 cases (87%) the highest level of pain recovery was achieved which was significant compared to similar studies. The lowest level of rehabilitation in 59% of patients was in forward flexion strength.

## Discussion

As it is considered, following arthroscopic repair of full thickness rotator cuff, most patients presented a significant improvement in UCLA score. Based on the UCLA criterion, arthroscopic repair of full thickness rotator cuff in 82% of patients lead to good and excellent results comparable to those of other studies in recent years. In study conducted by Elman et al., the patient satisfaction was 86%, which is almost the same as our study in which the number of patients was almost doubled. In different studies, the results were almost the same [7]. Compared with the study of Ide et al. with 50 patients and 18 months of follow up, this study included more number of samples and a shorter follow up, but in terms of UCLA standard almost the same results were achieved. In Ide study, the comparison between the results of open and arthroscopic methods did not present a significant difference.

Barnes et al and Huang et al compared arthroscopic versus mini-open repair of rotator cuff tears. They came to the conclusion that both methods are associated with similar outcomes and can be used interchangeably based on the patient and rotator tear conditions [12, 13]. In this study, there was no possibility of performing this comparison between open and arthroscopic methods since almost all patients requested arthroscopic surgery [9]. The poor results in 16 patients were due to various factors such as age, wide tears, inadequate decompression, adequate repair, tendon intrinsic characteristics, and underlying disease such as rheumatoid arthritis. Investigating the effect of these factors on prognosis of patient treatments requires another study that is currently ongoing.

Compared to other studies, the number of samples in the present study was higher and patients were included in the study based on certain criteria, which is one of the strengths of this study. Since this study was a descriptive prospective, more values would be obtained if comparisons were made between different methods, longer follow-up period utilized, or the effect of different factors on the patient prognosis were evaluated. Generally, due to the sufficient number of samples in this prospective study, it can be concluded that currently, the full thickness arthroscopic repair of rotator cuff tear in Iran achieves good results, and it is recommended if the patients are properly chosen and there is adequate experience and conversancy in the surgery. It seems that if there is sufficient skill in performing arthroscopic methods and taking into account its advantages, it can be expected that this treatment method is a suitable alternative treatment for an open method in tear surgery.

It was also observed that the results of the treatment in patients with a lower age were significantly better than those that indicated the necessity of surgical treatment at these ages. In patients with full thickness rotator cuff tear, in active and high-performance patients, and also in patients who have not responded to non-surgical treatments, surgical treatment is recommended to improve pain and increase the range of motion and shoulder performance [14,15]. In several studies that some of them are previously mentioned, it has been shown that open and arthroscopic methods do not differ significantly in terms of long-term results. As discussed in Severud et al., in the arthroscopic method fibrous ankylosis was less and the range of motion was started faster. Pain is the main complaint of most patients. As observed, pain recovery and patient performance were significantly enhanced, and relative improvement was achieved in the amount and strength of forward flexion.

## References

1. Abechain JJK, Godinho GG, Matsunaga FT, Netto NA, Daou JP, et al (2017). Functional outcomes of traumatic and non-traumatic rotator cuff tears after arthroscopic repair. World journal of orthopedics 8: 631-637.
2. Canale ST and Beaty JH (2012) Campbell's Operative Orthopaedics E-Book: Elsevier Health Sciences.



3. MacKechnie MA, Chahal J, Wasserstein D, Theodoropoulos JS, Henry P, et al. (2014) Repair of full-thickness rotator cuff tears in patients aged younger than 55 years. *Arthroscopy: the journal of arthroscopic & related surgery: official publication of the Arthroscopy Association of North America and the International Arthroscopy Association* 30: 1366-1371.
4. Choi S, Kim MK, Kim GM, Roh YH, Hwang IK, et al. (2014) Factors associated with clinical and structural outcomes after arthroscopic rotator cuff repair with a suture bridge technique in medium, large, and massive tears. *Journal of shoulder and elbow surgery* 23: 1675-1681.
5. Abrams GD, Gupta AK, Hussey KE, Tetteh ES, Karas V, et al. (2014) Arthroscopic Repair of Full-Thickness Rotator Cuff Tears with and Without Acromioplasty: Randomized Prospective Trial With 2-Year Follow-up. *The American journal of sports medicine* 42: 1296-1303.
6. Xiao J, Cui GQ, Wang JQ (2013) [Mid-term results after arthroscopic repair of full-thickness rotator cuff tears]. *Zhonghua wai ke za zhi [Chinese journal of surgery]* 51: 619-622.
7. Ellman H, Kay SP, Wirth M (1993) Arthroscopic treatment of full-thickness rotator cuff tears: 2-to 7-year follow-up study. *Arthroscopy: The Journal of Arthroscopic & Related Surgery* 9: 195-200.
8. Severud EL, Ruotolo C, Abbott DD, Nottage WM (2003) All-arthroscopic versus mini-open rotator cuff repair: a long-term retrospective outcome comparison. *Arthroscopy: The Journal of Arthroscopic & Related Surgery* 19: 234-238.
9. Ide J, Maeda S, Takagi K (2005) A comparison of arthroscopic and open rotator cuff repair. *Arthroscopy: The Journal of Arthroscopic & Related Surgery* 21: 1090-1098.
10. Lee E, Bishop JY, Braman JP, Langford J, Gelber J, et al. (2007) Outcomes after arthroscopic rotator cuff repairs. *Journal of shoulder and elbow surgery* 16: 1-5.
11. Ozbaydar MU, Bekmezci T, Tonbul M, Yurdoglu C (2006) The results of arthroscopic repair in partial rotator cuff tears. *Acta orthopaedica et traumatologica turcica* 40: 49-55.
12. Barnes LA, Kim HM, Caldwell JM, Buza J, Ahmad CS, et al. (2017) Satisfaction, function and repair integrity after arthroscopic versus mini-open rotator cuff repair. *The bone & joint journal* 99: 245-249.
13. Huang R, Wang S, Wang Y, Qin X, Sun Y (2016) Systematic Review of All-Arthroscopic Versus Mini-Open Repair of Rotator Cuff Tears: A Meta-Analysis. *Scientific* 6: 22857.
14. Burkhart SS (2001) Arthroscopic treatment of massive rotator cuff tears. *Clinical orthopaedics and related research* 2001: 107-118.
15. Burkhart SS, Barth JR, Richards DP, Zlatkin MB, Larsen M (2007) Arthroscopic repair of massive rotator cuff tears with stage 3 and 4 fatty degeneration. *Arthroscopy: the journal of arthroscopic & related surgery* 23: 347-354.