



An Effective Protocol in The Management of Pediatric Salter Harris Finger Fractures

Habib Al Basti, Salim AL Lahham*, Saif Badran, Ruba Sada, Ahmed Mofeed Mokhalalati, Rehan Zahid, Sequina Ali J.M.AL-Saigel, Shiyas Mohammedali, Sohail Quazi, Talal Al-Hetmi

***Corresponding author:** Salim Al Lahham, Fellowship in- microsurgery, Ganga hospital, No. 313, Mettupalayam Road, Saibaba Koil, Coimbatore, Tamil Nadu 641043, India.

Plastic surgeon ,HMC,,Doha,Qatar .Tel: +91-7430197754; Email: SAiLahham@hamad.qa

Citation: Basti HA, AL Lahham S, Badran S, Sada R, Mokhalalati AM, et al. (2018) An Effective Protocol in The Management of Pediatric Salter Harris Finger Fractures. J Orthop Ther: JORT-1123. DOI: 10.29011/2575-8241.001123

Received Date: 05 November, 2018; **Accepted Date:** 16 November, 2018; **Published Date:** 21 November, 2018

Abstract

Introduction: Pediatric hand fracture is a common problem that is insufficiently reported in the literature, but can cause significant acute functional and psychological impact on the children and their families.

Methods: A total number of 450 pediatric patients were included in a prospective fashion over six years, our main protocol was conservative management with early removal of the cast for patient with finger salter Harris type 2 fracture.

Results: Only 2 two cases (0.5%) needed operative fixation under general anaesthesia. None of our patients reported any residual pain or functional impairment at the discharge follow-up.

Conclusion: Conservative management with early finger mobilization is a safe and highly effective protocol in most of the cases and can help the child in preventing the risk of general anesthesia, reduce the psychological and functional impact of prolonged casting, and prevent the need of a long occupational therapy treatment.

Introduction

Pediatric trauma is a common problem that we face in the emergency department, of these the most commonly affected sites, are the hands which can result in a fracture [1]. phalangeal fractures are the most commonly affected site in the hand fractures, and account for the second cause of emergency visits for fracture in the unites states [2]. The pediatric Hand fracture is mostly non-epiphyseal in around 60% of the case, the remaining 40% are affecting the epiphyseal growth plates [3]. The epiphyseal fractures are categorized according to the Salter-Harris classification into five categories [1]. Salter-Harris type two, is the most common type and counter for more than 90% of the epiphyseal fractures, which represents around 39% of all hand fractures in the pediatric age group [1,3], and defined as a fracture that travels within the growth plate and then to the metaphysis away from the joint line.

Methods

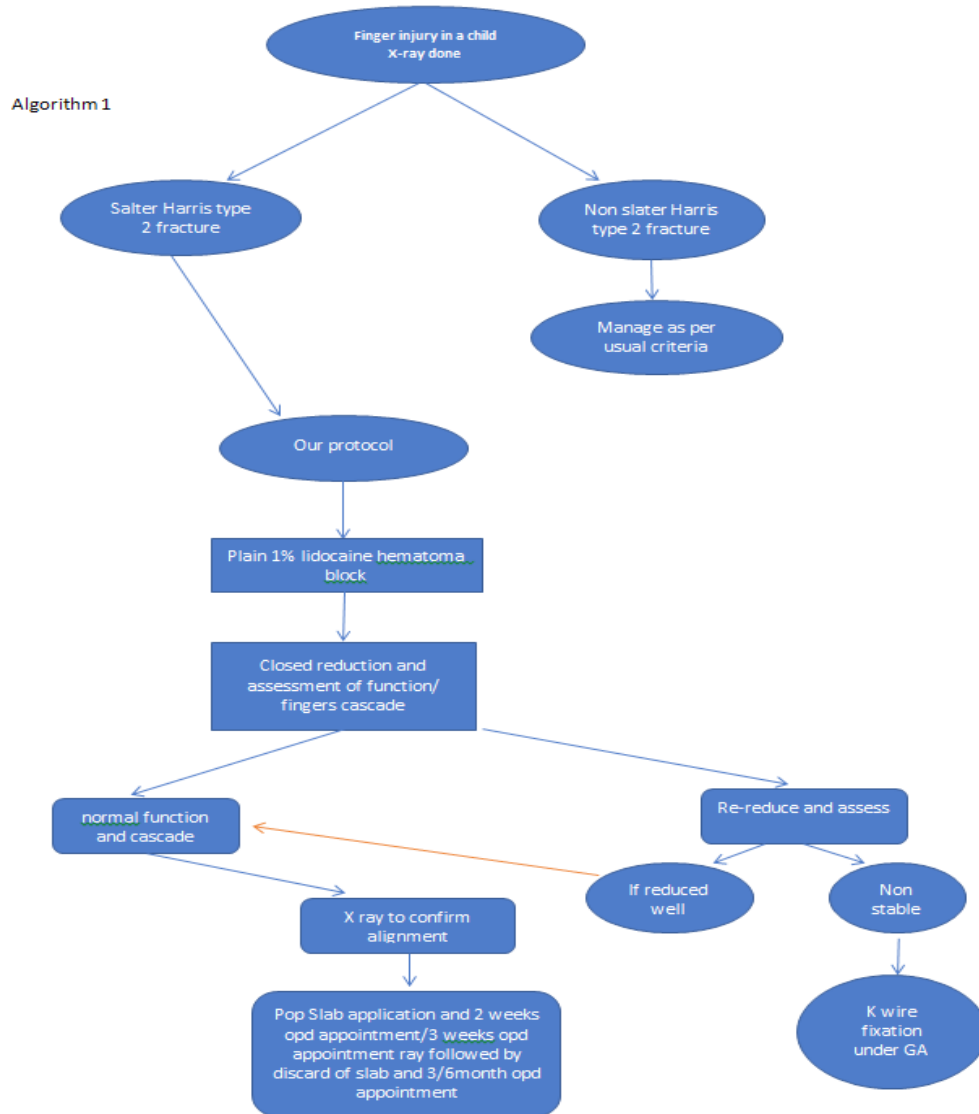
Our study was conducted in a prospective design over six years in the period between 2012 and 2017. A total number of 450 pediatric patients were included. In our study, we included a

pediatric age group up to 16 years of age. Radiographs with unclear details were repeated, and all our patient received the same plan of care as per our hospital protocols. Patients presented initially to the emergency department. The patient was evaluated initially by the emergency physician who requested an x-ray of the hand and injured the finger. Once the x-ray showed a Salter-Harris type 2 fracture, a consultation is made to our plastic surgery on-call team. The patient was then seen in the emergency by the plastic surgeon who discusses the type of injury with the guardian and explains our protocol in managing such fracture. Our protocol was as follows (algorithm 1):

Fracture hematoma block is made using lidocaine 1% (maximum dose 4mg/kg), closed reduction is done in both AP/ dorso-volar planes to restore normal bone alignment followed by assessment of function and fingers cascade. Once the function and fingers cascade is restored then a POP slab applied above the elbow in 3 years old or younger patients and below the elbow in patients older than 3 years. The patient is then seen in 2 weeks time for removal of the slab and reassessment of function, if all findings were normal then the x-ray was not repeated, and the slab is applied for one more week.

Notice: in all our patients we did not encounter any abnormal function at 2 weeks follow up visit.

The patient is seen again at 3 weeks follow up visit and the slab is removed, assessment of function and a new x-ray was done to confirm the alignment and the callus formation, in this visit the slab is discarded and the child is free to use his hand, only outdoor sports activities are avoided for 3 additional weeks. At 3 and 6 months follow up visit, only a clinical examination is performed, and the child is discharged, the parents were instructed to come anytime if they notice any abnormality in the finger. If the function and the cascade were not restored due to unstable fracture which we encountered in two cases only, then k-wire fixation is performed under general anesthesia followed by k wire removal on 3-4 weeks period according to the callus formation on x-ray.



Results

All patients restored normal range of motion without any clinical deformity at 3 and 6 months visits. Only 317(70%) patients completed 6 months follow up while 93 % of the patients completed 3 months follow up. All our patient fall in the age range between 20 months and 14 years old, average age was 5.8 years. Most of

our patient were male with 78%. Most of the traumas resulted in single digit affection, while in 27 cases (6%) multiple digits were involved. The most affected finger was the little finger in 31% of cases, followed by the thumb (21%), middle finger (19%), ring finger (16%) and the index finger in 13 % of the cases. The proximal phalanx was the most commonly affected site in 67% of the cases followed by 25% in the middle phalanx, and the distal

phalanx was the least common in only 8% of the cases. Only 2 two cases (0.5%) needed operative fixation under general anaesthesia. None of our patients reported any residual pain or functional impairment at the discharge follow-up (Figures 1,2).

Total number	follow up		Age Range	Gender		Number of affected digits		The affected digits					Affected phalanx		
	3 months	6 months		male	female	Single digit	multiple digit	thumb	index	middle finger	ring	little	proximal phalanx in 67%	25% middle phalanx	8% distal phalanx
450 pediatric patients	421 patients	317 patients	1,8 years to 14 years	78%	22%	94%	6%	21%	13%	19%	16%	31%			

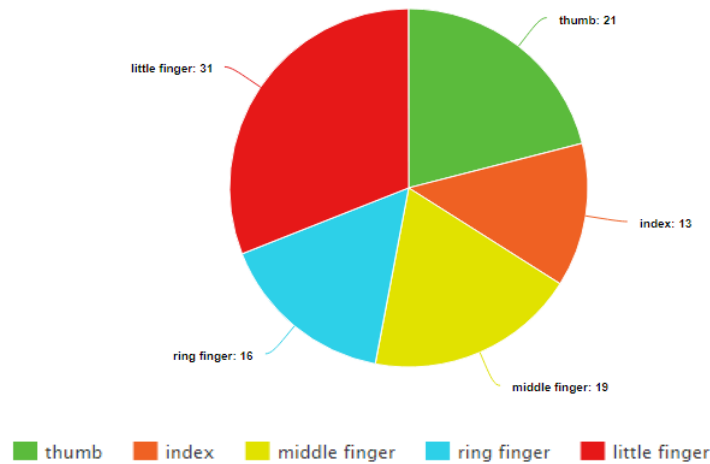


Figure 1: Pie chart illustrates the affected digit.

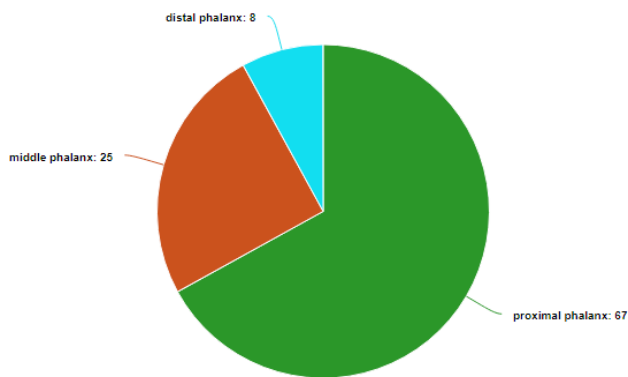


Figure 2: Pie chart illustrates the affected phalanx

Discussion

Our study differs from other studies in being the largest study that describes pediatric hand salter Harris fracture type 2 in the pediatric age group, most of our patient had a sufficient follow up to 6 months post injury, all our patient who followed in the clinic achieved a satisfactory result upon discharge without a reported complain regarding pain, deformity or weakness. Pediatric Fingers

fracture is a common problem, but still not sufficiently reported in the literature [1], almost two-thirds of boys and half of the girls experience one type of fracture before starting the teenage group [5]. Mostly affect children in the age of 10-14 years old, as they start to participate in contact sports which were the most common cause in both genders [2,3]. But in our group, the average age was 5.8 years old as the most common encounter mechanism of injury was falling down in the playgrounds at schools and parks. Although these injuries are usually don't end up with a long-term complication, they can still cause significant acute morbidity to the child which might affect his participating in life activities (3). Most of the previous protocols used in the management of these fractures are based on closed reduction +/- k wire fixation followed by 6 weeks immobilization in the functional position, we introduce a new protocol in management based on 3 weeks immobilization after closed reduction and then hand free active range of motion.

The ideal goal in fracture management of extra-articular fractures is to achieve proper bone healing and finger movement recovery at the same time, the prolonged use of a cast can promote the fracture healing on the expense of causing significant stiffness and delaying the recovery of fingers motion [4]. The prolonged

rigid immobilization of fingers fracture causes less risk of stiffness in children compared to adults, but it will prevent the children from participating in some of their recreational and learning activities, and the cast itself can cause significant psychological distress to both the children and their parents [3,4]. Pediatric age group skeletal bone is different from adults in having lesser density, more porous, and fewer mineral contents. However, their bones have been less tensile than the ligaments which will cause more fracture injuries than sprain injuries [5]. Bone fracture near the physis “also known as growth plate” in children will have a higher potential for faster remodeling and bone healing [5]. In our experience, most of the pediatric finger fractures Salter-Harris type 2 can be managed conservatively, with a short duration of splinting for 3 weeks only, results in satisfactory results with minimal acute psychological and physical morbidity to the children and their family. On the other hand, surgical treatment including open reduction or percutaneous reduction causes longer duration of immobilization, more significant acute and chronic morbidity, needs longer rehabilitation and occupational therapy treatment and put the child at a risk of general anesthesia [6,7].

Conclusion

Pediatric finger fractures, Salter-Harris type 2, are a common problem that is not sufficiently reported in the literature and can cause significant acute morbidity to the children. Conservative management with early finger mobilization is a safe and highly

effective protocol in most of the cases and can help the child in preventing the risk of general anesthesia, reduce the psychological and functional impact of prolonged casting, and prevent the need of a long occupational therapy treatment.

References

1. Izadpanah A, Karunanayake M, Izadpanah A, Sinno H, Luc M (2012) Salter-Harris Type 2 Fracture of the Proximal Phalanx of the Thumb with a Rotational Deformity. *Pediatric Emergency Care* 28: 288-291.
2. Abzug JM, Dua K, Bauer AS, Cornwall R, Wyrick TO (2016) Pediatric Phalanx Fractures. *Journal of the American Academy of Orthopaedic Surgeons* 24.
3. Mahabir RC, Kazemi AR, Cannon WG, Courtemanche DJ (2001) Pediatric hand fractures: A review. *Pediatric Emergency Care* 17: 153-156.
4. Jandali A, Jung F, Leclère F, Wartburg UV, Hug U, et al. (2013) Functional-Conservative Treatment of Extra-articular Physeal Fractures of the Proximal Phalanges in Children and Adolescents. *European Journal of Pediatric Surgery* 23: 317-321.
5. Arora R, Fichadia U, Hartwig E, Kannikeswaran N (2014) “Pediatric Upper-Extremity Fractures.” *Pediatric Annals* 43: 196-204.
6. Bohr S, Mammadli T (2018) “Early Functional Treatment of Proximal Phalanx Fractures in Children.” *Pediatric Emergency Care*, 2018.
7. Matzon JL, Cornwall R (2014) “A Stepwise Algorithm for Surgical Treatment of Type II Displaced Pediatric Phalangeal Neck Fractures.” *The Journal of Hand Surgery* 39: 467-473.