

## Research Article

# Laparoscopic Creation of Neovagina

Sanjay Chaube\*, A.K Sanwal, Jyoti Chaube

Department of Surgery, Gynaecology & Obesity, St. Jude's Hospital, Uttar Pradesh, India

\***Corresponding author:** Sanjay Chaube, Department of Surgery, Gynaecology & Obesity, Radio Diagnosis, St. Judes Hospital, Sipri Bazar, Uttar Pradesh 284003, India. Tel: +919415030227; Email: sanjay\_chaube@yahoo.co.in

**Citation:** Chaube S, Sanwal AK, Chaube J (2018) Laparoscopic Creation of Neovagina. J Surgery: JSUR-1104. DOI: 10.29011/2575-7903.001104

**Received Date:** 13 July, 2018; **Accepted Date:** 30 July, 2018; **Published Date:** 02 August, 2018

### Abstract

**Background:** MRKH syndrome is also defined as Müllerian agenesis. There are several surgical as well as nonsurgical methods for the treatment of vaginal agenesis still there is not any standardized treatment established. The laparoscopic procedure is a simple surgical technique with good cosmetic outcome.

**Aims and Objective:** The objective of the study was to perform laparoscopic creation of neo-vagina and analyze the outcome for the same with slightly modification of method with available instruments which leads to reduction in overall cost.

**Materials and Methods:** A total of 8 patients with vaginal agenesis were enrolled and all were treated with laparoscopic procedure.

**Results:** Patient were treated successfully with laparoscopic procedure with satisfactory sexual life however patient were also facing slight pain manageable by oral analgesics, patients were having dyspareunia & coital difficulty also. Laparoscopic procedure decreases operative time as well as post-operative hospitalization. No significant additional equipment required at hospital during surgical procedure.

**Conclusion:** Laparoscopic creation of neovagina appears to be safe, simple and effective method.

**Keywords:** Laparoscopy; Neovagina

### Introduction

Vaginal agenesis in karyotypic female may be escorted by defects of urogenital and skeletal systems. Combination of these anomalies are entitled as Mayer-Rokitansky-Kuster-Hauser Syndrome (MRKHS) [1]. MRKH syndrome is defined as congenital malformation which is characterized by absence of vagina associated with a variable abnormality of the uterus and the urinary tract however it includes functional ovaries [1]. There are two different syndromes have been described as per following: Typical: Isolated form of congenital agenesis of the vagina and uterus and, Atypical: Agensis of the vagina and uterus is a major and perhaps even obligatory characteristic [1]. In atypical syndrome patients diagnosed with renal agenesis or ectopia together with the MRKH and KF syndromes, known as the MURCS association (MU: Mullerian duct aplasia; R: renal agenesis/ectopia; CS: cervical somite dysplasia) [1]. MRKH syndrome is also defined as Müllerian agenesis or Müllerian aplasia [2]. The second most

frequent cause of primary amenorrhoea is Mullerian agenesis, found in 1:4000 to 1:5000 females from births [3]. Patients with Mullerian agenesis is almost always associated with a contralateral agenesis, which leads to an important surgical challenge as the pelvic anatomy is different and this condenses impractical most of the currently used procedures for creation of a neovagina [3]. Multiple genes concerned in the normal development of the Mullerian, renal, and bone structures, but two groups appear to be the strongest candidates:

- HOXA genes and
- WNT4 genes.

Since HOXA10 represents the area of the developing uterus, HOXA11 the lower uterine segment and cervix, and HOXA13 the vagina. It is biologically plausible that altered expression of these genes would result in the anomalies found in MRKH. Interestingly, the HOX genes are also associated with the normal development of the kidneys, bone, and vascular structures, which would reinforce the hypothesis of dysregulation of developmental genes involved

in the embryonic origin of the female reproductive tract Mullerian agenesis classified as per following: [1].

MO-unilateral system normally formed but unfused or septum retained,

M1-vaginal agenesis alone,

M2-vaginal and uterine agenesis,

M3-mullerian agenesis total, and

M4-mullerian and ovarian agenesis.

Both ovaries are normal in most of the cases, and affected women have “normal” sexual activity. Occasionally one ovary with ipsilateral fallopian tube may be absent. Hormone profile and secondary sexual characteristics are normal in the cases of MRKH syndrome. If Mullerian agenesis is left untreated, there will be sexual inability and patients may develop severe psychological problems. Many procedures have been described for development of neo-vagina with acceptable function, feeling and appearance.

Procedures for development of neo-vagina:

- Serial dilation,
- Vecchietti’s technique,
- Sigmoid or ileal flaps,
- Gracilis flap,
- Singapore flap, and
- Expanded vulval flap.

Among the above options, the modified Mc Indoe technique became very popular which is the simplest operation with very low donor site morbidity [4]. As there are several surgical as well as nonsurgical methods for the treatment of vaginal agenesis with MRKH syndrome, still there is not any standardized treatment established. The laparoscopic Davydov procedure is a simple surgical technique with good cosmetic outcome [2]. To diagnose with Mullerian agenesis structure, ultrasound and Magnetic Resonance Imaging (MRI) are mainly the options. Ultrasound is easily accessible and readily available in many settings, but it is not always effective in identifying underdeveloped Mullerian structures and ovaries, which are usually located high in the pelvis, often at the level of the pelvic brim. The presence of extra-pelvic ovaries has been reported in 16%-19% of the patients. For surgical planning, MRI is the most useful method, but it is more expensive than ultrasound. [5] The objective of the study was to perform laparoscopic creation of neo-vagina and analyze the outcome for the same with slightly modification of method with available instruments which leads to reduction in overall cost. Aim for

creating neo-vagina is to achieve a sufficient length and successful coital function. The surgery was performed before female is about to marry which is the best time as there is no need to do regular dilatation for long time and the chances of stenosis is minimal.

## Materials and Methods

Study was conducted in the Department of surgery, St. Jude’s Hospital, Jhansi, India. Informed consent was obtained from patient prior to enrollment as a part of study. Total 8 patients were enrolled in the study. Veres needle was used to pass the sutures as this helped in avoiding injury to the peritoneal organs and the blunt tip in the dissection in the avascular plain (Figure 1).

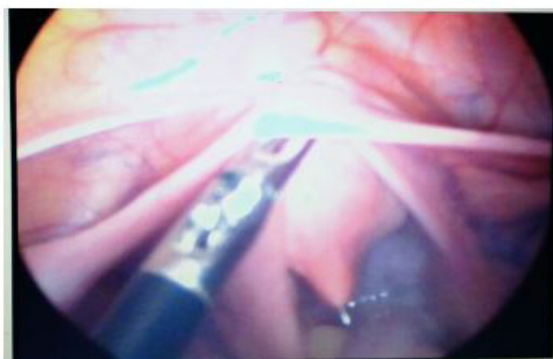


Figure 1: Dissection with blunt needle.

A suture grasping needle was used to pull out the traction sutures and tied to the locally developed traction devise with a locking bolt to apply gradual traction on the glass olive placed at the hymen dimple (Figure 2).

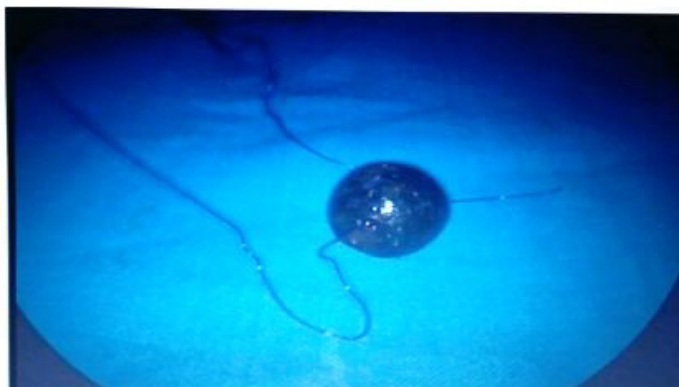
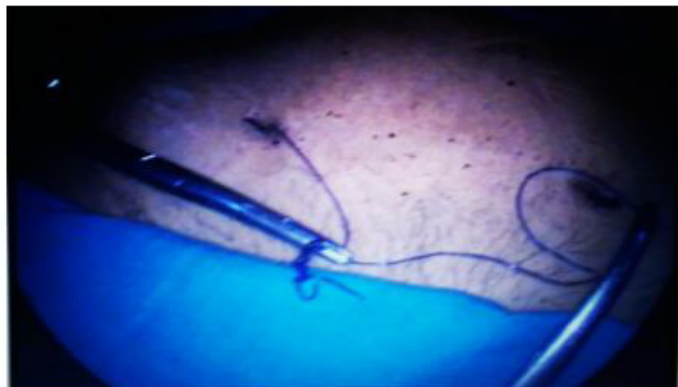
Figure 2: Glass Olive and Thread.

An invagination was created in the vesicorectal space in 10 to 12 days. The space thus created maintained with regular mould application till the patient became sexually active (Figure 3).



**Figure 3:** Mould creation.

The whole procedure has been performed under laparoscopic/cystoscopy vision which leads to negligible chances of injury to the bladder or intraperitoneal. There was no need of skin grafting. The problem of vaginal dryness or obliteration of neovagina does not happen as sufficient epithelization occurs in three to four months' time.

## Results and Discussion

Measurement of result were carried out depending on following parameters:

- a. Post-operative period:
  - Uneventful
- b. Patient complains:
  - Slight pain (Controlled by oral analgesics)
  - Dyspareunia
  - Coital difficulty

Dyspareunia and coital difficulty does not reported as caliber and depth of the created neovagina which is sufficient in the procedure. After laparoscopic surgery of patient for neovagina, it has been observed that there was less post-operative hospitalization as well as less there was less operative time for laparoscopic method. Similar type of results was observed by K. Takahashi et al. [5] where it has been observed that with laparoscopic method patient operative time and post-operative hospitalization time get decreases with time. As per L. Fedele, et al. [3], laparoscopic procedure requires less operative time as well as shorter post-operative stay at hospital. C. L. Templeman, et al. [6], observed similar result with shorter operative time as well as shorter post-operative hospitalization stay. In current study it was observed that sexual life of patients was satisfactory however patients were having slight pain which was manageable with oral

analgesics. According to K. Tajahashi, et al. [2], post-operative pain was less in patient with developed neo-vagina. Additionally, dilators were used for patients and they may have initially pain due to dilator however it was manageable. Post-operative sexual life for patients were found satisfactory. According to L. Fedele, et al. [3], patients have reported a normal sexual life and no dyspareunia or long term urologic long term complications. However, in current study, patient was also reported dyspareunia. As per E. Leblanc et al., surgical treatment of vaginal neoplasia is a source of dyspareunia or dehiscence however the specific impact of this situation is variable according to patient and her partner. As per study by E. Leblanc, et al. [7], patients were also complaining of reduced sexual function because of short vagina size or even post-coital vaginal dehiscence.

In current study there was not any need of skin grafting for developing neovagina. Similar results were observed with E. Leblanc et al. [7] that by laparoscopy procedure, no skin grafting, flap or any foreign material were needed.

In this study laparoscopic procedure was performed with available equipment at hospital only. No significantly new equipment was required as per current study. Similar type of comment was found by S.Y. Brucker, et al. [8] According to S.Y. Brucker, et al. [8], no instrument-related complications were seen with new instrument set for neovagina creation in vagina agenesis by laparoscopic procedure. After current study it was observed that laparoscopic procedure for creating neovagina is a simple, safe and effective procedure which allows patient with vaginal agenesis to have a satisfactory sexual life. Similar type of results was observed by E. Baptista, et al. [9] that laparoscopic technique is a simple, safe and effective procedure, which allows patients with congenital vaginal aplasia to have a satisfactory sexual activity, comparable to that of normal controls. According to S.Y. Brucker, et al. [8], laparoscopic procedure is therefore a safer, shorter, more effective, and less traumatic. As per L. Fedele, et al. [4], laparoscopic technique seems to have the important advantages of being brief, safe, effective, and yielding optimal anatomic-functional results in this critical subset of MRKH patients with a known higher perioperative risk factor. E. Leblanc, et al. [7] found that laparoscopy is a simple and promising method for creation of neovagina.

## Conclusion

Laparoscopic creation of neovagina appears to be safe, simple and effective method. During follow up visit of the patients, it shows that laparoscopic procedure gives anatomically and functionally grafting results. Laparoscopic procedure can be performed with some modification in locally available materials without much increasing cost of the procedure however due to poor socioeconomic status, development of laparoscopic method

in central India region is very difficult.

## References

1. Gupta NP, Ansari MS (2002) Mayer-Rokitansky-Kuster-Hauser (MRKH) Syndrome - a Review. *Indian Journal of Urology* 18: 111–116.
2. Takahashi K, Nakamura E, Suzuki S, Shinoda M, Nishijima Y, et al. (2016) Laparoscopic Davydov Procedure for the Creation of a Neovagina in Patients with Mayer-Rokitansky-Küster-Hauser Syndrome: Analysis of 7 Cases. *Tokai J Exp Clin Med* 41: 81-87.
3. Fedele L, Frontino G, Motta F, Restelli E, Candiani M (2010) Creation of a Neovagina in Rokitansky Patients with a Pelvic Kidney: Comparison of Long-Term Results of the Modified Vecchietti and McIndoe Techniques. *Fertility and Sterility* 93: 1280-1285.
4. Tiwari P, Jain A, Tiwari M, Yadav V (2015) Functional and Anatomical Results after McIndoe Vaginoplasty. *J of Evolution of Med and Dent Sci* 4: 9173-9179.
5. Londra L, Chuong FS, Kolp L (2015) Mayer-Rokitansky-Kuster-Hauser Syndrome: A Review. *IJWH* 7: 865-870.
6. Templeman CL, Hertweck SP, Levine RL, Reich H (2000) Use of Laparoscopically Mobilized Peritoneum in the Creation of a Neovagina. *Fertility and Sterility* 74: 589-592.
7. Leblanc E, Bresson L, Merlot B, Puga M, Kridelka F, et al. (2016) A Simple Laparoscopic Procedure to Restore a Normal Vaginal Length After Colpohysterectomy with Large Upper Colpectomy for Cervical and/or Vaginal Neoplasia. *Journal of Minimally Invasive Gynecology* 23: 120-125.
8. Brucker Sara Y, Gegusch M, Zubke W, Rall K, Gauwerky JF, et al. (2008) Neovagina Creation in Vaginal Agenesis: Development of a New Laparoscopic Vecchietti-Based Procedure and Optimized Instruments in a Prospective Comparative Interventional Study in 101 Patients. *Fertility and Sterility* 90: 1940-1952.
9. Baptista E, Carvalho G, Nobre C, Dias I, Torgal I (2016) Creation of a Neovagina by Laparoscopic Modified Vecchietti Technique: Anatomic and Functional Results. *Rev Bras Ginecol Obstet* 38: 456-464.