



Variations in Abnormal Nipple Discharge Management in Women- a Systematic Review and Meta-analysis

Alison Leong, Alison Johnston, Michael Sugrue*

Department of Breast Surgery, Breast Centre North West, Donegal Clinical Research Academy, Letterkenny University Hospital, Donegal, Ireland

***Corresponding author:** Michael Sugrue, Department of Breast Surgery, Breast Centre North West, Donegal Clinical Research Academy, Letterkenny University Hospital, Donegal, Ireland. Tel: +353749188823; Fax: +353749188816; Email: michael.sugrue@hse.ie

Citation: Leong A, Johnston A, Sugrue M (2018) Variations in Abnormal Nipple Discharge Management in Women- a Systematic Review and Meta-analysis. J Surg: JSUR-1154. DOI: 10.29011/2575-9760.001154

Received Date: 13 July, 2018; **Accepted Date:** 19 July, 2018; **Published Date:** 26 July, 2018

Abstract

Nipple discharge accounts for 5% of referrals to breast units; breast cancer in image negative nipple discharge patients varies from 0 to 21%. This systematic review and meta-analysis determined variability in breast cancer rates in nipple discharge patients, diagnostic accuracy of modalities and surgery rates. An ethically approved meta-analysis was conducted using databases PubMed, EMBASE, and Cochrane Library from January 2000 to July 2015. For the breast cancer rates' review, studies were excluded if no clinical follow-up data was available. For the diagnostic accuracy meta-analysis, studies were excluded if there was no reference standard, or the number of true and false positives and negatives were not known. Pooled sensitivities were determined using Mantel-Haenszel method. For the surgery rates' review, only studies with consecutive nipple discharge patients were included. Average risk of having a breast cancer is 10.2% in nipple discharge patients. Most studies reported an age threshold of 50 above which breast cancer risk greatly increases. Pooled sensitivities of ultrasound, mammogram, mammogram and ultrasound, breast MRI, conventional galactography, smear cytology, ductal lavage cytology and ductoscopy were 0.64, 0.34, 0.65, 0.81, 0.75, 0.37, 0.49 and 0.82 respectively. Average surgery rate was 43.4%. Malignancy rate of 10.2% indicates the need to continue surgery, especially for patients aged over 50. Patients below 50, in the absence of risk factors such as family history, can be managed conservatively with close follow up.

Keywords: Breast Cancer; Breast Diseases; Management; Nipple Discharge; Pathologic; Women

Introduction

Nipple discharge accounts for about 3-5% of referrals to a breast unit, and is the third most common presenting symptom after a mass or breast pain [1-3]). The clinical challenge is differentiating physiological from pathological nipple discharge. The latter is usually spontaneous, persistent, unilateral, uniductal and may be bloodstained but can be clear, pink, serous or serosanguinous [4]. There are various guidelines and algorithms reported for nipple discharge management [5-22]. While an abnormal mammogram and subareolar ultrasound allows fine needle aspiration cytology, core biopsy, or excision to determine the pathology, a particular challenge occurs in patients with nipple discharge who have a normal physical examination and imaging. The risk of breast cancer

in image negative nipple discharge patients varies depending on the patient cohort between 0 and 21% [23-27]. In such cases, while some algorithms propose observation, microdochectomy, or major duct excision, others propose the use of galactography. A significant number of countries have used intraductal approaches in nipple discharge evaluation, such as Japan, China, US and Turkey which have used ductoscopy and ductal lavage cytology, and Germany, Taiwan, Bulgaria, and the USA which have used galactography. For countries where galactography use for suspicious nipple discharge is routine, the European Society of Breast Cancer Specialists (EUSOMA) recommends the use of breast MRI when galactography fails for technical reasons [28]. Studies have examined the need for a duct excision as compared to conservative management involving a clinical follow-up [23,29]. This systematic review and meta-analysis aim to provide an overview of the variability in breast cancer rates of nipple discharge

patients across different age groups, the diagnostic accuracy of modalities for nipple discharge management, and the differences in surgery rates of pathological nipple discharge patients.

Methods

Review Questions

The overarching questions for this review were:

1. The risk of breast cancer in women with pathological nipple discharge in different age groups.
2. The diagnostic accuracy of tests used in nipple discharge evaluation.
3. The rates of nipple discharge patients undergoing surgery.

Search Strategy

This systematic review was conducted in accordance with the PRISMA statement for systematic reviews and meta-analysis. An electronic search was conducted using PubMed, EMBASE and the Cochrane Library from January 2000 to July 2015 and the results were limited to those in English. The search strategy combined the Medical Subject Heading (MeSH), Emtree terms and free text words. The search terms used were: nipple discharge AND (breast diseases OR breast cancer OR intraductal OR lesion OR pathological).

Inclusion and Exclusion Criteria

For the first review question, studies were included if they reported the number of breast cancer cases or percentages of those who had breast cancer stratified for age for women with a pathological nipple discharge. Studies were excluded if there was no clinical follow-up for those who did not undergo a biopsy or surgery to avoid bias. For the second review question, all studies that reported the diagnostic accuracy of tests for evaluation of women with a pathological nipple discharge were included. Studies were excluded if i) there was no reference standard for the index tests via pathology (surgical excision or tissue biopsy) or clinical follow-up, ii) a four-field contingency table for sensitivities and specificities could not be constructed as the number of true and false positives and negatives were not clear or could not be calculated, or the criteria for the classification of findings into positive and negatives were not stated in the case of cytology, and iii) the population involved only those who already had breast cancer as they were not reflective of the general population and positive predictive values are known to increase with a higher disease prevalence. Studies were also excluded if they were non-English publications, or were conference abstracts, letters, reviews, case series or case reports as these usually present limited data for analysis (Figure 1).

Figure 1. Flow diagram of study selection.

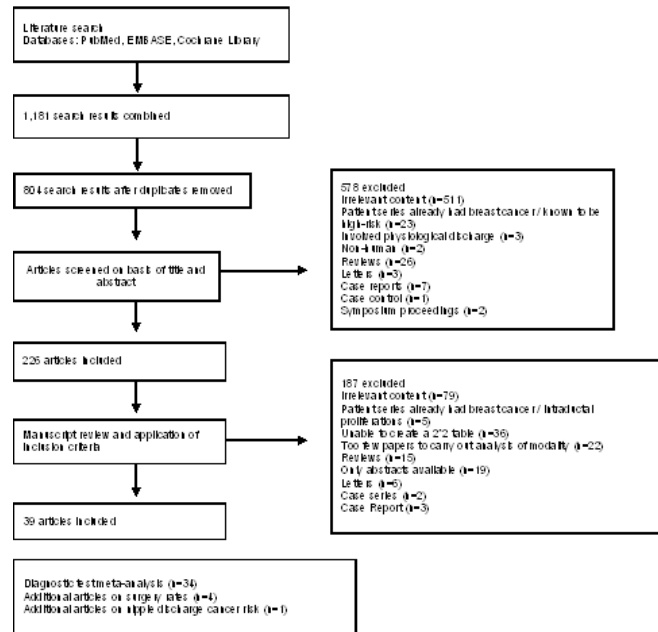


Figure 1: Flow diagram of study selection.

For the third review question, studies were included only if they were prospective studies involving the evaluation of women with abnormal nipple discharge or were retrospective studies involving the selection of consecutive patients from a prospective database. Studies were excluded if it was not clear how many underwent surgery, or the patients were pre-selected on the basis of having undergone certain diagnostic tests.

Methodological Quality Assessment

For the diagnostic test accuracy review, studies that were included were assessed using the QUADAS-2 (Quality Assessment of Diagnostic Accuracy Studies) criterion which grades the quality of primary diagnostic studies via four domains involving patient selection, index test, reference standard, and flow and timing [30]. The risk of bias in each domain are assessed as “low”, “high”, or “unclear” via signalling questions. In addition, generalizability of studies is assessed simultaneously for the first three domains. This data is available in supplementary material.

Data Extraction

For studies that met the inclusion criteria for breast cancer rates in age groups, numbers with breast cancer determined from surgery, biopsy, and clinical follow-up together with numbers in

cohort were extracted. Numbers or proportions of those with breast cancer stratified for age were also extracted. For the diagnostic test accuracy review, the following data were extracted from each study: first author, publication year, country, study design, setting, sample size, mean age and age range, type of index test, criteria for a positive test, contrast type and dose if applicable, and number of True Positives (TP), False Positives (FP), False Negatives (FN), and True Negatives (TN). TP, FP, FN, and TN were calculated according to the sample size of those who had breast pathology and those without. The following formula was used: TP = number of breast pathology patients × sensitivity; FN = number of breast pathology patients × (1-sensitivity); TN = number of breast pathology patients × specificity; FP = number of breast pathology patients × (1-specificity). For studies that met the inclusion criteria for surgery rates, numbers undergoing surgery and the numbers in cohort were extracted. Numbers with the various etiologies of a pathological nipple discharge were also extracted.

Data Analysis

All data was entered into an excel spreadsheet for analysis. For the diagnostic tests' accuracy review, data was analysed using Meta-DiSc 1.4. For each study, the sensitivities and the 95% confidence intervals were calculated. The primary objective was

to determine the pooled sensitivities of diagnostic tests for nipple discharge evaluation using the Mantel-Haenszel method. The Cochran Q-statistic and I² test was used to assess heterogeneity. For the reviews on breast cancer rates in different age groups and surgery rates of abnormal nipple discharge patients, proportions were calculated, and data summarised in tables. A funnel plot was used to show the surgery rates.

Results

Review question 1: The risk of breast cancer in women with pathological nipple discharge in different age groups

Using the aforementioned search terms and inclusion criteria, a total of 15 studies were identified, 10 of which had mentioned the number of breast cancer cases detected from observation or clinical follow-up in addition to biopsy and surgery, and 5 of which grouped breast cancer risk into those under 50 years or 50 years and over.

The average risk of a having a breast cancer is 10.2% in patient with features of a pathological nipple discharge i.e. unilateral spontaneous bloodstained or serous discharge as shown in (Table 1).

Author	Year	No. of patients with cancer	Total number of patients	Percentage with cancer (%)
Dinkel [31]	2001	16	384	4.2
Vargas [5]	2006	4	82	4.9
Gray [13]	2007	7	124	5.6
Morrogh [32]	2007	31	306	10.1
Morrogh [33]	2010	68	287	23.7
Khan [34]	2011	6	59	10.1
Sabel [23]	2012	7	142	4.9
Ashfaq [26]	2014	9	142	6.3
Bahl [35]	2015	20	273	7.3
Yoon [36]	2015	35	198	17.7
Average (n)		20	200	9
Total		203	1997	10.2
*Inclusion criteria vary with referral practice				

Table 1: Average risk of a patient with pathological nipple discharge having breast cancer diagnosed via biopsy, surgery, or clinical follow-up*.

Most studies reported an age threshold of 50 and above where the risk of breast cancer with a pathological nipple discharge is greatly increased (Table 2).

Author	Year	No. of patients	% cancer in <50 yrs old	% cancer in ≥50 yrs old
Seltzer [2]	2004	318	1.3	9.5
Gray [13]	2007	204	0.0	6.0
Dolan [11]	2010	313	2.0	15.0
Lubina [25]	2015	56	7.7	20.0
Yang [37]	2015	207	18.5	46.4

Table 2: Breast cancer risk in patients with nipple discharge stratified for age.

According to Morrogh et al. (2007), the incidence of cancer in nipple discharge patients with a negative standard evaluation was reported to be seven percent in patients younger than 40 years old, nine percent between 40 and 60 years old, and 14% over the age of 60 [34]. In a heterogeneous series of 116 patients with pathological discharge 4/9 identified with cancer were premenopausal [38]. Sabel et al. reported that four of seven cancer cases were in women less than or equal 40 years [23]. Yoon et al. (2015) reported that 23.5% of cancer cases were in those below 40 [36]. In contrast, Lau et al. (2005) reported that 10 of 11 patients with cancer were postmenopausal and recommended that all postmenopausal women with pathological nipple discharge undergo excision [39]. Moreover, Cabioglu et al. have shown that age 40 years and younger is a statistically significant predictor of

clinically benign disease [18].

Review question 2: The diagnostic accuracy of tests used in nipple discharge evaluation

A total of 34 studies were included, and the diagnostic test type and number of participants are summarised in (Table 3).

Diagnostic Test	No. of studies looking at test	Participants
Ultrasound	9	1100
Mammogram	12	1318
Mammogram and ultrasound	4	403
Breast MRI	10	470
Conventional Galactography	12	1007
ND Smear Cytology	11	1036
Ductal Lavage	6	582
Ductoscopy	8	1169

Table 3: Number of studies for each diagnostic test in meta-analysis and the corresponding number of participants.

(Table 4) lists the quality assessment of the 34 eligible studies. In terms of patient selection, in 1/34 of studies it was not clear whether a consecutive or random sample of patients enrolled.

Study	Year	Risk of bias				Applicability concerns		
		Patient selection	Index test	Reference standard	Flow and timing	Patient selection	Index test	Reference standard
Ashfaq [26]	2014	L	L	L	L	L	L	L
Bahl [35]	2015	L	L	L	L	L	L	L
Baitchev [40]	2013	L	?	L	L	L	L	L
Dietz [41]	2002	L	L	?	L	L	L	L
Dinkel [31]	2001	L	L	L	L	L	L	L
Gelder [42]	2014	L	L	L	?	L	L	L
Gray [13]	2007	L	L	L	?	L	L	L

Grunwald [43]	2007	L	L	L	?	L	L	L
Hahn [17]	2009	L	L	L	?	L	L	L
Hou [44]	2001	L	L	L	L	L	L	L
Hou [45]	2002	L	?	L	L	L	L	L
Kalu [46]	2012	L	L	L	L	L	L	L
Kamali [47]	2014	L	L	L	?	L	L	L
Kaplan [48]	2011	?	L	L	?	?	L	L
Khan [34]	2011	L	L	L	L	L	L	L
Kooistra [27]	2008	L	L	L	L	L	L	L
Lau [39]	2005	L	?	L	L	L	L	L
Lee [49]	2002	L	L	L	?	L	L	L
Liu [12]	2008	L	L	L	?	L	L	L
Lorenzon [50]	2011	L	L	L	?	L	L	L
Lubina [25]	2015	L	L	L	?	L	L	L
Manganaro [51]	2015	L	L	L	?	L	L	L
Morrogh [34]	2007	L	L	L	?	L	L	L
Ohlinger [52]	2014	L	L	L	?	L	L	L
Pritt [53]	2004	L	L	L	L	L	L	L
Sabel [23]	2011	L	L	L	?	L	L	L
Shen [54]	2000	L	L	L	?	L	L	L
Shen [55]	2001	L	L	L	?	L	L	L

Simmons [56]	2003	L	L	L	?	L	L	L
Tokuda [57]	2009	L	L	L	?	L	L	L
Vargas [5]	2006	L	?	L	?	L	L	L
Vaughan [58]	2009	L	L	L	L	L	L	L
Yamamoto [59]	2001	L	L	L	?	L	L	L
Yoon [36]	2015	L	L	L	?	L	L	L

L: Low risk?: Unclear risk, H: High risk.

Table 4: QUADAS -2 risk of bias assessment.

Variability was minimised as we only included consecutive patients presenting with nipple discharge and excluded studies involving only breast cancer patients, those with proliferations, and those known to be high risk undergoing surgery [60-64]. In terms of the risk of bias in the index test, in 4/34 of studies it was not clear what the criteria for a positive test was as it was not pre-specified. In terms of reference standard, 1/34 of studies used duct excision via ductoscopy rather than the usual biopsy or surgery. In terms of flow and timing, in 20/34 of studies it was not clear what the interval between the index test and the reference standard was. Of the 34 studies included in the meta-analysis 10/34 (29.4%) were prospective and 10 countries represented. The overall number of patients was 6997; mean age 48.7 ± 4.1 as shown in (Table 5).

Study	Year	Study Design	Country	No. of patients	Mean age
Ashfaq [26]	2014	Retrospective	USA	192	
Bahl [35]	2015	Retrospective	USA	273	48
Baitchev [40]	2013	Retrospective	Bulgaria	172	
Dietz [41]	2002	Retrospective	USA	121	52
Dinkel [31]	2001	Retrospective	Germany	384	47.5
Gelder [42]	2014	Retrospective	Netherlands	111	52
Gray [13]	2007	Retrospective	USA	153	55
Grunwald [43]	2007	Retrospective	Germany	64	
Hahn [17]	2009	Prospective	Germany	33	51.7
Hou [44]	2001	Retrospective	Taiwan	487	44.7
Hou [45]	2002	Retrospective	Taiwan	215	47.6
Kalu [46]	2012	Retrospective	USA	89	49.3
Kamali [47]	2014	Prospective	Turkey	430	
Kaplan [48]	2011	Retrospective	USA	50	50
Khan [34]	2011	Prospective	USA	59	45

Kooistra [27]	2008	Retrospective	Netherlands	618	
Lau [39]	2005	Retrospective	Germany	116	56.7
Lee [49]	2002	Retrospective	Taiwan	174	41.5
Liu [12]	2008	Prospective	China	1048	
Lorenzon [50]	2011	Retrospective	Italy	38	51.8
Lubina [25]	2015	Prospective	Germany	50	51.2
Manganaro [51]	2015	Retrospective	Italy	53	42
Morrogh [32]	2007	Retrospective	USA	376	
Ohlinger [52]	2014	Retrospective	Germany	214	52.2
Pritt [53]	2004	Retrospective	USA	39	
Sabel [23]	2011	Retrospective	USA	175	50.4
Shen [54]	2000	Prospective	China	415	
Shen [55]	2001	Prospective	China	259	46
Simmons [61]	2003	Retrospective	USA	108	49
Tokuda [56]	2009	Prospective	Japan	47	49
Vargas [5]	2006	Retrospective	USA	82	42
Vaughan [58]	2009	Prospective	USA	89	
Yamamoto [59]	2001	Prospective	Japan	65	
Yoon [36]	2015	Retrospective	Korea	198	44.8

Table 5: Characteristics of studies included in meta-analysis.

Of the 9 studies reporting sensitivity and specificity the mean sensitivity was 0.63 (0.2-1). Specificity is shown in (Table 6) .

Study	Criteria for abnormality	TP	FP	FN	TN	Sensitivity [95% CI]	Specificity [95% CI]
Ashfaq [26]	Mass or intraductal mass(es)	8	38	0	102	1.00 [0.63, 1.00]	0.73 [0.65, 0.80]
Bahl [35]	Subareolar and intraductal masses are coded BI-RADS category 4 or 5 if the patient has nipple discharge. Aim was to detect DCIS and invasive adenocarcinoma	10	58	8	170	0.56 [0.31, 0.78]	0.75 [0.68, 0.80]
Gray [13]	Mass or intraductal mass(es). Aim was to detect carcinoma	5	38	1	5	0.83 [0.36, 1.00]	0.12 [0.04, 0.25]
Grunwald [43]	Suspected papilloma or malignancy	39	5	19	8	0.67 [0.54, 0.79]	0.62 [0.32, 0.86]
Hou [45]		7	21	28	120	0.20 [0.08, 0.37]	0.85 [0.78, 0.91]
Lau [39]		6	28	4	49	0.60 [0.26, 0.88]	0.64 [0.52, 0.74]
Liu [12]		16	26	28	3	0.36 [0.22, 0.52]	0.10 [0.02, 0.27]

Lorenzon [50]	Cases scored as BI-RADS 3, BI-RADS 4 or BI-RADS 5 with a final histological diagnosis of a malignant or highrisk lesion were considered as true positive, while cases assessed as BI-RADS 1 or BI-RADS 2 with a final histological diagnosis of malignant or high-risk lesions were considered as false negative	12	3	7	16	0.63 [0.38, 0.84]	0.84 [0.60, 0.97]
Ohlinger [52]	DEGUM (German equivalent of BIRADS)	102	73	21	16	0.83 [0.75, 0.89]	0.18 [0.11, 0.28]

Table 6: Accuracy rates for use of ultrasound in women with pathological nipple discharge.

12 studies assessed the sensitivity and specificity of mammography with a mean sensitivity of 0.3 and specificity of 0.7 as shown in (Table 7) .

Study	Criteria for abnormality	TP	FP	FN	TN	Sensitivity [95% CI]	Specificity [95% CI]
Ashfaq [26]	Mass, indeterminate/suspicious calcifications, or architectural distortion. Aim was carcinoma detection.	2	11	7	157	0.22 [0.03, 0.60]	0.93 [0.89, 0.97]
Bahl [35]	BIRADS	3	5	17	237	0.15 [0.03, 0.38]	0.98 [0.95, 0.99]
Dietz [41]	BIRADS 3-5	2	100	3	4	0.40 [0.05, 0.85]	0.04 [0.01, 0.10]
Gray [13]	Indeterminate/suspicious calcifications, or architectural distortion. Aim was to detect carcinoma.	3	5	3	3	0.50 [0.12, 0.88]	0.38 [0.09, 0.76]
Grunwald [43]	BIRADS 3-5 for any abnormality	22	1	36	12	0.38 [0.26, 0.52]	0.92 [0.64, 1.00]
Hou [45]		1	4	34	137	0.03 [0.00, 0.15]	0.97 [0.93, 0.99]
Lau [39]		4	27	5	56	0.44 [0.14, 0.79]	0.67 [0.56, 0.77]
Liu [12]		18	16	19	10	0.49 [0.32, 0.66]	0.38 [0.20, 0.59]
Lorenzon [50]	Cases scored as BI-RADS 3, BI-RADS 4 or BI-RADS 5 with a final histological diagnosis of a malignant or highrisk lesion were considered as true positive, while cases assessed as BI-RADS 1 or BI-RADS 2 with a final histological diagnosis of malignant or high-risk lesions were considered as false negative	5	1	14	18	0.26 [0.09, 0.51]	0.95 [0.74, 1.00]
Ohlinger [52]	BIRADS	41	79	31	40	0.57 [0.45, 0.69]	0.34 [0.25, 0.43]
Simmons [56]	Masses, nodules, microcalcifications	4	20	3	32	0.57 [0.18, 0.90]	0.62 [0.47, 0.75]
Vargas [5]		3	0	38	25	0.07 [0.02, 0.20]	1.00 [0.86, 1.00]

Table 7: Accuracy rates for use of mammogram in women with pathological nipple discharge.

When combining ultrasound and mammogram, which was reported in 4 studies, it revealed a mean sensitivity and specificity of 0.7 and 0.7 respectively as shown in (Table 8) .

Study	Criteria for abnormality	TP	FP	FN	TN	Sensitivity [95% CI]	Specificity [95% CI]
Liu [12]		21	15	16	11	0.57 [0.39, 0.73]	0.42 [0.23, 0.63]
Lorenzon [50]	Cases scored as BI-RADS 3, BI-RADS 4 or BI-RADS 5 with a final histological diagnosis of a malignant or high-risk lesion were considered as true positive, while cases assessed as BI-RADS 1 or BI-RADS 2 with a final histological diagnosis of malignant or high-risk lesions were considered as false negative.	14	3	5	16	0.74 [0.49, 0.91]	0.84 [0.60, 0.97]
Sabel [23]	MMG: benign findings, dilated retroareolar ducts, suspicious mass or asymmetry and suspicious microcalcifications US: Benign changes, dilated ducts, subareolar mass, intraductal mass or filling defect	60	1	39	4	0.61 [0.50, 0.70]	0.80 [0.28, 0.99]
Yoon [36]	US: BIRADS	28	74	6	90	0.82 [0.65, 0.93]	0.55 [0.47, 0.63]

Table 8: Accuracy rates for use of ultrasound and mammogram in women with pathological nipple discharge.

10 studies assessed the sensitivity and specificity of breast MRI with a mean sensitivity of 0.7 and specificity of 0.7 as shown in (Table 9).

Study	Contrast Agent type	Dose	Criteria for abnormality	TP	FP	FN	TN	Sensitivity [95% CI]	Specificity [95% CI]
Ashfaq [26]			mass or suspicious enhancement pattern. Aim was carcinoma detection.	1	3	1	4	0.50 [0.01, 0.99]	0.57 [0.18, 0.90]
Gelder [42]			BIRADS \geq 5	2	3	3	99	0.40 [0.05, 0.85]	0.97 [0.92, 0.99]
Gray [13]			Mass or suspicious enhancement pattern. Aim was carcinoma detection.	1	1	0	1	1.00 [0.03, 1.00]	0.50 [0.01, 0.99]
Grunwald [43]			Suspected papilloma or malignancy	15	3	8	1	0.65 [0.43, 0.84]	0.25 [0.01, 0.81]
Lorenzon [50]	Gadobenato Dimeglumina 0.5 M (Multihance, Bracco, Milan, Italy) was administered IV as an automated bolus injection	Dose of 0.1 mL/kg body weight at a flow rate of 2 mL/s, followed by flushing of 20 mL of saline	Cases scored as BI-RADS 3, BI-RADS 4 or BI-RADS 5 with a final histological diagnosis of a malignant or high risk lesion were considered as true positive, while cases assessed as BI-RADS 1 or BI-RADS 2 with a final histological diagnosis of malignant or high-risk lesions were considered as false negative	18	4	1	15	0.95 [0.74, 1.00]	0.79 [0.54, 0.94]

Lubina [25]		MR-BI-RADS® ratings of 1, 2, and 3 were regarded as benign, and 4 and 5 as malignant	6	6	2	42	0.75 [0.35, 0.97]	0.88 [0.75, 0.95]
Manganaro [51]	Gadobutrol	Dose of 0.1mmol per kilogram with a rate of 2 mL/s together with 10mL of saline bolus. NA. Overall benign, papillomatous, malignant and DCIS lesion detection	44	0	1	8	0.98 [0.88, 1.00]	1.00 [0.63, 1.00]
Morrogh [32]		BI-RADS 4 or 5 considered suspicious, while score of 1-3 considered negative	11	8	4	29	0.73 [0.45, 0.92]	0.78 [0.62, 0.90]
Ohlinger [52]			45	30	9	4	0.83 [0.71, 0.92]	0.12 [0.03, 0.27]
Tokuda (57)	Gadopentetate dimeglumine (0.1mmol per kilogram of body weight) at a rate of 3 mL/s	0.1mmol per kilogram of body weight at a rate of 3 mL/s Clustered ring enhancement evaluation for malignant detection	9	2	6	20	0.60 [0.32, 0.84]	0.91 [0.71, 0.99]

Table 9: Accuracy rates for use of breast MRI in women with pathological nipple discharge.

The accuracy of galactography was reported in 12 studies with a mean sensitivity of 0.7 and specificity of 0.6 as shown in (Table 10) .

Study	Contrast	Criteria for abnormality	TP	FP	FN	TN	Sensitivity [95% CI]	Specificity [95% CI]
Ashfaq[26]		Duct cutoff or filling defect. Aim was carcinoma detection.	1	11	0	4	1.00 [0.03, 1.00]	0.27 [0.08, 0.55]
Baitchev [40]	urografin (0.5-2.0ml)		11	44	5	73	0.69 [0.41, 0.89]	0.62 [0.53, 0.71]
Gray [13]		Duct cutoff or filling defect. Aim was to detect carcinoma detection.	1	16	0	1	1.00 [0.03, 1.00]	0.06 [0.00, 0.29]
Grunwald [43]		Intraductal mass	9	0	7	3	0.56 [0.30, 0.80]	1.00 [0.29, 1.00]
Hahn [17]		NA. Aim was to assess intraductal epithelial proliferation	17	5	5	4	0.77 [0.55, 0.92]	0.44 [0.14, 0.79]
Hou [44]		intraductal filling defects	32	32	3	109	0.91 [0.77, 0.98]	0.77 [0.69, 0.84]

Hou [45]	Urografin (0.5-2 ml)	Malignant : ductal obstructions and irregular intraductal defects. To a smaller extent, ductal wall irregularity, surr duct torsion and displacement; Benign: lobular (smooth) intraductal defect and ductal dilatation	34	31	3	113	0.92 [0.78, 0.98]	0.78 [0.71, 0.85]
Lau [39]	0.5-1 mL of a 1:1 solution of sterile, water-soluble contrast material (Solutrast; Altana Pharma GmbH, Konstanz, Germany) and toluol blue		8	38	3	60	0.73 [0.39, 0.94]	0.61 [0.51, 0.71]
Manganaro [51]	nonionic iodinated contrast agent (iopamidol 300) up to a maximum of 1-1.5 mL	Findings were classified according to the Gregl scheme. Values calculated for the detection of ductal pathologies.	22	0	23	8	0.49 [0.34, 0.64]	1.00 [0.63, 1.00]
Morrogh [32]		filling defect or duct ectasia	21	91	10	17	0.68 [0.49, 0.83]	0.16 [0.09, 0.24]
Ohlinger [52]		possible intraductal lesion	70	19	16	15	0.81 [0.72, 0.89]	0.44 [0.27, 0.62]
Simmons [56]		intraductal or suggestive mass	0	1	2	9	0.00 [0.00, 0.84]	0.90 [0.55, 1.00]

Table 10: Accuracy rates for use of galactography in women with pathological nipple discharge.

The accuracy of smear cytology was reported in 11 studies with a mean sensitivity of 0.4 and specificity of 0.8 as shown in (Table 11) .

Study	Criteria for abnormality	TP	FP	FN	TN	Sensitivity [95% CI]	Specificity [95% CI]
Dinkel [31]	categories of “normal,” “dubious,” and “no cells” are considered to be negative, and those of “suspicious” and “positive” to be positive,	5	4	11	153	0.31 [0.11, 0.59]	0.97 [0.94, 0.99]
Grunwald [43]	Suspected papilloma or malignancy.	18	2	31	7	0.37 [0.23, 0.52]	0.78 [0.40, 0.97]
Hahn [17]	NA. Assessed epithelial intraductal proliferations via papillomatous cell detection	1	1	20	8	0.05 [0.00, 0.24]	0.89 [0.52, 1.00]
Hou [45]	Negative, atypia, suspicious, positive, inadequate	13	14	22	127	0.37 [0.21, 0.55]	0.90 [0.84, 0.94]
Kalu [46]	Negative cytology was defined as the presence of histiocytes, proteinaceous fluid, and the absence of epithelial cells. Atypical, suspicious, and papillary results were grouped together and designated as positive cytology. Benign non-papillary results were designed as negative cytology.	44	21	15	9	0.75 [0.62, 0.85]	0.30 [0.15, 0.49]
Kaplan [48]	positive (invasive and intraductal carcinoma), papillary, atypical, negative, unsatisfactory	1	2	9	38	0.10 [0.00, 0.45]	0.95 [0.83, 0.99]

Kooistra [27]	national cancer institute-recommended diagnostic categories: benign, atypical, suspicious or malignant (for accuracy calculation, suspicious and malignant considered positive)	6	43	30	84	0.17 [0.06, 0.33]	0.66 [0.57, 0.74]
Lee [49]	nondiagnostic, benign, papilloma, indeterminate papillary lesion, atypia, suspicious or malignant. cytological categories of ‘nondiagnostic’, ‘benign’, ‘papilloma’, ‘indeterminate papillary lesion’, and ‘atypia’ are considered to be negative, and those of ‘suspicious’ and ‘malignant’ to be positive	10	0	8	64	0.56 [0.31, 0.78]	1.00 [0.94, 1.00]
Ohlinger [52]	unremarkable ductal epithelium vs papilloma or carcinoma	18	8	61	47	0.23 [0.14, 0.34]	0.85 [0.73, 0.94]
Pritt [53]	Categories: negative, atypical, suspicious, and positive. Diagnoses of “negative” and “atypical” were considered negative for malignancy and diagnoses of “suspicious” and “positive” were considered positive for malignancy.	11	1	2	31	0.85 [0.55, 0.98]	0.97 [0.84, 1.00]
Simmons [56]	Benign, atypical, malignant	1	1	8	26	0.11 [0.00, 0.48]	0.96 [0.81, 1.00]

Table 11: Accuracy rates for use of nipple discharge smear cytology in women with pathological nipple discharge.

6 studies assessed ductal lavage cytology with a mean sensitivity of 0.5 and specificity of 0.9 as shown in (Table 12) .

Study	Criteria for abnormality	TP	FP	FN	TN	Sensitivity [95% CI]	Specificity [95% CI]
Khan [34]*	Abnormal cytology= mild atypia or malignant cytology/ severe atypia or malignancy. Aim was detection of papilloma or cancer.	12	5	23	19	0.34 [0.19, 0.52]	0.79 [0.58, 0.93]
Ohlinger [52]	unremarkable vs suspicious	17	6	13	36	0.57 [0.37, 0.75]	0.86 [0.71, 0.95]
Shen [54]	Malignant vs benign cells	39	15	52	51	0.43 [0.33, 0.54]	0.77 [0.65, 0.87]
Shen [55]	Cytological findings were grouped into three categories: clumps of ductal cells (. 50 cells), clumps with atypia (based on nuclear pleomorphism, chromatin staining, and size), and single ductal cells or small clumps. For the purposes of this study, they assumed that large ductal clumps reflected the exfoliation of an intraductal papillary lesion and that single ductal cells reflected the absence of the same. Positive findings: clumps with atypia and clumps with ductal cells	7	0	4	155	0.64 [0.31, 0.89]	1.00 [0.98, 1.00]
Vaughan [58]	positive cytology = malignancy, papilloma, or atypia	44	1	34	10	0.56 [0.45, 0.68]	0.91 [0.59, 1.00]
Yamamoto [59]	positive cytology = malignancy, papilloma, or atypia	2	2	2	33	0.50 [0.07, 0.93]	0.94 [0.81, 0.99]

* Involved use of brush.

Table 12: Accuracy rates for use of ductal lavage cytology in women with pathological nipple discharge.

For ductoscopy, while some studies focused on overall lesion detection, others classified lesions into malignant and non-malignant. Ductoscopy from all 8 studies reported a mean sensitivity of 0.8 and specificity of 0.6 as shown in (Table 13) . Overall it can be seen that variability exists in the criteria for a positive test.

Study	Year	Use of ductoscopy	TP	FP	FN	TN	Sensitivity [95% CI]	Specificity [95% CI]
Shen [54]	2000	Lesion detection	76	16	12	53	0.86 [0.77, 0.93]	0.77 [0.65, 0.86]
Grunwald [43]	2007	Lesion detection	32	5	26	8	0.55 [0.42, 0.68]	0.62 [0.32, 0.86]
Hahn [17]	2009	Lesion detection	18	5	2	4	0.90 [0.68, 0.99]	0.44 [0.14, 0.79]
Vaughan [58]	2009	Lesion detection	77	11	1	0	0.99 [0.93, 1.00]	0.00 [0.00, 0.28]
Kamali [47]	2014	Lesion detection	115	98	11	131	0.91 [0.85, 0.96]	0.57 [0.51, 0.64]
Ohlinger [52]	2014	Lesion detection	89	45		44	0.71 [0.62, 0.79]	0.49 [0.39, 0.60]
Total mean			68	30	15	40		
range			18-115	5-98	1-36	0-131		
Shen [55]	2001	Malignant lesion detection	8	2	3	153	0.73 [0.39, 0.94]	0.99 [0.95, 1.00]
Liu [12]	2008	Malignant lesion detection	49	2	3	34	0.94 [0.84, 0.99]	0.94 [0.81, 0.99]
Total mean (n)			29	2	3	94		
range			8-49	2-2	3-3	34-153		

Table 13: Accuracy rates for use of ductoscopy in women with pathological nipple discharge.

The pooled sensitivities are shown in (Figure 2a-2h).

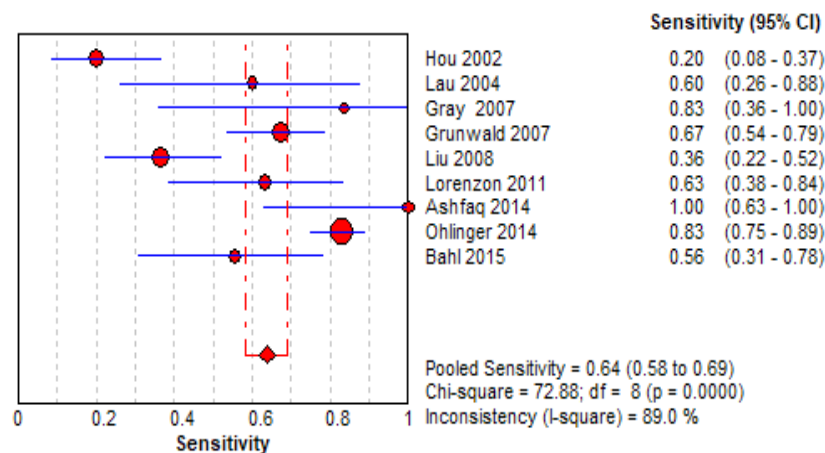


Figure 2a: Pooled sensitivity of ultrasound in women with pathological nipple discharge.

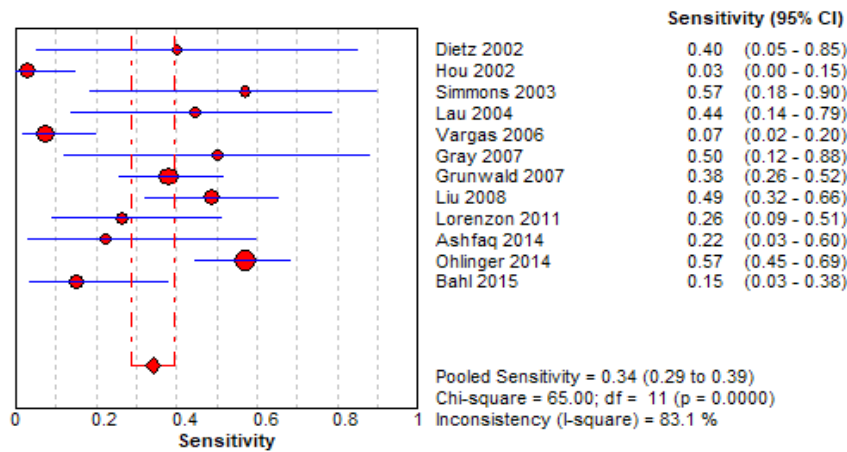

Figure 2b: Pooled sensitivity of mammogram in women with pathological nipple discharge.

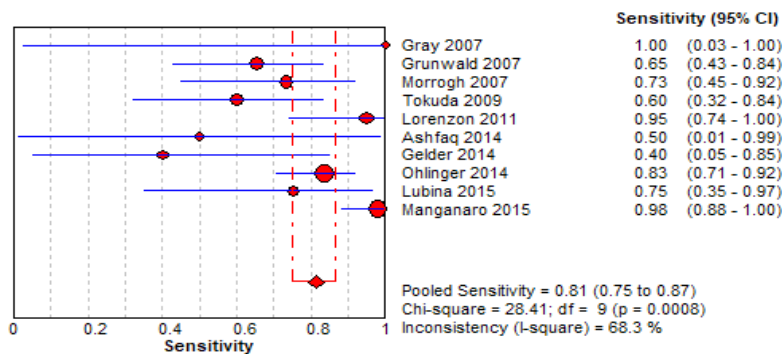


Figure 2c: Pooled sensitivity of breast MRI in women with pathological nipple discharge.

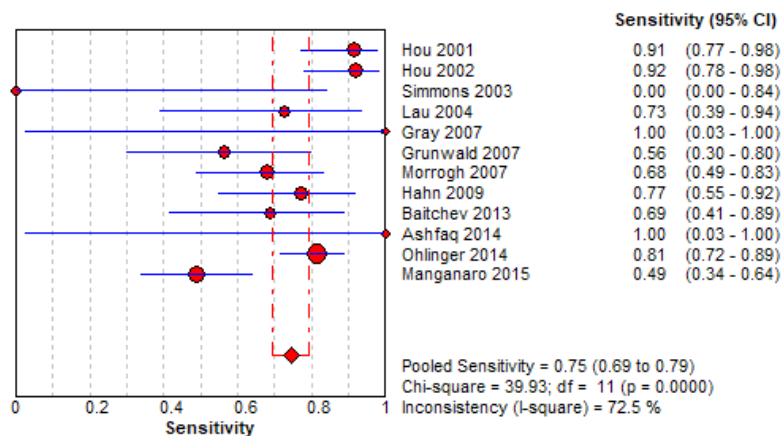


Figure 2d: Pooled sensitivity of conventional galactography in women with pathological nipple discharge.

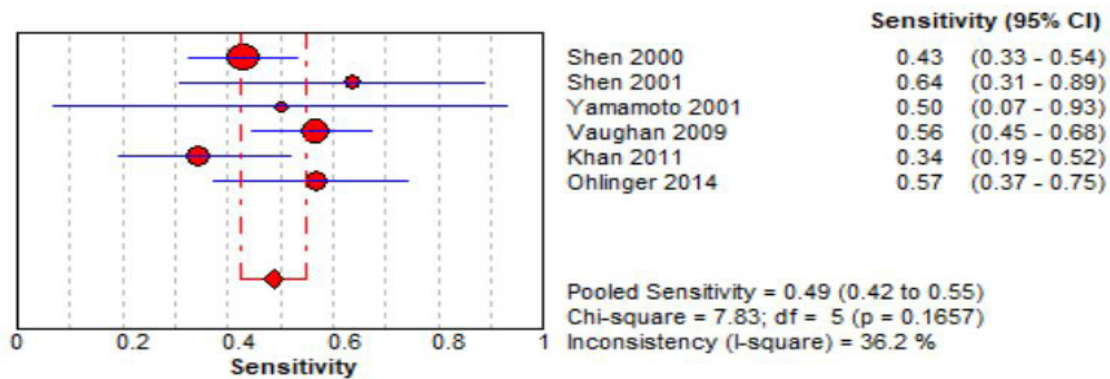


Figure 2e: Pooled sensitivity of nipple discharge smear cytology in women with pathological nipple discharge.

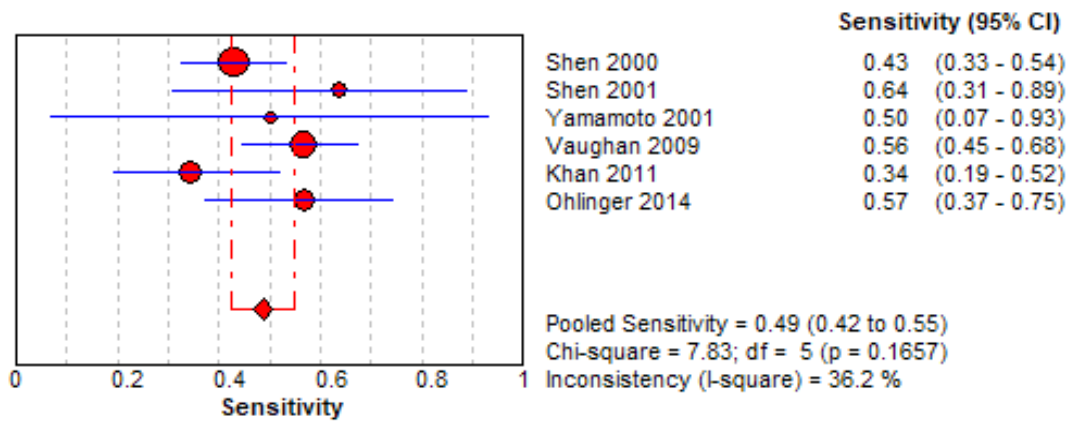


Figure 2f: Pooled sensitivity of ductal lavage cytology in women with pathological nipple discharge.

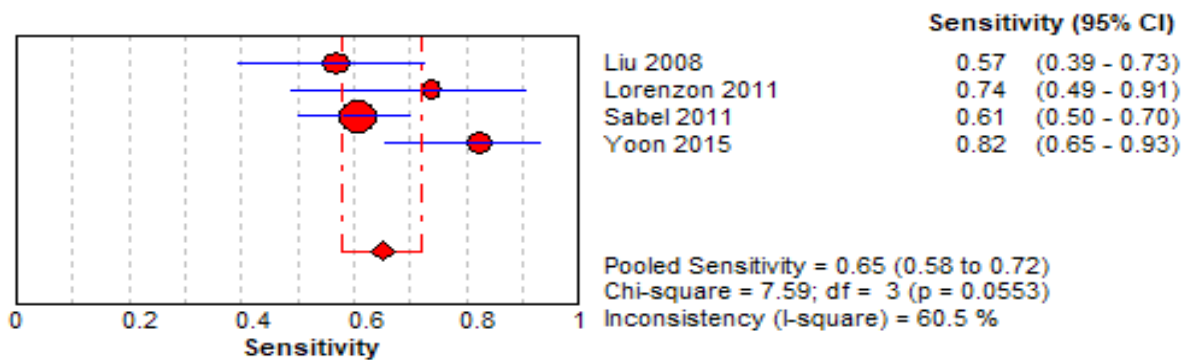


Figure 2g: Pooled sensitivity of mammogram combined with ultrasound in women with pathological nipple discharge.

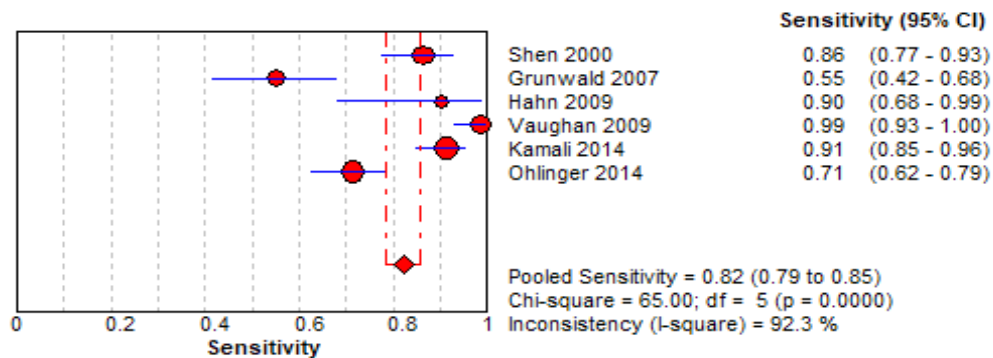


Figure 2h: Pooled sensitivity of ductoscopy in lesion detection.

Mammogram followed by nipple discharge smear cytology had the lowest pooled sensitivities. Mammogram combined with ultrasound resulted in a higher pooled sensitivity. The tests with the highest pooled sensitivities were breast MRI followed by galactography. For ductoscopy, while some studies focused on overall lesion detection, others classified lesions into malignant and non-malignant. Ductoscopy had a pooled sensitivity of 0.82 in lesion detection.

Review question 3: The rates of nipple discharge patients undergoing surgery

A total of 13 studies met the inclusion criteria. The average surgery rate among women with a pathological nipple discharge was 43.4%, with the highest being 83.0% (Cabioglu 2002) and the lowest being 24.0% (Yoon 2015) [18,36]. (Figure 3) shows the surgery rates.

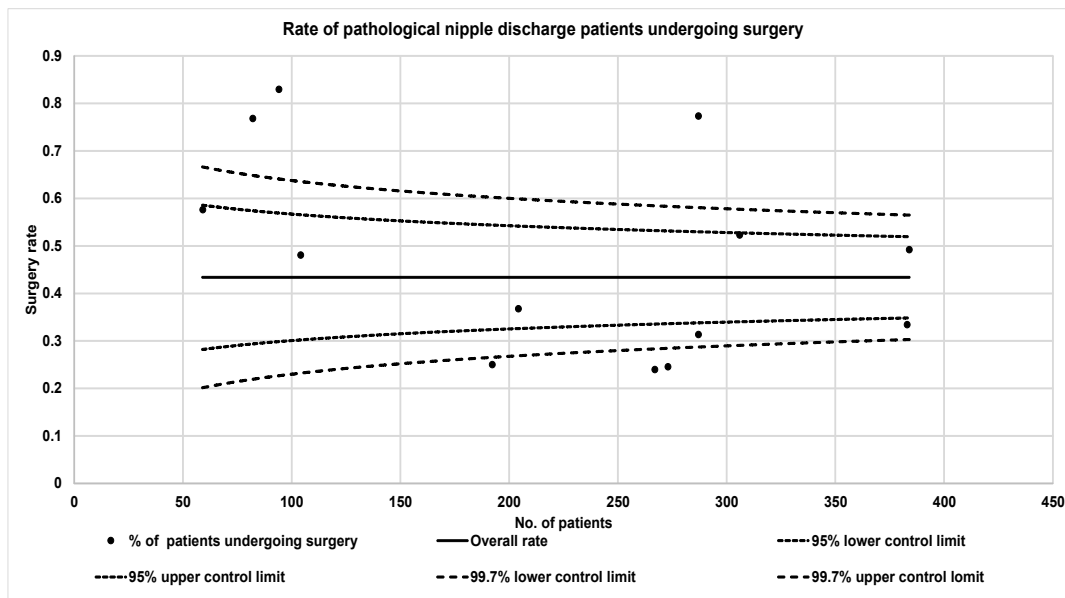


Figure 3: Funnel plot showing the percentage of pathological nipple discharge patients undergoing surgery.

Etiology data was extracted from 3 studies which we were able to group into complementary categories (Table 14). Papillomas (48.1%) followed by ductal ectasia (14.9%) were the main causes of a pathological nipple discharge in women with a tissue diagnosis.

Author	Year	No. with pathology results	Papilloma n (%)	Ductal Ectasia n (%)	Benign/ non-specific changes n (%)	LCIS/ ADH/ Papilloma with Atypia n (%)	Carcinoma n (%)
Cabioglu [63]	2003	94	62 (66.0)	4 (4.3)	8 (8.5)	1 (1.1)	19 (20.2)
Morrogh [32]	2007	182	88 (48.4)	37 (20.3)	11 (6.0)	16 (8.8)	30 (16.5)
Morrogh [33]	2010	287	121 (42.2)	43 (15.0)	28 (9.8)	30 (10.5)	65 (22.6)
Total n (%)		563(100.0)	271 (48.1)	84 (14.9)	47 (8.3)	47 (8.3)	114 (20.2)

Abbreviations: ADH = atypical ductal hyperplasia; LCIS = lobular carcinoma in situ

Table 14: Cause of pathological nipple discharge in women who had a tissue diagnosis.

Discussion

Pathological nipple discharge characterised by unilateral spontaneous bloody or serous exudate from a single duct can be a cause for concern as it can be the underlying sign of breast cancer. Surgery is used to identify those with cancer and pre-malignant changes as well as to manage symptoms [5]. For many of those who undergo duct excision for nipple discharge, few cases reveal an underlying carcinoma [13]. This begets the question of whether a duct excision is necessary for all cases of suspicious nipple discharge. While studies have reported rates of breast cancer in nipple discharge patients ranging from 5.8% to 20.2% it is important to note that these only include patients undergoing surgery and does not account for others [5,18]. Our calculations taking into account patients who underwent surgery, biopsy, or observation show that the average risk of breast cancer is 10.2%. The risk of breast cancer in women with pathological nipple discharge increases with age and has been shown by studies to be much higher in those aged beyond 50. Hence, a surgical approach via central duct excision or microdochectomy is favored to rule out breast cancer in this age group. Most studies reported a higher risk of breast cancer beyond the age of 50 years. However, it would be useful if studies could be conducted to explore the risk of breast cancer in nipple discharge patients according to decades. Other factors to take into account regarding risk of breast cancer include a positive family history of breast cancer and a previous biopsy history [18]. A palpable mass in nipple discharge patients has also been shown to be a predictor of a malignant nipple discharge [11,12,32,36]. Morrogh et al. (2007) reported that only large volume nipple discharge appeared to be predictive of breast cancer [32]. Patients with spontaneous nipple discharge are also at an increased risk of breast cancer if they had a higher number of pregnancies and a longer period of lactation, and the possibility of breast cancer in patients with provoked nipple discharge should also be considered [42].

Sabel et al (2012) mentioned that the reason why it was recommended that all women with pathological nipple discharge underwent duct excision was because of the inadequate sensitivity

of diagnostic modalities in the past [23]. This is supported by Gray et al. that there was no clear consensus on what diagnostic modality could reliably differentiate benign etiologies comprising a large number of patients from those with carcinoma comprising the relatively few patients [13]. Our meta-analysis showed that in patients with nipple discharge, breast MRI had the highest pooled sensitivity followed by galactography, and that mammography and nipple discharge smear cytology had the lowest pooled sensitivities. However, combinations of modalities, such as ultrasound and mammogram led to a higher sensitivity. As highlighted by Dolan et al. the limitations of cytology are that it has a high non-diagnostic rate, leads to a low number of cancers diagnosed using this technique, and is unable to distinguish between carcinoma in and invasive cancers [11]. Technical problems also result from insufficient retrieval of cellular material leading to an inconclusive result. Mammography has low sensitivity for nipple discharge patients as retroareolar lesions are often small and intraductal and lack calcifications. In addition Bahl et al. reported that in the 70% of patients who had normal mammogram but abnormal ultrasound findings, there were extremely dense breasts which can obscure breast and intraductal abnormalities [31]. Breast MRI has been shown to demonstrate the location and distribution most clearly, especially for a ductal carcinoma in situ [65]. It also has a high sensitivity for papillomas [66]. However, according to van Gelder et al., it does not have an added value in the evaluation of patients who have no signs of a malignancy on conventional diagnostic examinations, with malignancy being demonstrated in less than 2% [42].

Explanation for Variations

The Cochran-Q value and I² test showed that there was statistically significant variability in the sensitivities of the various diagnostic tests. This can be attributed to patient selection, and differing criteria for a positive test as well as local expertise and interpretation. For example, Hou et al. (2002) reported good results for galactography that was due to the use of a monofilament polypropylene guiding suture that eased cannulation, and the

availability of a pathologist on site to identify intraductal lesions together with the surgeon once the affected ducts were opened during the operation [45]. For studies on ductoscopy, while some studies focused on lesion detection, others differentiated between benign and malignant appearing lesions. Classifying lesions according to the system proposed by Makita et al. and Al Sarakbi et al. would depend on surgeon experience in differentiating the lesions. Another factor leading to variability would be the number of features of pathological nipple discharge i.e. unilateral, clear or bloody, and spontaneous considered in each study [30]. Variations in the breast cancer rates in consecutive nipple discharge patients are likely to be due to patient selection [30]. While 4.7% of patients were found to have cancer in the studies of Sabel et al. and Vargas et al., 23.7% of patients in the study of Morrogh et al. (2010) were found to have breast cancer (Table 1) [23,5,33]. This could be because the patients in Morrogh et al. study presented over a ten-year period and were selected to further undergo cytologic examination, ductography, or MRI followed by needle biopsy with or without surgery [30]. Variations in the breast cancer rates of nipple discharge patients with a tissue diagnosis are likely to be due to patient selection as well, along with differing diagnostic tests used to select patients for surgery. For example, some practices use ductography or MRI in addition to ultrasound and mammogram for nipple discharge. Some studies looked at biomarkers in nipple aspirate fluid, nipple discharge and ductal washings such as microsatellite alterations, chromosomal aneusomy and proteins and carbohydrates [67-69]. These were not included in our meta-analysis as there were too few reported for each biomarker for a pooled analysis. Novel methods such as mammary ductoscopy by helical CT, direct and indirect galactography and scintimammography were also not included for the same reason.

Conclusion

As the yield of malignancy can be low when nipple discharge patients undergo excision, stricter guidelines regarding the need for interventions is needed. A malignancy rate of 10.2% indicates the need to continue surgery, especially for patients aged over 50 years old. Younger patients below 50, in the absence of risk factors such as family history, a palpable mass, an increased period of lactation or a high-volume discharge, can be managed conservatively with close follow up. We also carried out the first meta-analysis involving pooled sensitivities of diagnostic modalities for women with pathological nipple discharge. Our final recommendation for practical diagnostic work up of patients with nipple discharge would include a step-up approach from combined clinical examination and mammography with ultrasound, to selective additional investigation to include individualized request for nipple fluid cytology, MRI Breast and, in selective units, ductoscopy in selected patients. Irrespective of all investigations in high risk patients either microdochotomy or central duct excision

may be indicated.

References

1. Mansel RE, Webster DJT, Sweetland HM (2009) Hughes, Mansel & Webster's Benign Disorders and Diseases of the Breast 2009.
2. Seltzer MH (2004) Breast Complaints, Biopsies, and Cancer Correlated with Age in 10,000 Consecutive New Surgical Referrals. *Breast J* 10: 111-117.
3. Seow JH-S, Metcalf C, Wylie E (2011) Nipple discharge in a screening programme: Imaging findings with pathological correlation. *J Med Imaging Radiat Oncol* 55: 577-586.
4. Sickles EA (2000) Galactography and other imaging investigations of nipple discharge 356: 1622-1623.
5. Vargas HI, Vargas MP, Eldrageely K, Gonzalez KD, Khalkhali (2006) Outcomes of clinical and surgical assessment of women with pathological nipple discharge. *Am Surg* 72: 124-128.
6. National Guideline Clearinghouse Common breast problems. Rockville MD: Agency for Healthcare Research and Quality (AHRQ).
7. National Guideline Clearinghouse. Diagnosis of breast disease. Rockville MD: Agency for Healthcare Research and Quality (AHRQ).
8. Zervoudis S, Economides P, Iatrakis G, Polyzos D, Lykeridou K, et al. (2008) Nipple discharge: evaluation and management. *Gineco Ro* 4: 230-237.
9. Salzman B, Fleegle S, Tully AS (2012) Common breast problems. *Am Fam Physician* 86: 343-349.
10. Bevers TB, Anderson BO, Bonaccio E, Buys S, Daly MB, et al. (2009) Breast cancer screening and diagnosis: Clinical practice guidelines in oncologyTM. *JNCCN J Natl Compr Cancer Netw* 7: 1060-1096.
11. Dolan RT, Butler JS, Kell MR, Gorey TF, Stokes MA (2010) Nipple discharge and the efficacy of duct cytology in evaluating breast cancer risk. *Surgeon* 8: 252-258.
12. Liu G, Lu JS, Shen KW, Wu J, Chen CM, et al. (2008) Fiberoptic ductoscopy combined with cytology testing in the patients of spontaneous nipple discharge. *Breast Cancer Res Treat* 108: 271-277.
13. Gray RJ, Pockaj BA, Karstaedt PJ (2007) Navigating murky waters: a modern treatment algorithm for nipple discharge. *Am J Surg* 194: 850-854.
14. Vargas HI, Romero L, Chlebowski RT (2002) Management of bloody nipple discharge. *Curr Treat Options Oncol* 3: 157-161.
15. Ingvar C (2002) Papillary secretion. Diagnostic assessment and treatment. *Scand J Surg* 91: 246-250.
16. Lang JE, Kuerer HM (2007) Breast ductal secretions: Clinical features, potential uses, and possible applications. *Cancer Control* 14: 350-359.
17. Hahn M, Fehm T, Solomayer EF, Siegmann KC, Hengstmann AS, et al. (2009) Selective microdochectomy after ductoscopic wire marking in women with pathological nipple discharge. *BMC Cance* 9: 151.
18. Cabioglu N, Hunt KK, Singletary SE, Stephens TW, Marcy S, et al. (2003) Surgical decision making and factors determining a diagnosis of breast carcinoma in women presenting with nipple discharge. *J Am Coll Surg* 196: 354-364.

19. Patel BK, Falcon S, Drukteinis J (2015) Management of nipple discharge and the associated imaging findings. *Am J Med* 128: 353-360.
20. King TA, Carter KM, Bolton JS, Fuhrman GM, Campbell SD, et al. (2000) A simple approach to nipple discharge. *Am Surg* 66: 960-966.
21. Willett AM, Michell MJ, Lee MJR (2010) Best practice diagnostic guidelines for patients presenting with breast symptoms 2010.
22. BCMA (2013) Breast Disease and Cancer: Diagnosis. *Clin Pract Guidel Protoc Br Columbia* 2013.
23. Sabel MS, Helvie MA, Breslin T, Curry A, Diehl KM, et al. (2012) Is duct excision still necessary for all cases of suspicious nipple discharge? *Breast J* 18: 157-162.
24. Kocdor MA, Sevinc AI, Canda T, Balci P, Saydam S, et al. (2009) Pathologic nipple discharge in patients with radiologically invisible mass: Review of 28 consecutive sub-areolar explorations. *Breast J* 15: 230-235.
25. Lubina N, Schedelbeck U, Roth A, Weng AM, Geissinger E, et al. (2015) 3.0 Tesla breast magnetic resonance imaging in patients with nipple discharge when mammography and ultrasound fail. *Eur Radiol. Germany* 25: 1285-1293.
26. Ashfaq A, Senior D, Pockaj BA, Wasif N, Pizzitola VJ, et al. (2014) Validation study of a modern treatment algorithm for nipple discharge. *Am J Surg* 208: 222-227.
27. Kooistra BW, Wauters C, van de Ven S, Strobbe L (2009) The diagnostic value of nipple discharge cytology in 618 consecutive patients. *Eur J Surg Oncol* 35: 573-577.
28. Sardanelli F, Giuseppetti GM, Canavese G, Cataliotti L, Corcione S, et al. (2008) Indications for breast magnetic resonance imaging. Consensus document "Attualita in senologia", Florence 2007. *Radiol Med* 113: 1085-1095.
29. Foulkes RE, Heard G, Boyce T, Skyrme R, Holland PA, et al. (2011) Duct excision is still necessary to rule out breast cancer in patients presenting with spontaneous bloodstained nipple discharge. *Int J Breast Cancer* 2011.
30. Whiting PF, Rutjes AWS, Westwood ME, Mallett S, Deeks JJ, et al. (2011) Quadas-2: A revised tool for the quality assessment of diagnostic accuracy studies. *Ann Intern Med* 155: 529-536.
31. Dinkel HP, Gassel AM, Muller T, Lourens S, Rominger M, et al. (2001) Galactography and exfoliative cytology in women with abnormal nipple discharge. *Obstet Gynecol* 97: 625-629.
32. Morrogh M, Morris EA, Liberman L, Borgen PI, King TA, et al. (2007) The predictive value of ductography and magnetic resonance imaging in the management of nipple discharge. *Ann Surg Oncol* 14: 3369-3377.
33. Morrogh M, Park A, Elkin EB, King TA (2010) Lessons learned from 416 cases of nipple discharge of the breast. *Am J Surg* 200: 73-80.
34. Khan SA, Mangat A, Rivers A, Revesz E, Susnik B, et al. (2011) Office ductoscopy for surgical selection in women with pathologic nipple discharge. *Ann Surg Oncol* 18: 3785-3790.
35. Bahl M, Baker JA, Greenup RA, Ghate SV (2015) Diagnostic Value of Ultrasound in Female Patients with Nipple Discharge. *AJR Am J Roentgenol* 205: 203-208.
36. Yoon H, Yoon JH, Kim E-K, Moon HJ, Park B-W, et al. (2015) Adding Ultrasound to the Evaluation of Patients with Pathologic Nipple Discharge to Diagnose Additional Breast Cancers: Preliminary Data. *Ultrasound Med Biol* 41: 2099-2107.
37. Yang L, Wu D, Fan ZM (2015) Retrospective analysis of pathologic nipple discharge. *Genet Mol Res* 14: 1443-1449.
38. Dillon MF, Mohd Nazri SR, Nasir S, McDermott EW, Evoy D, et al. (2006) The role of major duct excision and microdochectomy in the detection of breast carcinoma. *BMC Cancer* 6: 164.
39. Lau S, Küchenmeister I, Stachs A, Gerber B, Krause A, et al. (2005) Pathologic nipple discharge: surgery is imperative in postmenopausal women. *Annals of surgical oncology* 12: 546-551.
40. Baitchev G, Gortchev G, Todorova A, Dikov D, Stancheva N, et al. (2003) Intraductal aspiration cytology and galactography for nipple discharge. *International surgery* 88: 83-86.
41. Dietz JR, Crowe JP, Grundfest S, Arrigain S, Kim JA (2002) Directed duct excision by using mammary ductoscopy in patients with pathologic nipple discharge. *Surgery* 132: 582-588.
42. Van Gelder L, Bisschops RHC, Menke-Pluymers MBE, Westenend PJ, Plaisier PW (2015) Magnetic resonance imaging in patients with unilateral bloody nipple discharge; useful when conventional diagnostics are negative? *World J Surg* 39: 184-186.
43. Grunwald S, Heyer H, Paepke S, Schwesinger G, Schimming A, et al. (2007) Diagnostic value of ductoscopy in the diagnosis of nipple discharge and intraductal proliferations in comparison to standard methods. *Oncology Research and Treatment* 30: 243-248.
44. Hou MF, Huang TJ, Liu GC (2001) The diagnostic value of galactography in patients with nipple discharge. *Clinical imaging* 25: 75-81.
45. Hou MF, Tsai KB, Ou-Yang F, Lin HJ, Liu CS, et al. (2002) Is a one-step operation for breast cancer patients presenting nipple discharge without palpable mass feasible?. *The Breast* 11: 402-407.
46. Kalu ON, Chow C, Wheeler A, Kong C, Wapnir I (2012) The diagnostic value of nipple discharge cytology: breast imaging complements predictive value of nipple discharge cytology. *Journal of surgical oncology* 106: 381-385.
47. Kamali S, Harman Kamali G, Akan A, Simsek S, Bender O (2014) Use of ductoscopy as an additional diagnostic method and its applications in nipple discharge. *Minerva Chir* 69: 65-73.
48. Kaplan R, Hoda SA, Hoda RS (2013) Cytological evaluation of bloody nipple discharge fluid. *Diagnostic cytopathology* 41: 183-185.
49. Lee WY (2003) Cytology of abnormal nipple discharge: a cyto-histological correlation. *Cytopathology* 14: 19-26.
50. Lorenzon M, Zuiani C, Linda A, Londero V, Girometti R, et al. (2011) Magnetic resonance imaging in patients with nipple discharge: should we recommend it?. *European radiology* 21: 899-907.
51. Manganaro L, D'Ambrosio I, Gigli S, Di Pastena F, Giraldi G, et al. (2015) Breast MRI in patients with unilateral bloody and serous-bloody nipple discharge: a comparison with galactography. *BioMed research international* 2015.
52. Ohlinger R, Stomps A, Paepke S, Blohmer JU, Grunwald S, et al. (2014) Ductoscopic detection of intraductal lesions in cases of pathologic nipple discharge in comparison with standard diagnostics: the German multicenter study. *Oncology research and treatment* 37: 628-632.

53. Pritt B, Pang Y, Kellogg M, St John T, Elhosseiny A (2004) Diagnostic value of nipple cytology. *Cancer Cytopathology* 102: 233-238.
54. Shen KW, Wu J, Lu JS, Han QX, Shen ZZ, et al. (2000) Fiberoptic ductoscopy for patients with nipple discharge. *Cancer* 89: 1512-1519.
55. Shen KW, Wu J, Lu JS, Han QX, Shen ZZ, et al. (2001) Fiberoptic ductoscopy for breast cancer patients with nipple discharge. *Surgical endoscopy* 15: 1340-1345.
56. Simmons R, Adamovich T, Brennan M, Christos P, Schultz M, et al. (2003) Nonsurgical evaluation of pathologic nipple discharge. *Annals of Surgical oncology* 10: 113-116.
57. Tokuda Y, Kuriyama K, Nakamoto A, Choi S, Yutani K, et al. (2009) Evaluation of suspicious nipple discharge by magnetic resonance mammography based on breast imaging reporting and data system magnetic resonance imaging descriptors. *Journal of computer assisted tomography* 33: 58-62.
58. Vaughan A, Crowe JP, Brainard J, Dawson A, Kim J, et al. (2009) Mammary ductoscopy and ductal washings for the evaluation of patients with pathologic nipple discharge. *The breast journal* 15: 254-260.
59. Yamamoto D, Shoji T, Kawanishi H, Nakagawa H, Haijima H, et al. (2001) A utility of ductography and fiberoptic ductoscopy for patients with nipple discharge. *Breast cancer research and treatment* 70: 103-108.
60. Lian Z-Q, Wang Q, Zhang A-Q, Zhang J-Y, Han X-R, et al. (2015) A nomogram based on mammary ductoscopic indicators for evaluating the risk of breast cancer in intraductal neoplasms with nipple discharge. *Breast Cancer Res Treat* 150: 373-380.
61. Sauter ER, Klein-Szanto A, Ehya H, MacGibbon B (2004) Ductoscopic cytology and image analysis to detect breast carcinoma. *Cancer* 101: 1283-1292.
62. Sauter ER, Klein-Szanto A, Macgibbon B, Ehya H (2010) Nipple aspirate fluid and ductoscopy to detect breast cancer. *Diagn Cytopathol* 38: 244-251.
63. Zielinski J, Jaworski R, Irga-Jaworska N, Haponiuk I, Jaskiewicz J (2015) The significance of ductoscopy of mammary ducts in the diagnostics of breast neoplasms 10: 79-86.
64. Beechey-Newman N, Kulkarni D, Kothari A, Culora G (2005) Throwing light on nipple discharge. *Breast J. United States* 11: 138-139.
65. Nakahara H, Namba K, Watanabe R, Furusawa H, Matsu T, et al. (2003) A comparison of MR imaging, galactography and ultrasonography in patients with nipple discharge. *Breast Cancer* 10: 320-329.
66. Kramer SC, Rieber A, Gorich J, Aschoff AJ, Tomczak R, et al. (2000) Diagnosis of papillomas of the breast: value of magnetic resonance mammography in comparison with galactography. *Eur Radiol* 10: 1733-1736.
67. Sauter ER, Shan S, Hewett JE, Speckman P, Du Bois GC (2005) Proteomic analysis of nipple aspirate fluid using SELDI-TOF-MS. *Int J Cancer. United States* 114: 791-796.
68. Deutscher SL, Dickerson M, Gui G, Newton J, Holm JE, et al. (2010) Carbohydrate antigens in nipple aspirate fluid predict the presence of atypia and cancer in women requiring diagnostic breast biopsy. *BMC Cancer* 10: 519.
69. Zhang K, Zhao S, Wang Q, Yang H-S, Zhu J, et al. (2015) Identification of microRNAs in Nipple Discharge as Potential Diagnostic Biomarkers for Breast Cancer. *Ann Surg Oncol* 3: 536-544.