

Case Study

An Unusual Case of Emphysematous Cystitis in Non Diabetes Metastatic Lung Cancer Patient Undergoing Chemotherapy

Marwane Andaloussi Benatiya¹, Ghizlane Rais^{2*}

¹Department of Urology, Hassan 2 Hospital, Agadir, Morocco

²Department of Medical Oncology, Regional Center of Oncology, Agadir, Morocco

*Corresponding author: Rais Ghizlane, Medical Oncology Department, Regional Center of Oncology, Agadir, Morocco. Email: medghiz@hotmail.com

Citation: MA Benatiya, G Rais (2018) An Unusual Case of Emphysematous Cystitis in Non Diabetes Metastatic Lung Cancer Patient Undergoing Chemotherapy. Emerg Med Inves: EMIG-178. DOI: 10.29011/2475-5605. 000078

Received Date: 06 June, 2018; **Accepted Date:** 15 June, 2018; **Published Date:** 25 June, 2018

Abstract

Emphysematous cystitis is a rare and severe infection of the bladder wall and/or lumen that causes gas accumulation in the tissues. The gas is mainly produced by gram-negative bacteria such as *E. coli* or fungal pathogens. Emphysematous cystitis most often occurs in older women with poorly controlled diabetes. It has a fulminating course, and can be fatal if not recognized and treated promptly.

We report a case of a 45-year-old male, under chemotherapy for metastatic lung cancer, presented with fever, dysuria, and pneumaturia. Emphysematous cystitis diagnosed by a computed tomography scan. The treatment was based on antibiotics associated with bladder drainage.

The purpose of presenting this case report is not only to report an uncommon case of emphysematous cystitis but also to raise awareness among clinicians that this rare entity can occur in non diabetes patients, during chemotherapy

Introduction

Emphysematous Cystitis (EC) is a relatively rare disease characterized by the presence of gas in the bladder wall and/or lumen. The primary risk factor of emphysematous cystitis is diabetes mellitus [1]. Other risk factors include neurogenic bladder, urinary tract outlet obstruction, chronic urinary tract infections, UTIs, indwelling urethral catheters, and immune-deficiency [2]. The spectrum of clinical presentation of EC is non-specific and can range from minimally symptomatic urinary tract infection to a scenario of peritonitis and septic shock [3]. The occurrence during chemotherapy and the absence of medical history of diabetes or other risk factor often reported in the literature, are two remarkable characteristics described in this case report.

Observation

Patient presented to our department with three days history of fever, chills, dysuria and pneumaturia. In his past medical history, we don't find notion of mellitus diabetes. He had a 25-year history of tobacco use, smoking one pack of cigarettes per day,

but had no additional risk factors. He was followed in medical oncology department for metastatic lung cancer undergoing palliative chemotherapy with Paclitaxel-Carboplatin protocol. He was on day 13 of the third cycle of chemotherapy.

Physical examination revealed a temperature of 39°C, normal blood pressure and a pulse rate of 95 bpm. On palpation, we found a hypogastric sensitivity. The patient's urine was dark and cloudy. Cardiac and pulmonary examinations were unremarkable. Laboratory evaluation showed a normal glucose level of 1,1g/dl. Blood count revealed 19.000 white blood cells/mm³, hemoglobin 9,3gm/dl, sodium 132mmol/l, potassium 4,5mmol/l, Chlorid 80mmol/l. The C-Reactive Protein (CRP) was 160 mg/dl. The transaminase enzyme levels were normal. Urine analysis revealed cloudy urine, pH 5,5 with numerous white and red blood cells on microscopy. The diagnosis of emphysematous cystitis was made based on the CT scan. Abdomino-pelvic image showed presence of intraluminal gas and thickening of the bladder wall (Figure 1,2). There were no findings of ureteral obstruction or pyelonephritis. He was empirically treated with association of ciprofloxacin and

ceftriaxone and he was catheterized with an 20 Fr Foley catheter.

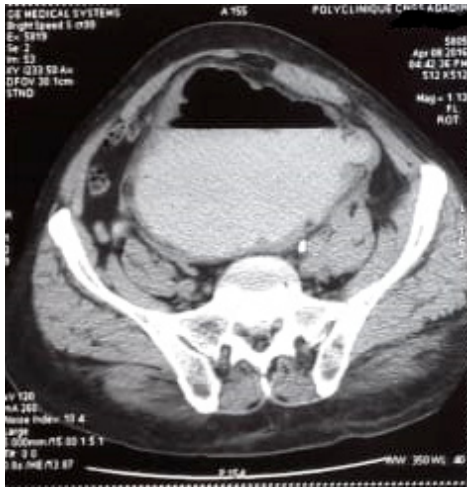


Figure 1: CT scan of the pelvis showing gas in the bladder and the bladder wall.

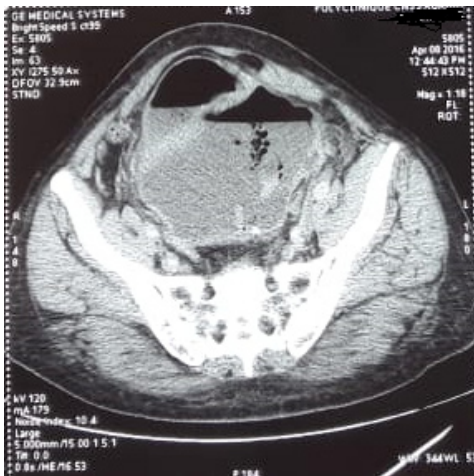


Figure 2: Pelvic computed tomography demonstrating emphysematous changes in the bladder wall.

The patient's clinical status improved. He became afebrile and decline in his white cell count on day 3 and his catheter was removed on day 15. Urine culture grew *Escherichia coli*, and based on sensitivities, he continued antibiotics with Ciprofloxacin. A repeat urine culture was sterile on the 20th day of the antibiotic treatment then referred to medical oncology department to continue his cancer care.

Discussion

Emphysematous cystitis (EC) as within the urinary tract was initially described in 1671, in the case of a man presenting with pneumaturia [4]. Although rare, these infection is more common than is suggested by the approximately 200 cases that are currently

documented in the literature as case reports and cases series [5]. The pathogenesis of EC is not completely understood. Elevated tissue glucose levels in diabetic patients may provide a more favorable microenvironment for gas-forming microbes. However, bacterial gas production does not fully explain the pathologic and clinical manifestations of emphysematous UTIs [5,6].

On reviewing the literature on EC, persons at risk of the disease are the elderly women (most patients were over age 60), diabetics and patients with an immunosuppressive co-morbidity and/or urinary tract outlet obstruction, such as a neurogenic bladder [1,6]. To the best of our knowledge, our case is the first report of emphysematous cystitis occurring during cancer treatment by chemotherapy. Our patient has received three cycles of chemotherapy according Paclitaxel-Carboplatin protocol. Severe infections associated with this association and reported in several phase III trials are around 5%.

The presentation of EC varies widely, ranging from asymptomatic features to septic shock [1-6]. A pathognomonic sign of circumferential, acoustic shadowing around the bladder wall is rarely noted. According to a literature review, the most frequent symptoms and findings on physical examination are abdominal pain, pneumaturia after catheterisation and urinary retention, noted 80%, 70% and 60% of the patients, respectively [8]. In this case, our patient was in immunosuppressive condition caused by chemotherapy and presented with fever, dysuria, and pneumaturia which strongly suggested the diagnosis of emphysematous cystitis.

As reported in the literature, two-thirds of EC are caused by *E. coli*; the remaining third are caused by *Enterobacter* species, *Clostridium* species, *Klebsiella pneumoniae*, *Staphylococcus aureus*, or *Proteus mirabilis*, *Candida* species may also be responsible [1,3,9]. The pathogen agent in our case was *E. coli*, which was sensitive to Ceftriaxone and Quinolones. The diagnosis of EC is established by radiological findings. Every patient with urinary tract infection who seems to be severely ill should have preferably a pelvic C scan to detect emphysematous complications. EC is aggressive and has a good prognosis with rapid healing when appropriately treated. A delay in diagnosis may cause bladder rupture, septicemia, peritonitis and death. Failure to recognize or diagnose this condition early in the course of the infection increases the associated mortality rate by up to 10% [1,3,9].

Treatment of EC consists of the administration of antibiotics which should be adjusted to the results of urine culture, bladder drainage and the treatment of co-morbid disorders. Endovenous antibiotics, such as fluoroquinolones, penicillin with beta-lactamase inhibitors and third generation cephalosporines, are some of the appropriate treatments. Antifungal agents may be used in cases of a fungal infection. In different published cases, the duration of treatment varied from 1 to 3 weeks [6-11].

Surgical interventions, such as debridement or partial cystectomy, may be required for patients who respond poorly to antibiotics or have necrotizing tissue [10,11]. The prognosis of EC is generally good with an improvement of the patient's condition within the first week. Complications are noted in 10-20% and the mortality rate is low (7%) [1,6,7].

Conclusion

This unusual case reveal that emphysematous cystitis can occur on patient during chemotherapy treatment without other risk factors such as DM. Physicians should be alert to signs of these potentially fatal infections and diagnosis should be followed by the appropriate combination of medication and surgical intervention, if needed.

Reference

1. Thomas AA, Lane BR, Thomas AZ, Remer EM, Campbell SC, et al. (2007) Emphysematous cystitis: a review of 135 cases. *BJU Int* 100: 17-20.
2. Mokabberi R, Ravakhah K (2007) Emphysematous urinary tract infections: diagnosis, treatment and survival (Case review series). *Am J Med Sci* 333111-333116.
3. Bracq A, Fourmarier M, Bourgninaud O, Boutemy F (2004) Emphysematous cystitis complicated by bladder perforation: diagnosis and treatment of a rare case. *Prog Urol* 14: 87-89.
4. Holesh S (1969) Gas in the bladder. Cystitis emphysematosa. *Clin Radiol* 20: 234-236.
5. Gargouri MM, Abid K, Kallel Y, Rhouma SB, Chelif MY (2015) Nourira Severe sepsis secondary to emphysematous cystitis . *African Journal of Urology* 21 : 41-43.
6. Pérez Fentes D, Blanco Parra M, Lema Grille J, Toucedo Caamano V, Novás Castro S, et al. (2009) Emphysematous cystitis: casereport. *Arch Esp Urol* 62: 392-395.
7. Rosell R, Gatzemeier U, Betticher DC, Keppler U, Macha HN, Pirker R, et al. (2002) Phase III randomised trial comparing paclitaxel/carboplatin with paclitaxel/cisplatin in patients with advanced non-small-cell lung cancer: a cooperative multinational trial. *Annals of Oncology* 13: 1539-1549,
8. Holesh S (1969) Gas in the bladder. Cystitis emphysematosa. *Clin Radiol*. 20: 234-236.
9. Grupper M, Kravtsov A, Potasman I (2007) Emphysematous cystitis: illustrative case report and review of the literature. *Medicine (Baltimore)* 86: 47-53.
10. Perlmutter AE, Mastromichaelis M, Zaslau S (2004) Emphysematous cystitis: a case report and literature review. *W V Med J* 100: 232-233.
11. Selley JK, Kane BG, Kane KE (2010) Importance of obtaining a detailed medical history in diagnosing emphysematous cystitis. *J Am Osteopath Asso* 110: 91-94.
12. Reese AC, Stoller ML (2010) Emphysematous cystitis *Urology*. 75 : pp. 1315-1316