



## Cuff Tear Arthropathy Following Non-Operative Treatment of Massive Rotator Cuff Tears - a Long Term Study

Netanel Agajany<sup>1</sup>, Yair Barzilay<sup>2</sup>, Charles Milgrom<sup>3</sup>, Ori Safran<sup>3</sup>, Shaul Beyth<sup>3\*</sup>

<sup>1</sup>Assaf Harofeh Medical Center, Zrifin, Israel

<sup>2</sup>Department of Orthopedic Surgery, Spine Surgery Center, Shaare Zedek Medical Center, Jerusalem, Israel

<sup>3</sup>Department of Orthopedic Surgery, Hadassah University Hospital, Jerusalem, Israel

\*Corresponding author: Shaul Beyth, Department of Orthopedic Surgery, Hadassah University Hospital, Jerusalem, P.O.B. 12000, Zip code 91120, Israel. Tel: +97226776342; Fax: +97226423074; Email: sbeyth@hadassah.org.il

**Citation:** Agajany N, Barzilay Y, Milgrom C, Safran O, Beyth S (2018) Cuff Tear Arthropathy Following Non-Operative Treatment of Massive Rotator Cuff Tears - a Long Term Study. J Orthop Ther: JORT-198. DOI: 10.29011/2575-8241. 000098

**Received Date:** 16 May, 2018; **Accepted Date:** 18 May, 2018; **Published Date:** 25 May, 2018

### Summary

**Background:** Massive Rotator Cuff Tear (RCT) may result in Cuff Tear Arthropathy (CTA) which is a complete derangement of the glenohumeral joint. In order to avoid CTA, patients are advised to undergo surgical repair of the tendon whenever possible. Yet, since little is known of the long-term natural history of massive RCT and the incidence of CTA in patients who were treated non-operatively. This research aims to fill this current gap in knowledge.

**Methods:** We reviewed shoulder ultrasound examinations performed by a senior musculoskeletal radiologist, between 1997-2002. We identified a cohort of 53 patients who were diagnosed with massive cuff tear and didn't undergo surgery. Patients who met inclusion criteria were evaluated radio-graphically and clinically by the DASH and Constant for the presence and severity of CTA, according to Seebauer's classification.

**Results:** 53 patients with 59 massive rotator cuff tears did not undergo surgery. Of those, 21 were unavailable for the study and 13 did not meet inclusion criteria. Of 25 shoulders examined (follow up 14.9 years  $\pm$  1.3), 22 shoulders (88%) had radiographic evidence of CTA while 13 patients (52%) had Seebauer IA CTA, and 9 had Seebauer IIA CTA (36%). Significant correlation was found between the average severity of the CTA and the time elapsed since the initial diagnosis.

**Conclusion:** The long-term natural history of massive RCT under non-operative management is not favorable, as regards the possibility of developing CTA. We recommend that patients who suffer from massive RCT and poor functional ability should consider undergo surgery.

**Keywords:** Arthropathy; Clinical Outcome; Incidence; Long Term; Massive Cuff Tear; Rotator Cuff

### Introduction

The rotator cuff is a term describing a system of muscles and tendons located at the shoulder, which consists of four muscles: Supraspinatus, Infraspinatus, Teres minor, and Subscapularis. Its function is to stabilize the humeral head in the Glenoid's fossa, and to enable the middle to final range of motion of the shoulder joint [1]. A Rotator Cuff Tear (RCT) is one of the most common pathologies of the shoulder. The prevalence of this injury increases with age, but is also seen in young athletic patients, usually due to sports or other traumatic injuries [2]. The RCT can be either the result of a traumatic tear or a degenerative tear. The former is usually symptomatic and presents itself with pain and range

restriction, at the acute phase. In contrast, a degenerative tear, which is more common, is mostly asymptomatic at least in its initial phases, hence the importance of the radiographic imaging [3]. In both cases the size of the tear can vary between a small tear (up to 1 cm) and a massive tear (larger than 5 cm) [4]. The more severe the tear, the more tendons are affected [3,5].

Other than the signs and symptoms of the actual tear, several later complications can occur as a result of it. One of these complication is a rotator Cuff Tear Arthropathy (CTA) [6-8]. CTA is defined as degenerative arthritis of the shoulder joint, caused by a rotator cuff tear, and it consists of three main common features: (1) Rotator cuff insufficiency, (2) degenerative changes of the glenohumeral joint; and (3) humeral head superior migration. Neer [7] hypothesized that the CTA develops due to a combination of mechanical and nutritional causes. The mechanical theory states

that humeral head instability in the glenoid leads to a superior migration toward the acromion. This migration causes erosions in the humerus and scapula. According to the nutritional theory, the superior migration causes synovial fluid leak, and as a result, prevents the joint's cartilage from receiving vital nutrients, which in turn results in the destruction of the joint [1,7,9].

There are several classifications which grade the degree of arthropathy by relying on radiographic findings, the most commonly used is Seebauer's classification [10,11]. This classification differentiates a degenerative process in the glenohumeral joint when the humeral head is centered, parallel to the glenoid, and a degeneration where the humeral head is superior, adjacent to the acromion. This classification defines four pathologic conditions which are divided into two sub-groups [11] (Table 1).

I. Centered - Minimal superior migration of humeral head		II. Decentered - Severe superior migration of the humeral head	
<p>IA. Stable: Intact anterior restraints</p> <ul style="list-style-type: none"> <li>Minimal superior migration.</li> <li>Dynamic joint stabilization.</li> <li>Acetabularization of coracoacromial arch and femoralization of humeral head.</li> </ul>	<p>IB. Medialized: Intact anterior restraints/ force couple intact</p> <ul style="list-style-type: none"> <li>Minimal superior migration.</li> <li>Compromised dynamic joint stabilization.</li> <li>Medial erosion of the glenoid.</li> </ul>	<p>IA: Limited stable: Compromised anterior restraints / compromised force couple</p> <ul style="list-style-type: none"> <li>Superior translation of Humerus.</li> <li>Insufficient dynamic joint stabilization.</li> <li>Minimal stabilization by Coracoacromial arch.</li> <li>Superomedial erosion of Glenoid</li> </ul>	<p>IIB: Unstable: Incompetent anterior structures</p> <ul style="list-style-type: none"> <li>Anterior superior escape.</li> <li>Absent dynamic joint stabilization.</li> <li>No stabilization by Coracoacromial arch.</li> </ul>

**Table 1:** Classification of Cuff tear arthropathy.

Generally, RCT does not heal spontaneously. Therefore, the treatment can be either conservative, which will not repair the tear but could help reduce the symptoms, or surgical, with the goal of mending the tear and restoring full shoulder function. The conservative treatment includes pharmaceutical measures, such as steroid injections; physical measures, such as warming the joint and physical therapy for the surrounding muscles; and watchful waiting. Though clinical improvement can appear, current data shows that the majority of tears tend to grow as time passes under this treatment [12,13]. The surgical treatment involves a rehabilitation process, including several weeks of shoulder fixation using a shoulder stabilizer, in order to enable the formation of fibrous tissue between the torn tendon and the bone. Following the surgery, there is a period of several months in which the range of motion is restored and eventually, so are the strength and function of the joint. In the case of massive tears, this process can take up to a year [14,15]. This long process of rehabilitation makes it harder for patients to choose to undergo surgery, especially given that with many tears, the patients do not suffer from any symptoms [3,12]. On the other hand, if the tears are not treated in time, the tear might deteriorate to CTA and destroy the joint, thus causing a substantial impairment to the shoulder function, accompanied by pain. At this point, there is no possibility of tendon repair, and the relevant treatment is the more complex procedure of shoulder arthroplasty [9,5]. Patients undergoing this surgery usually are left with functional restriction in their range of motion, are susceptible to surgery complications, require a long-term follow up, and

sometimes a need for revision surgery [5].

Despite the vast literature regarding the natural history of RCT, little is known about the possibly of developing CTA. Since the diagnosis of CTA is made by radiographic examination, even relatively good shoulder functioning, as can be seen in some of the patients, does not rule out the presence of the arthropathy [16]. In their article, Neer et al. estimated that 4% percent of patients with massive RCT will develop CTA within 8 years of the tear [7]. Hamada et al. have also conducted a follow-up study with 7 patients suffering from tears for 8 years, and found that 5 patents had degenerative changes of the shoulder joint, and of these 5 patients, one (14%) developed CTA. According to these findings, it was hypothesized that CTA results from a deterioration of the joint. As of now, there is no data in current literature regarding the development of CTA longer than 8 years after the RCT. The lack of information concerning the long-term development of CTA creates a situation where neither the patient nor the physician can make an informed decision regarding the best treatment plan for a tear in the shoulder. Thus, the purpose of this study is to examine the long-term clinical natural history of patients with massive RCT and to detect possible risk factors involved in the development of CTA. By being able to predict the likelihood of developing CTA, we can recommend the right treatment for the specific patients at risk of developing it, thereby reducing the chances of developing CTA, on one hand, and preventing unnecessary surgical procedures on the other.

## Materials and Methods

In this case control study, we review over 1,500 shoulders which underwent shoulder US between 1997-2002 in our medical center. Of these, 59 shoulders, belonging to 53 patients were diagnosed with massive RCTs which were not treated surgically. The massive tear was diagnosed by a single senior musculoskeletal radiologist, with over 20 years of experience in performing shoulder US, and a senior orthopedic surgeon in clinical examination. The patients were summoned to the medical center where they underwent True AP shoulder X-Ray, a physical examination of their shoulder motion and filled out the following three questionnaires with the assistance of the study team to clarify the questions and the answers.

1. Demographic questionnaire
2. DASH questionnaire [17] - a subjective questionnaire for evaluating patients' ability to perform daily activities and the severity of shoulder pain while performing these activities. The score ranges from 25 to 100; the higher the score the more severe the shoulder's condition.
3. Constant Murley shoulder outcome score [18]- a semi-objective questionnaire for evaluating the range of shoulder movement as well as estimating the pain. This questionnaire originally consisted of four sub-categories; however, in our research we used only 3 of them, excluding the fourth- pulling force- due to the age heterogeneity of the size of the study sample. These two factors could result in a confounding effect which could obscure the objective condition of the shoulder. Thus, the maximal score is 75, and the higher the score the better the shoulder's condition.
4. True AP shoulder X-Ray for assessing the presence and stage of CTA - the evaluation was conducted separately by two senior orthopedic surgeons with shoulder subspecialty according to Seebauer's criteria [11]. In order to validate their intra-observer reliability, they were assessed twice, in different order of appearance by each specialist. In case of a disagreement, a shared evaluation of the X-rays was conducted. Exclusion criteria to our study consisted of situations that could obscure the clinical damage to the shoulder or the ability of accurate reporting of the shoulder condition, such as: Cerebrovascular Accident (CVA); dementia post-tear surgery, avascular necrosis of the shoulder, previous evidence of CTA, and shoulder fracture.

## Statistical Methods

SPSS 22.0 was used to record and process the data. In order to examine the relationship between two quantitative variables, Pearson's correlation coefficient was calculated. Comparison of a quantitative variable between two independent groups was done using the non-parametric Mann-Whitney test, whereas a comparison of a quantitative variable between 3 groups was performed using the non-parametric Kruskal-Wallis test. The relationship between two categorical variables was examined using the Fischer's exact

test. P value of 0.05 or less was statistically significant. Overall, the following variables were measured and tested for correlation: presence of CTA, CTA staging, age, time elapsed since RCT diagnosis, gender, the dominant hand, functional limitation in daily living, shoulder range of motion, ability of performing everyday activities, and everyday pain.

## Results

Between 1997-2002 more than 1,500 shoulder ultrasounds took place in our medical center. They were reviewed to yield 59 massive rotator cuff tears which were treated conservatively. Out of the 59 shoulders, 7 belonged to patients who passed away, 14 were unavailable or refused to be examined, and 13 met the exclusion criteria, leaving a sample of 25 patients who met the inclusion criteria (Figure 1).

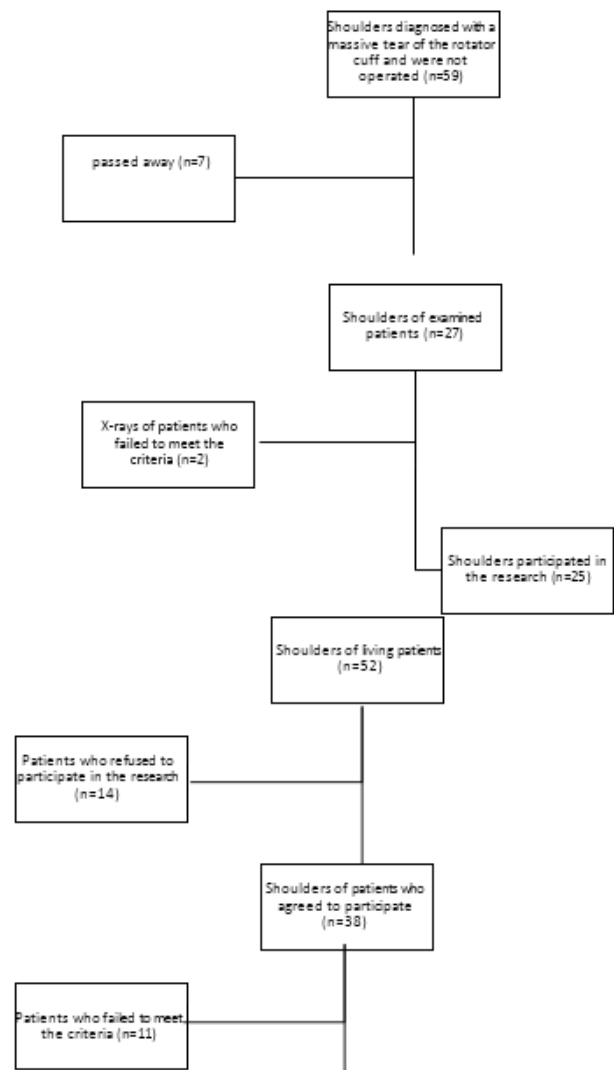


Figure 1: Flow chart of patient inclusion and enrollment with details for those who were excluded.

The study group consisted of 15 females and 10 males. The patient's ages ranged from 59 to 94 years of age, with an average of  $78.6 \pm 10.3$  years. Time elapsed from the RCT to the examination ranged from 12 to 18 years with an average of  $14.9 \pm 1.3$  years. Of the examined shoulder, 19 were right shoulders and 6 were left shoulders. The examined shoulder was of the dominant hand in 20 of the examined shoulders. Only 3 patients showed no signs of arthropathy, thus 22 patients presented symptoms of arthropathy. Furthermore, 13 patients were diagnosed with minimal superior migration with the acetabularization of coracoacromial arch and femoralization of humeral head which correlates with the IA definition of Seebauer's classification, while nine of the examined shoulders showed radiographic evidence of superior migration of the humeral head with insufficient dynamic joint stabilization and superomedial erosion of the glenoid which correlates with the IIA definition of Seebauer's classification. No shoulders were identified with arthropathy that matches IB or IIB Seebauer's classification. The average overall score for Constant Murley questionnaires, from a maximum score of 75, was 38 for shoulders without evidence of arthropathy, 38 for shoulders with IA arthropathy and 22.6 for shoulders with IIA arthropathy. The total score of DASH questionnaires was 44.2 for shoulders with no evidence of arthropathy, 46.3 for shoulders with IA and 52.1 for arthropathy with IIA arthropathy. There was no statistically significant association between the degree of arthropathy and the overall score in the Constant Murley and the DASH questionnaire. A significant correlation ( $r=0.462$   $p \leq 0.054$ ) was found between the time elapsed since the initial diagnosis and the transitioning from arthropathy of IA of Seebauer's classification to arthropathy of IIA of Seebauer's classification.

## Discussion

The purpose of this study was to examine the long-term clinical natural history of patients with massive RCT and to assess the possible risk factors that influence the prevalence of CTA. The most significant finding of this research relates to the long-term influence of massive tears of the rotator cuff. According to our findings, in a long-term follow-up of 15 years on average, 88% of our patients ( $n=17$ ) developed CTA. This finding differs from that of Hamada [19] and confirms the hypothesis concerning the gradual development of the tear until the creation of CTA. In 17 patients, the diagnosed shoulder was the dominant hand. These findings coincide with the conclusions of Jensen, et al. [20] according to which Rotator Cuff Tear arthropathy is more common in the dominant hand. One possible reason for that is that the everyday use of the dominant hand makes it more prone to develop a massive tear of the rotator cuff in comparison to the non-dominant hand, which in turn will develop into arthropathy of the rotator cuff. According to our study there is no sub-population with a reduced risk for developing arthropathy of the rotator cuff in the long run. This data, combined with the rise in average life expectancy and the high prevalence of CTA in our study, means that the chances for developing CTA increases as people with RCT age, and the chances are perhaps as high as 90%.

In light of this process, surgical intervention should be considered in patients with a massive rupture of the rotated cuff and clinical status that correlate with this imaging. The literature shows that patients who underwent surgery to correct the cuff were significantly improved in terms of overall satisfaction with their condition. In particular, a benefit is described in the functional ability to use the shoulder and in pain level over time [21]. Our findings also contradict some of Seebauer's findings according to which, level I of arthropathy includes medial migration of the humeral head while level II includes cephaladic migration, thus these are different types of injuries. According to our data, as time passes, the likelihood to develop level II arthropathy increases, thus these are not necessarily different processes. This finding must be explored in future studies concerning Seebauer's classification. Finally, the study sample included only patients with massive tears of the rotator cuff, thus it may not be relevant for patients with smaller tears. Yet tears have the potential to grow [11,22,23], and so even smaller tears can evolve into massive tears, thus the risk of developing arthropathy also exists in smaller tears, in the long run.

Despite the socio-demographic and clinical heterogeneity of the research sample, all the participants refused to undergo an operation shortly after the tear was diagnosed. So, while there is no demographic factor that differentiates them from the rest of the patients, there is still a risk of selection bias in the research sample. While this study did not address the improvement in patients who underwent a surgical procedure, it does suggest the need to conduct follow-up studies examining the functioning of the patients who underwent such an operation and to compare them with our study. There were hardly significant results, due to the size and the heterogeneous nature of the sample. Thus, it is likely that follow-up studies with larger samples will yield statistically significant findings concerning the measures of functioning and pain levels of arthropathy patients.

## Conclusion

The long-term natural history of massive RCT under non-operative management is not favorable, as regards the possibility of developing CTA. We recommend that patients who suffer from massive RCT and poor functional ability should consider undergo surgery.

## References

1. Ecklund KJ, Lee TQ, Tibone J, Gupta R (2007) Rotator cuff tear arthropathy. *J Am Acad Orthop Surg* 15: 340-349.
2. Williams GR, Rockwood CA, Bigliani LU, Iannotti JP, Stanwood W (2004) Rotator cuff tears: why do we repair them? *J Bone Joint Surg Am* 86: 2764-2776.
3. Yamaguchi K, Tetto AM, Blam O, Evanoff BA, Teefey SA, et al. (2001) Natural history of asymptomatic rotator cuff tears: a longitudinal analysis of asymptomatic tears detected sonographically. *J Shoulder Elbow Surg* 10:199-203.
4. Cofield RH (1982) Subscapular muscle transposition for repair of chronic rotator cuff tears. *Surg, Gynecol Obstet* 154: 667-676.

5. Sanchez-Sotelo J (2011) Total Shoulder Arthroplasty. *Open Orthop J* 5: 106-114.
6. Adams RA (1873) Treatise of rheumatic gout or chronic rheumatoid arthritis of all the joints. Maclachlan & Stewart, Edinburgh 1873: 91-175.
7. Neer CS, Craig EV, Fukuda H (1983) Cuff-tear arthropathy. *J Bone Joint Surg Am* 65: 1232-1244.
8. Smith RW (1853) Observations upon chronic rheumatic arthritis of the shoulder. *The Dublin Quarterly Journal of Medical Science* 15: 343-358.
9. Feeley BT, Gallo RA, Craig EV (2009) Cuff tear arthropathy: Current trends in diagnosis and surgical management. *J Shoulder Elbow Surg* 18: 484-494.
10. Guerra-Soriano F, Ruiz-Suárez M, Encalada-Díaz MI, Pérez-Domech J, Moscona-Mishy L, et al. (2010) The Seebauer classification for the staging of arthropathy due to rotator cuff massive tear: intra- and interobserver concordance analysis. *Acta Ortop Mex* 24: 390-394.
11. Visotsky JL, Bassamania C, Seebauer L, Rockwood CA, Jensen KL (2004) Cuff tear arthropathy: pathogenesis, classification and algorithm for treatment. *J Bone Joint Surg Am* 86: 35-40.
12. Keener JD, Galatz LM, Teefey SA, Middleton WD, Steger-May K, et al. (2015) A prospective evaluation of survivorship of asymptomatic degenerative rotator cuff tears. *J of Bone Joint Surg Am* 21: 89-98.
13. Maman E, Harris C, White L, Tomlinson G, Shashank M, et al. (2009) Outcome of nonoperative treatment of symptomatic rotator cuff tears monitored by magnetic resonance imaging. *J Bone Joint Surg Am* 91:1898-1906.
14. Charoussat C, Grimberg J, Duranthon LD, Bellai"che L, Petrover D, et al. (2008) The time for functional recovery after arthroscopic rotator cuff repair: correlation with tendon healing controlled by computed tomography arthrography. *Arthroscopy* 24: 25-33.
15. Louis U, Bigliani LU, Cordasco FA, McIlveen SJ, Musso ES (1992) Operative repair of massive rotator cuff tears: Long-term results. *J Shoulder Elbow Surg* 1: 120-130.
16. Middernacht B, Winnock de Grave P, Van Maele G, Favard L, Molé D, et al. (2011) What do standard radiography and clinical examination tell about the shoulder with cuff tear arthropathy? *J Orthop Surg Res* 6: 1.
17. Hudak PL, Amadio PC, Bombardier C (1996) Development of an upper extremity outcome measure: the DASH (disabilities of the arm, shoulder and hand). The Upper Extremity Collaborative Group (UECG). *Am J Ind Me* 29: 602-608.
18. Constant CR and Murley AH (1987) A clinical method of functional assessment of the shoulder. *Clin Orthop Relat Res* 214: 160-164.
19. Hamada K, Fukuda H, Mikasa M, Kobayashi Y (1990) Roentgenographic findings in massive rotator cuff tears. A long-term observation. *Clin Orthop Relat Res* 254: 92-96.
20. Jensen KL, Williams GR, Russell IJ, Rockwood CA (1999) Current concepts review - rotator cuff tear arthropathy *J Bone Joint Surg Am* 81: 1312-1324.
21. Nho SJ, Yadav H, Shindle MK, Macgillivray JD (2008) Rotator cuff degeneration: etiology and pathogenesis. *Am J Sports Med* 36: 987-993.
22. Iannotti JP, McCarron J, Raymond CJ, Ricchetti ET, Abboud JA, et al. (2010) Agreement study of radiographic classification of rotator cuff tear arthropathy. *J Shoulder Elbow Surg* 19: 1243-1249.
23. Park JG, Cho NS, Song JH, Baek JH, Rhee YG (2016) Long-term outcome of tuberoplasty for irreparable massive rotator cuff tears: is tuberoplasty really applicable? *J Shoulder Elbow Surg* 25: 224-231.