

Case Report

A Series of 3 Cases of *Streptococcus pneumoniae* Pneumonia in 3 Foreign Shipyard Workers

Lee Eng Kiang*

Department of Anaesthesia, Ng Teng Fong General Hospital, 1 Jurong East Street 21, Singapore

*Corresponding author: Lee Eng Kiang, Senior Consultant, Intensive Care Medicine, Ng Teng Fong General Hospital, 1 Jurong East Street 21, Singapore. Tel: + 6567724208; +6567162000; Email: eng_kiang_lee@nuhs.edu.sg

Citation: Kiang LE (2018) A Series of 3 Cases of *Streptococcus pneumoniae* Pneumonia in 3 Foreign Shipyard Workers. Ann Case Rep: ACRT-156. DOI: 10.29011/2574-7754/100056

Received Date: 27 December, 2017; **Accepted Date:** 12 January, 2018; **Published Date:** 22 January, 2018

Summary

We are reporting a series of 3 cases of foreign shipyard workers who have been in Singapore for less than a year and presented with similar clinical features of pneumonia from *Streptococcus pneumoniae*. These patients came in within a span of 3 months from April to June and all 3 were referred early by General Practitioners (GP). Despite the recent advances in antibiotic therapy and ventilating equipment, community acquired pneumonia remains a common cause for hospitalization and intubation for type one respiratory failure. A study done in 1993 by Hui [1] in National University Hospital of Singapore reported an incidence 12 % of *Streptococcus pneumoniae* for non-tuberculous pneumonia.

Two of the three patients had positive blood cultures from Streptococcal pneumonia and one had positive urine Streptococcal antigen tests. All 3 presented with hypotension and hypoxia on arrival in the Emergency Department(ED) and despite fluid resuscitation and oxygen therapy, 2 of them ended up with severe hypoxia requiring intubation. All 3 ended up with norepinephrine inotropic infusion for at least 24 hours. All three patients responded to treatment and recovered fully. They were all subsequently discharged from the hospital.

There is a postulation that Pneumococcal vaccine could have prevented the infection and the subsequent complication related to the infection in these foreign shipyard workers though there is not enough data to suggest so. The current data is based on studies in young children and elderly patients [2,3].

Introduction

Community acquired pneumonia remains in Singapore a common cause for hospital admission. Despite the presence of potent antibiotics over the last 2 to 3 decades, significant morbidity and mortality are still associated with community acquired pneumonia requiring hospitalization and Intensive Care (ICU) admission. In 1993, a study on the local pattern of pathogens was done by Hui [1] and Streptococcal pneumoniae accounted for 12 % of non-tuberculous pneumonia. In Singapore as reported by Low [2,3] in 2007 that the mean annual hospitalization rate for pneumococcal disease was 10.9 per 100,000 population from 1995 to 2004. The mean rate was highest in the young and the elderly.

We are reporting a series of 3 foreign shipyard workers who presented with pneumococcal pneumonia over a period of 3 months from April to June this year. 2 of them required intubation and one

of the two ended up with Adult Respiratory Distress Syndrome (ARDS) and infective endocarditis. The third patient only required non-invasive ventilator support and inotropic infusion for less than 24 hours. All three patients recovered fully and were successfully discharged from the hospital.

Report

The first patient is a 41-year-old Bangladeshi shipyard worker who has been working in Singapore for eight months. He has no significant medical condition except for a short period of childhood asthma. He had been coughing for 3 days and was progressively getting worse with fever, chills and rigor and purulent sputum. He also complained of severe pleuritic pain on the left chest wall. He was seen by a general practitioner who referred him to the Emergency Department(ED). He was hypotensive, tachycardic and tachypneic on arrival at the ED. The first chest X-ray showed a significant left

upper lobe consolidation. Figure 1. He was also neutropenic with a white cell count of less than $0.5 \times 10^9/l$. CRP was 457.3 mg/L. He was resuscitated aggressively with a total of 7 litres of crystalloid and intravenous peripheral dopamine was started while waiting for transfer to the ICU. His systolic blood pressure was perpetually below 80 mmHg and diastolic was below 40 mmHg. He also became progressively more hypoxic requiring intubation before he could be transferred to the ICU. He was started on intravenous amoxicillin-clavulanate, ceftazidime and azithromycin and was on high dose noradrenaline infusion. He also required very high ventilatory support over the next 3 days and blood culture came back positive with multi-sensitive *Streptococcal pneumoniae* in both aerobic and anaerobic bottles within 24 hours. Despite intravenous antibiotics, the patient deteriorated and developed a pneumothorax and big pleural effusion requiring a chest tube into the right pleural space. He also developed ARDS and was changed to high frequency oscillation ventilation. Despite this, His saturation continued to deteriorate. After consultation with the cardiothoracic surgeon, an extracorporeal membrane oxygenation device was inserted to enhance his oxygenation. He was transferred to another hospital for further management and was subsequently found to have infective vegetation in his mitral valve. He received a mitral prosthetic valve after he recovered from his ARDS and was discharged back home to Bangladesh.

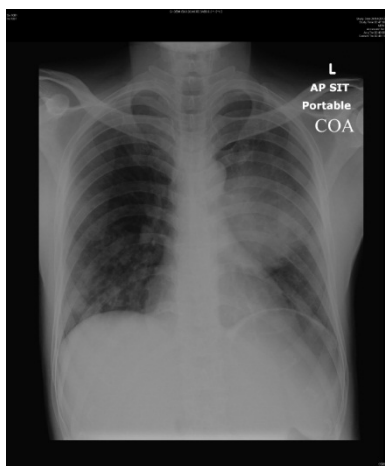

Figure 1: Chest X-ray showed a significant left upper lobe consolidation.

The second patient is a 24-year-old Indian shipyard worker who has been in Singapore for less than eight months. He presented to the ED with a referral from the GP for a history of 6 days of fever, coughing with purulent sputum and right sided pleuritic pain. A chest X-ray taken at the GP also showed a right upper lobe consolidation. Figure 2. He was tachycardic with a heart rate above 130 per minute and persistent low systolic pressure below 80 mmHg despite given a total of 5 litres of crystalloid. He was also hypoxic with a saturation of less than 90% despite on 100% non-rebreathing mask. He was intubated before he was sent the

ICU with intravenous amoxicillin-clavulanate, ceftazidime and azithromycin. The blood culture came back within 12 hours showing multi-sensitive *Streptococcal pneumoniae*. Unlike our first patient, the intravenous amoxicillin-clavulanate was double in dose to 2.4g tds on arrival in the ICU. His ventilatory requirement came down very rapidly within 24 hours and his noradrenaline infusion was also stopped. He was extubated the next day and was discharged to the general ward with resolution of his fever and tachycardia and tachypnea. He was discharged back to his dormitory after staying 5 days in the hospital with no subsequent complication.

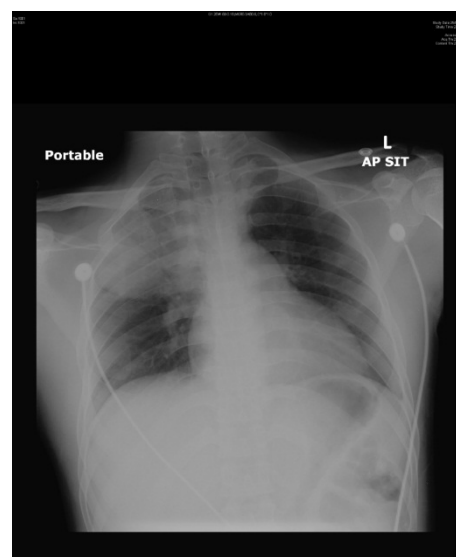


Figure 2: Chest X-ray taken at the GP also showed a right upper lobe consolidation.

The third patient is a 20-year-old Indian shipyard worker who had been working in Singapore for less than 3 months. He presented to the ED after he was seen by his GP. He had a 10-day history of fever, chills and rigor and coughing out purulent sputum. Similarly, he also had significant right side pleuritic pain. His systolic blood pressure was below 100 mmHg and heart rate was about 120 to 130 per minute. A chest X-ray showed a right lower lobe consolidation. Figure 3. He was given 1.5 litres of crystalloid and was started on intravenous dopamine before he was sent to the ICU on 100% non - rebreathing mask. A central line was inserted in the ICU before noradrenaline was started and the dosing of intravenous amoxicillin - clavulanate was double to 2.4g tds. He was also placed on non-invasive ventilator support and within 6 hours of therapy, he was weaned down to facemask and down to nasal prong after spending 8 hours in the ICU. The inotropic infusion was also stopped after about 6 hours. Blood culture test was negative but the urine test on *Streptococcal antigen* came back positive within 3 hours. The patient was discharged to the general ward the next day and was discharged to his dormitory after 3 days in the hospital.

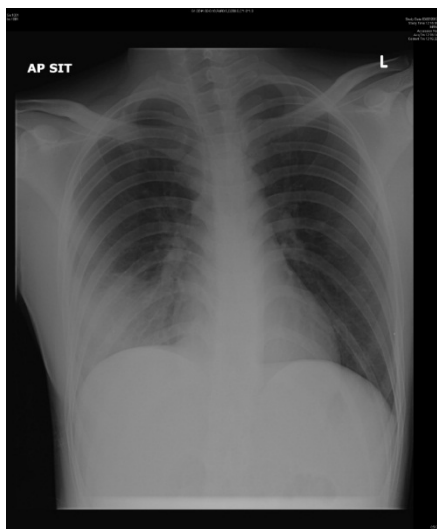


Figure 3: Chest X-ray showed a right lower lobe consolidation.

Conclusion and Discussion

All 3 patients presented with similar clinical pictures and were critically ill on arrival at the ED. The first patient had significant morbidity and almost demised from his complications related to Streptococcal infection and incurred a significant medical bill. All these patients were reviewed by GPs and were referred quickly to the hospital for further management.

The above cases showed that pneumococcal infection is an important cause of mortality and morbidity. This is an infection that can cause a wide spectrum of illness and disease and as evidence by the development of ARDS and infective endocarditis in our first patient. However, like many other developed countries, the burden of *Streptococcus pneumoniae* is still greatest at the extreme of ages and mortality is highest with the elderly and young children.

Since the introduction of the 23-valent polysaccharide pneumococcal vaccine, Pneumovax 23 and Pneumo 23 In 1988 and 1998 respectively, there has been a downward trend in the annual hospitalization rates for pneumococcal disease from 2000 onwards, and most notably among elderly adults 75 years and above. The introduction of another new vaccine, PCV7 in 2002 also resulted in a significant decline in the annual hospitalization of the young and elderly patients [2,3].

We were surprised by the span of presentation of these workers over a short period of time. They are young healthy males

who developed severe morbidity from pneumococcal infection. The common factors among the three patients were the fact that they were foreigners who had been in Singapore for less than a year and may be exposed to the same unknown factor in their working environment. We were unable to analyze the serotypes of the Streptococcal pneumoniae of these 3 patients and it could have been helpful in determining if they belong to the more invasive strains that are present in Singapore.

At this moment pneumococcal vaccine is only recommended for young children and elderly people and also those who have splenectomy. In a recent review of pneumococcal vaccine in a tertiary hospital in Singapore by Hsu [3,4], the use of Pneumococcal Polysaccharide vaccine (PPV23) can be used to cover 82.8% of the isolates in Singapore. At this moment there is no recommendation for foreign workers to have pneumococcal vaccines as there are no relevant studies to support its usage. As there are more 90 over serotypes of pneumococcal bacteria, we are not sure that the existing data of the resistant strain pattern in paediatric patient [5] can be extrapolated to foreigners working in Singapore. As such, we can only consider recommending it to these shipyard workers on an ad hoc basis. A study on the cost-effectiveness of pneumococcal vaccination might be useful for evaluating the potential benefits of vaccination for these foreign workers. A detailed study of the working environment may be also useful in determining what is the common factor involved.

References

1. Hui KP, Chin NK, Chow K, Brownlee A, Yeo TC, et al. (1993) Prospective Study of the Aetiology of Adult Community Acquired Bacterial Pneumonia needing hospitalisation in Singapore. Singapore Med J 34: 329-334.
2. Low S, Chan FL, Cutter J, Ma S, Goh KT, et al. (2007) A National Study of the Epidemiology of Pneumococcal disease among hospitalized patients in Singapore: 1995 to 2004. Singapore Med J 48: 824-829.
3. Hsu LY, Lui SW, Lee JL, Hedzlyn HM, Kong DH, et al. (2009) Adult Invasive Pneumococcal Disease pre-and peri-pneumococcal conjugate vaccine introduction in a tertiary hospital in Singapore. J of Med Microbiol 58: 101-104.
4. Yew WS (2010) Pneumococcal Vaccination in Adults. The Singapore Family Physician 36: 22-25.
5. Soh SWL, Poh CL, Lin RVTP (2000) Serotype Distribution and Antimicrobial Resistance of isolates in *Streptococcus pneumoniae* Paediatric patients in Singapore. Antimicrobial Agents and Chemotherapy 44: 2193-2196.