

Current Trends in Ophthalmology and Visual Science

Siegel D, et al. Curr Trends Ophthalmol and Vis Sci: CTOVS-102.

DOI: 10.29011/CTOVS-102/100002

Research Article

MicroPulse Diode Transscleral Cyclophotocoagulation Lowers Intraocular Pressure in Advanced Glaucoma

Dana Siegel^{1*}, Marc J. Siegel², Michael J. Siegel²¹Wayne State University School of Medicine, Detroit, MI, USA²The Glaucoma Center of Michigan, Southfield, MI, USA

*Corresponding author: Dana Siegel, Wayne State University School of Medicine, Detroit, MI, USA. Tel: +12487987587; Email: dsiegel@med.wayne.edu

Citation: Siegel D, Siegel MJ, Siegel MJ (2018) MicroPulse Diode Transscleral Cyclophotocoagulation Lowers Intraocular Pressure in Advanced Glaucoma. Curr Trends Ophthalmol and Vis Sci: CTOVS-102. DOI: 10.29011/CTOVS-102/100002

Received Date: 17 March, 2018; **Accepted Date:** 09 April, 2018; **Published Date:** 16 April, 2018

Abstract

Background: Glaucoma is a leading cause of irreversible blindness. MicroPulse diode laser (MP3) transcleral cyclophotocoagulation is an innovative cycloablative technique used to lower intraocular pressure (IOP). The objective of this study was to evaluate the effectiveness of MP3 in controlling the IOP while avoiding more invasive surgery and complications in the management of advanced glaucoma.

Methods: This was a retrospective study performed in the metro Detroit area. The records of 100 eyes with advanced glaucoma that underwent MP3 were reviewed. The MicroPulse P3 hand-piece was used with the Cyclo G6 laser device. The MP3 settings were largely derived from the pilot study. Main measures included pre and post-procedure IOP, number of glaucoma medications and visual acuity, as well as additional surgeries or complications. Full success (definition A) and qualified success (definition B) were defined and calculated. Paired t-tests were used to determine significance with $p < 0.05$.

Results: The mean IOP at 6 months post-treatment was statistically lower than the pre-treatment IOP ($P < 0.01$). The success rate for definition A was 25% and 44% for definition B. Twelve eyes required more invasive surgery. The average number of glaucoma medications increased from 2.9 to 3.0. The visual acuity had no significant change. No serious complications were observed.

Conclusions: MP3 is a safe and effective procedure for lowering the IOP in advanced glaucoma while avoiding more invasive surgeries. It does not, however, appear to have any effect neither on reducing the number of ocular medications nor on improving the visual acuity.

Keywords: Ciliary body; Glaucoma; Intraocular pressure; CAG : Closed angle glaucoma
Laser surgery; New treatments; Photocoagulation

Abbreviations

MP3	:	MicroPulse
TS-CPC	:	Diode laser transcleral cyclophotocoagulation
IOP	:	Intraocular pressure
CPC	:	Cyclophotocoagulation
OAG	:	Open angle glaucoma

Introduction

Glaucoma continues to be a leading cause of irreversible blindness worldwide. The prevalence of glaucoma in 2013 was estimated to be 64.3 million with projected increases of up to 76.0 million in 2020 [1]. Current therapies to help prevent progression of blindness include topical medications, lasers, and incisional surgery. These therapies are designed to lower the Intraocular Pressure (IOP) by reducing aqueous production, increasing aqueous outflow, or both. Reducing the IOP has been proven to

help decrease damage to the optic nerve and thus preserve visual function [2,3].

A common modality used in refractory glaucoma involves transscleral ciliary body ablation. This cycloablative technique targets the aqueous-producing ciliary body epithelium and stroma in order to decrease the production of aqueous humor. Although traditional external cycloablative procedures such as cryotherapy and continuous laser Transscleral Cyclophotocoagulation (TS-CPC) are able to effectively reduce the IOP in advanced glaucoma, the risk for significant side effects including permanent vision loss make their use confined to poor visual potential eyes only [4,5].

Recently, a promising new technique utilizing a “micropulsed” transscleral diode laser (MP3) was developed in order to decrease the incidence of vision-threatening complications while maintaining the aqueous humor reduction capabilities. MP3 differs from the conventional laser in that it delivers repetitive low-energy pulses of diode laser separated by brief rest periods as opposed to a continuous laser wave. The break in pulses allows time for the cells in the ciliary body to return to their baseline temperature, decrease the build-up of thermal energy, and remain below its coagulation threshold [6]. This has been proven in multiple clinical trials to have a statistically significant effect on the avoidance of collateral damage, cellular destruction, inflammation, and scarring, as well as improved patient comfort [7,8]. The objective of this present retrospective study was to evaluate the effectiveness of MP3 in controlling the IOP, reducing the medication burden, and avoiding more invasive surgery in the management of advanced glaucoma while preventing serious ocular complications.

Materials and Methods

The study design was a retrospective chart review performed at a glaucoma sub-specialty private practice in the metropolitan Detroit area. The MP3 lasers were performed at an Ambulatory Surgery Center. The study was reviewed and approved by the institutional review board of the affiliated hospital. The review examined 86 consecutive patients (100 eyes) between September 2016 and January 2017 with full demographic data visualized in (Table 1). All four surgeons performing the MicroPulse Diode Cyclophotocoagulation (MP3) are board-certified by the American Board of Ophthalmology as well as glaucoma fellowship trained.

Consecutive patients were included in the study if they met the following criteria: 1) Received the MP3 between September 2016 and January 2017; 2) A history of advanced primary open angle glaucoma, closed angle glaucoma, or other glaucoma (neovascular, residual stage, steroid-induced, normal tension, juvenile); and 3) Had a minimum of a 6-month follow-up. Patients were excluded from the study if they had preoperative IOP <5 or >50. Preoperative data collected for each patient included age, gender, race/ethnicity, glaucoma diagnosis, IOP, number of ocular

anti-hypertensive medications, cup to disc ratio, and best-corrected visual acuity.

The laser used to perform all procedures was the FDA-approved Cyclo G6 diode laser device (IRIDEX Corporation, Mountain View, CA, USA) with the single-use MicroPulse P3 hand-piece. Prior to the procedure, patients received a peribulbar block of a 10cc mixture of hyaluronidase and 2% lidocaine to the treatment eye. The MP3 laser settings used across all patients were as follows: 2000 mW of 810nm of infrared radiation, 0.5 ms micropulse “ON”, 1.1 ms micropulse “OFF” and 31.3% duty cycle. With these settings, the MP3 probe was glided with firm pressure directly across the upper hemisphere of the affected eye 1.5 mm posterior to the limbus from the 9:30 to 2:30 clock position in 10-second continuous sweeps for 80 seconds. These 10-second sweeps were then repeated across the lower hemisphere for 80 seconds from the 3:30 to 8:30 clock position for a total treatment time of 160 seconds. Any areas of prior filtering surgery were avoided. Patients received a post-operative dose of neomycin polymyxin dexamethasone ointment and were patched for 4 hours. All patients were started on topical prednisolone acetate 1% QID but were tapered postoperatively based upon the clinician’s judgment.

Main outcomes measures included post-intervention IOP at 1, 3, and 6 months, ocular anti-hypertensive medication changes at 6 months, visual acuity at 6 months, complications, and the need for any additional surgery within the 6-month timeframe. Full success was defined as a minimum of 20% reduction of IOP, a decrease in at least one ocular anti-hypertensive medication, no decrease in visual acuity, no complications, and no additional surgeries (definition A). Qualified success was defined as an IOP lower than preoperative, no increase in the number of ocular anti-hypertensive medications, no complications, and no additional surgeries (definition B). Failure was defined as any need for additional surgical interventions (including repeat MP3 treatment), an increase in IOP at 6 months, any complications, or an increase in ocular anti-hypertensive medications. The success rate of MP3 was analyzed by the Kaplan-Meier survival analysis curves. The change in IOP, ocular anti-hypertensive medications, and visual acuity after laser treatment was analyzed by paired t-test. Clinical significance was set at $p < 0.05$.

Results

This study reviewed 100 eyes in 86 patients with a mean age of 73.5 years (standard deviation [SD]=12.4 years) and a roughly equal number of males and females (41 male, 45 female). Full patient demographics are summarized in (Table 1). The mean \pm SD baseline preoperative IOP was 23.19 ± 8.18 (range 10 to 49) and the mean number of glaucoma medications 2.93 ± 1.23 (range 0 to 6). The mean preoperative LogMAR visual acuity was -1.22 ± 1.18 (range -4.7 to 0) and the mean cup-to-disc ratio was 0.89 ± 0.17 (range 0.1 to 1). Patients received the MP3 laser treatment if

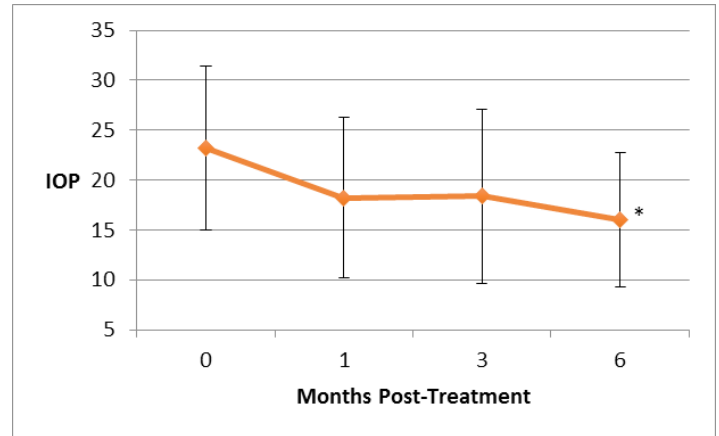
they had poorly controlled glaucoma as evidenced by elevated IOP and/or a maximally tolerated medication burden.

Of the 100 eyes reviewed during the 6-month follow-up timeframe, 32 needed additional interventions in order to control the IOP. Procedures performed included repeat MP3 (20 eyes), trabeculectomy (4 eyes), shunt procedures (4 eyes), and goniotomy (4 eyes). All of these eyes were defined as failures and were not included in the 6-month post-operative IOP and medication reduction data analysis.

Age (years):	73.54 ± 12.42
Sex:	
Male	41 (48%)
Female	45 (52%)
Eye:	
OD	47
OS	53
Race:	
Caucasian	36 (42%)
African-American	34 (40%)
Other	16 (18%)
Glaucoma diagnosis:	
OAG	77 (77%)
CAG	9 (9%)
Other	14 (14%)
Preoperative medications (Mean ± SD)	2.93 ± 1.23
Preoperative IOP (Mean ± SD)	23.19 ± 8.18
Preoperative logmar vision (Mean ± SD)	-1.22 ± 1.18
Preoperative cup:disc (Mean ± SD)	0.89 ± 0.17
OD, right eye; OS, left eye; OAG, open angle glaucoma; CAG, closed angle glaucoma; Other, neovascular, residual stage, steroid-induced, normal tension or juvenile glaucoma	

Table 1: Baseline demographic characteristics of all patients reviewed.

Overall changes in IOP after MP3 TS-CPC are shown in (Figure 1). The mean ± SD IOP at 1-month post-treatment decreased from 23.19 ± 8.18 mmHg (range 10-49) to 18.21 ± 8.06 mmHg (range 5-42 mmHg), 18.38 ± 8.72 mmHg at 3 months post-treatment (range 6-48 mmHg), and 16.04 ± 6.74 mmHg at 6 months post-treatment (range 2-36 mmHg). The mean IOP at 6 months post-treatment was statistically lower than the pre-treatment IOP (P < 0.01, paired t-test) (Table 2). One eye was excluded from the study as it had a pre-operative IOP of 68.



IOP=intraocular pressure.

*=P<0.01 based on paired T-test

Figure 1: Changes in intraocular pressure (mmHg) after MicroPulse diode laser ± SD.

The mean ± SD number of anti-hypertensive glaucoma medications pre-operatively was 2.90 ± 1.23 (range 0 to 6), while the average number of medications at 6 months postoperative was 3.03 ± 1.27 (range 0-5). 56.2% (41) of patients used the same number of medications as baseline, 12.3% (9) decreased their number of medications by 1, 4.1% (3) decreased by 2, and 1.37% (1) decreased by 3 or more. 19.2% (14) increased their number of medications by 1, 4.1% (3) increased by 2, and 1.37% (1) increased by 3 or more. There was no statistically significant change (Figure 2 & Table 2). The pre-treatment visual acuity ranged from no light perception to 20/20 with an unchanged post-treatment visual acuity range. Two patients had a clinically significant decline in their acuity at 6 months post-treatment (defined as >2 lines of vision), with one related to macular edema and the other caused by decomposition of previous corneal edema. There were also three patients who had a significant improvement in their acuity at 6 months post-treatment; these were secondary to improvement in macular edema (1 patient), improvement in IOP and glaucoma control (1 patient), and a new corneal transplant (1 patient). There was no statistically significant difference in the average acuity pre and post-treatment (Table 2). A Kaplan-Meier analysis of the study is presented in (Figures 3 & 4). According to definition A, life-table analysis showed an overall success rate of 25% at 6 months post-treatment. According to definition B, the overall success rate was 44% at 6 months post-treatment. The success rate of definition A dropped off at 6 months mostly due to repeat laser or more surgery (32%); in addition, 14% did not meet the

IOP reduction requirement, 7% did not decrease their number of glaucoma medications, and 17% did not meet the IOP nor medication reduction requirements. Definition B also had a decline in success rate at 6 months mostly because of repeat laser or more surgery (32%). The main difference in success rate between the two curves was due to the IOP reduction cutoff; 13 patients had IOP reductions between 1 and 20%.

There were no serious adverse effects encountered in this study. No patient developed pressure spikes, hyphema, scleral thinning or phthisis bulbi. The one patient with a post-operative IOP of 2 mmHg tolerated this low pressure with no problem. No patient reported pain levels greater than “mild”.

	Baseline	6 months
Intraocular pressure	23.19 ± 8.18 (range 10-49)	16.04 ± 6.74 (range 2-36 mmHg)*
Average number of glaucoma medications	2.93 ± 1.23 (range 0 to 6)	3.03 ± 1.27 (range 0-5)
Visual Acuity	-1.22 ± 1.18 (range -4.7 to 0)	-1.25 ± 1.22 (range -4.7 to 0.30)
*= $P < 0.01$ based on paired T-test		

Table 2: Change in the intraocular pressure (mmHg), number of glaucoma medications and LogMAR visual acuity at 6 months post-treatment ± SD.

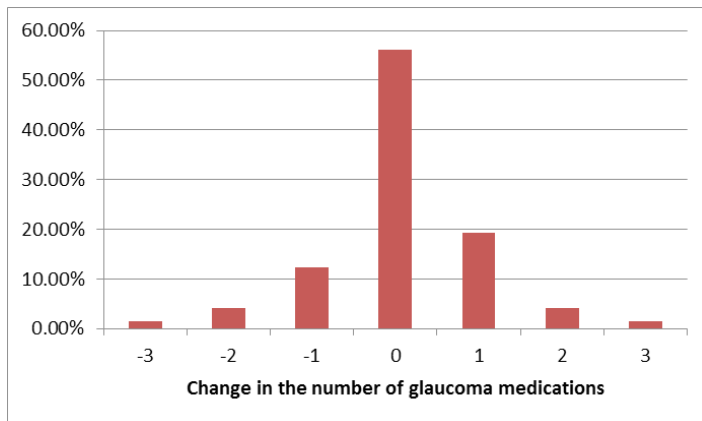


Figure 2: Percent of patients with the corresponding change in the number of anti-hypertensive glaucoma medications at 6 months post-treatment.

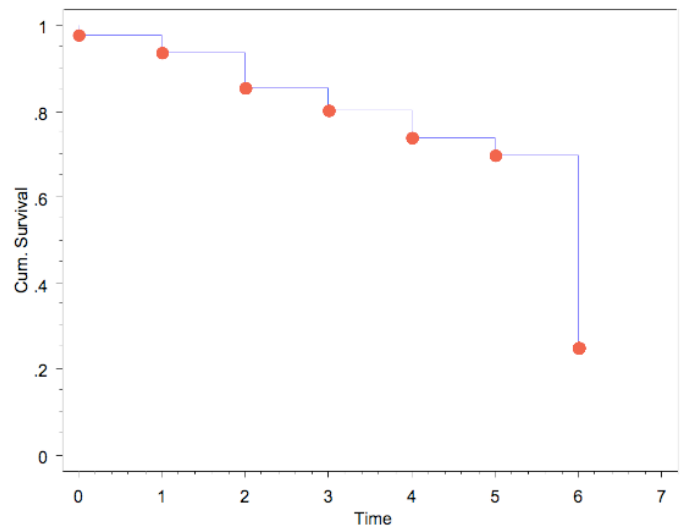


Figure 3: Kaplan-Meier Cumulative Survival for definition A†. †: Definition A=A minimum of 20% reduction of IOP, a decrease in at least one ocular anti-hypertensive medication, no decrease in visual acuity, no complications, and no additional surgeries.

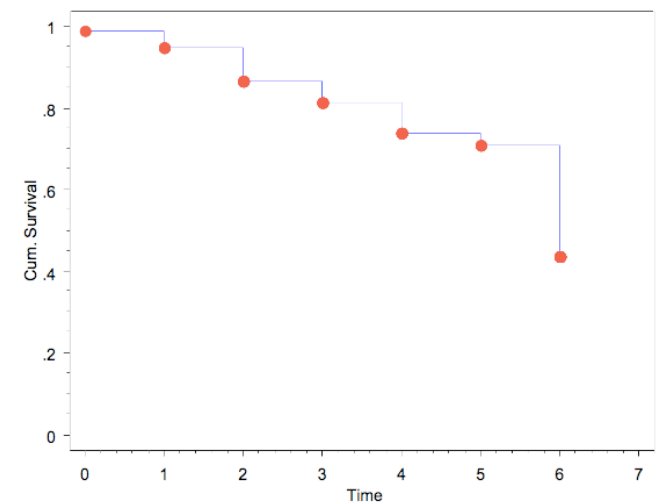


Figure 4: Kaplan-Meier Cumulative Survival for definition B†. †: Definition B=IOP lower than preoperative, no increase in the number of ocular anti-hypertensive medications, no complications, and no additional surgeries.

Discussion

Ablation or shrinkage of the ciliary body in order to decrease the production of aqueous humor secretion and thus lower the IOP has been used for decades in the treatment of refractory glaucoma [9]. Several modalities have been used to achieve cyclodestruction but Cyclophotocoagulation (CPC) has become the most commonly used procedure. Traditional Contact Transscleral CPC (TS-CPC) using continuous mode is effective in reducing aqueous humor secretion but is often used as a last resort due to the risk of serious adverse effects and the unpredictability of effect [4]. On the other hand, delivering the laser emission in a train of shorter pulses with adjustable “ON” and “OFF” time via the MicroPulse (MP3) laser has shown to cause less inflammation, less pain, and a lower risk of vision loss [4,6,10]. Patients were selected for MP3 TS-CPC if they had a history of advanced glaucoma on maximal tolerated medical therapy, failed conventional medical treatment and/or failed office-based laser trabeculoplasty procedures. Furthermore, these patients often had multiple co-morbidities including older age, which made MP3 a safer alternative to the more invasive surgeries. The safety benefits of MP3 include minimal to no inflammation post-treatment, a significantly low downtime, a non-incisional technique, and repeatability [11]. The patients included in this study had no serious adverse effects and had a statistically significant decrease in IOP ($p < 0.01$), with 88% of patients able to avoid more invasive surgeries and their associated complications. Repeat laser to further decrease the IOP, however, was performed in 20% of patients. Because the MP3 technique creates a non-lethal thermal insult, the cells of the ciliary epithelium are able to regenerate, and thus multiple treatments are sometimes necessary in order to achieve the desired long-term IOP-lowering effect. A prospective study by Ocakoglu et al. reported that 44% of patients required more than one MP3 treatment in order to control the IOP [12]. This present study has several strengths. Firstly, there was no selection bias in the study aside from excluding one patient with a pre-treatment IOP > 50 . Thus, almost all consecutive patients receiving the MP3 laser during the designated timeframe regardless of age, gender, race, or glaucoma diagnosis were included. The study also had an excellent and complete data collection, as only two patients out of 100 were lost to follow-up throughout the 6-month timeframe. The main weakness of this study is that the follow-up data collection was only until 6 months post-treatment. Therefore, longer follow-up in the future is required to determine the longevity of the treatment and/or any occurrence of late complications. As MP3 laser becomes more utilized as a treatment modality, changes to treatment protocols (in relation to power, duration of treatment and/or method of treatment) may be helpful in determining improved efficacy while maintaining a similar safety profile from the current studied protocols. Moving forward, further prospective data is needed to better validate the MP3 laser and its role in glaucoma surgical management.

Conclusion

Although MP3 TS-CPC was associated with a significant reduction in IOP and avoidance of more invasive surgeries, it did not appear to have any effect on reducing the number of anti-hypertensive ocular medications nor on improving the visual acuity. Overall, the authors view this study as a success as the goal of the procedure was to better control the IOP via a non-invasive technique to hopefully prevent further progression of the disease.

References

1. Tham YC, Li X, Wong TY, Quigley HA, Aung T, et al. (2014) Global prevalence of glaucoma and projections of glaucoma burden through 2040: a systematic review and meta-analysis. *Ophthalmology* 121: 2081-2090.
2. Heijl A, Leske MC, Bengtsson B, Hyman L, Hussein M, et al (2002) Reduction of intraocular pressure and glaucoma progression: results from the Early Manifest Glaucoma Trial. *Arch Ophthalmol* 120: 1268-1279.
3. The Advanced Glaucoma Intervention Study (AGIS) (2000) The relationship between control of intraocular pressure and visual field deterioration. The AGIS Investigators. *Am J Ophthalmol* 130: 429-440.
4. Aquino MC, Barton K, Tan AM, Sng C, Li X, et al. (2015) Micropulse versus continuous wave transscleral diode cyclophotocoagulation in refractory glaucoma: a randomized exploratory study. *Clin Exp Ophthalmol* 43: 40-46.
5. Meyer JJ, Lawrence SD (2012) What's new in laser treatment for glaucoma? *Curr Opin Ophthalmol* 23: 111-117.
6. Tan AM, Chockalingam M, Aquino MC, Lim ZI, See JL, et al. (2010) Micropulse transscleral diode laser cyclophotocoagulation in the treatment of refractory glaucoma. *Clin Exp Ophthalmol* 38: 266-272.
7. Lee JW, Yau GS, Yick DW, Yuen CY (2015) MicroPulse Laser Trabeculoplasty for the Treatment of Open-Angle Glaucoma. *Medicine (Baltimore)* 94: e2075.
8. Rantala E, Välimäki J (2012) Micropulse diode laser trabeculoplasty -- 180-degree treatment. *Acta Ophthalmol* 90: 441-444.
9. Feldman RM, el-Harazi SM, LoRusso FJ, McCash C, Lloyd WC, et al. (1997) Histopathologic findings following contact transscleral semiconductor diode laser cyclophotocoagulation in a human eye. *J Glaucoma* 6: 139-140.
10. Mistlberger A, Liebmann JM, Tschiderer H, Ritch R, Ruckhofer J, et al. (2001) Diode laser transscleral cyclophotocoagulation for refractory glaucoma. *J Glaucoma* 10: 288-293.
11. Tsang S, Cheng J, Lee JW (2016) Developments in laser trabeculoplasty. *Br J Ophthalmol* 100: 94-97.
12. Ocakoglu O, Arslan OS, Kayiran A (2005) Diode laser transscleral cyclophotocoagulation for the treatment of refractory glaucoma after penetrating keratoplasty. *Curr Eye Res* 30: 569-574.