

Mesenteric Revascularisation By Carrel Patch Technique in Abdominal Aortic Aneurysmectomy

Ruşen Melih Nebigil^{1*}, Metin Yalaza²

¹Department of Cardiovascular Surgery, Ankara Numune Training and Research Hospital, Ankara, Turkey

²Department of General Surgery, Ankara Numune Training and Research Hospital, Ankara, Turkey

***Corresponding author:** Ruşen Melih Nebigil, Department of Cardiovascular Surgery, Ankara Numune Training and Research Hospital, Hacettepe, Talatpaşa Blv No:44, 06230 Altındağ/Ankara, Turkey. Tel: +905055221128; Email: nebigilm@gmail.com

Citation: Nebigil RM, Yalaza M (2018) Mesenteric Revascularisation By Carrel Patch Technique in Abdominal Aortic Aneurysmectomy. J Surg: JSUR-1106. DOI: 10.29011/2575-9760.001106

Received Date: 07 February, 2018; **Accepted Date:** 17 February, 2018; **Published Date:** 26 February, 2018

Abstract

Mesenteric circulation is strongly related to postoperative mortality in Abdominal Aortic Aneurysms (AAA). Postoperative mortality is higher in patients with neglected mesenteric revascularization. In this report, we describe the surgical repair of an infrarenal AAA with reimplantation of the Inferior Mesenteric Artery (IMA) by using the Carrel patch technique.

Introduction

Complications of aortic grafts are hemorrhage, graft occlusion, embolization, infection, ureteral injury, ischemic colitis, spinal ischemia, pseudoaneurysm, material failure and sexual dysfunction. Ischemic colitis remains a rare entity after elective open abdominal aortic aneurysm repair with a reported incidence ranging from 1% to 3% [1]. When routine postoperative colonoscopy is performed, the incidence reaches 5% to 9% after elective surgery and 15% to 60% following rupture [2,3]. Colonic ischemia following aortic reconstruction is multifactorial, depending on the caliber of the occluded vessel, the duration and the degree of ischemia, the rapidity of onset of the ischemic process, the adequacy and efficiency of collateral circulation, the state of general circulation, metabolic requirements of the affected bowel, presence of bacteria within the bowel lumen and associated conditions such as colonic distention. The IMA ligation during an aortic reconstruction is the most important risk factor in the development of colonic infarction [4].

Although it is safe in the majority of cases, patients who lack adequate collateral colonic blood supply are at risk of colonic necrosis. Patients at greatest risk for development of ischemic colitis after aortic reconstruction are those with: ruptured aneurysms, post-aortic reconstruction mean Inferior Mesenteric

Arterial Stump Pressures (IMASP) below 40 mmHg, doppler arterial flow signals that cease after division or occlusion of the IMA, damaged meandering mesenteric artery that has gone unrecognized. On preoperative arteriography, retrograde filling of the Superior Mesenteric Artery (SMA) from the IMA places the patient at higher risk for postoperative ischemic colitis. IMA reimplantation is important in such cases, as well as in the case of severe bilateral hypogastric artery stenosis. The case presented here highlights the importance of considering intraoperative stump pressure measurement together with the evaluation of mesenteric circulation judged by intestinal motility, color and mesenteric arterial pulse palpation. This enables the surgeon to predict when IMA reimplantation is needed in order to avoid colonic ischemia. We feel that it is important to share our experience with the successful management of the following case.

Case Report

A 74 year- old male patient with abdominal pain radiating to his back was referred to our clinic. He had suffered blunt abdominal trauma three weeks before abdominal pain had occurred. At physical examination a pulsatile mass and a systolic murmur were found. Infrarenal aneurysm extending to both common iliac arteries was detected by Doppler USG and DSA (Figure 1).

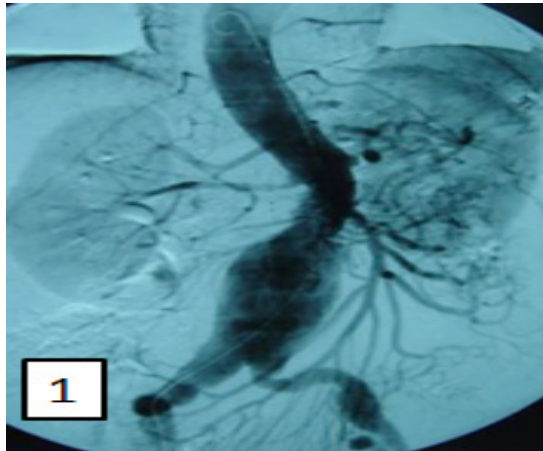


Figure 1: Angiography showing AAA and visualization.

The operation was performed and an aortobiliac Dacron Y graft implanted after aneurysmectomy and IMA detachment (Figure 2,3).

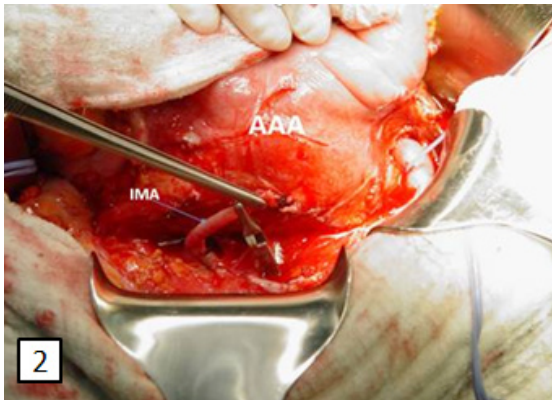


Figure 2: Intraoperative view of the aortic aneurysm sac.

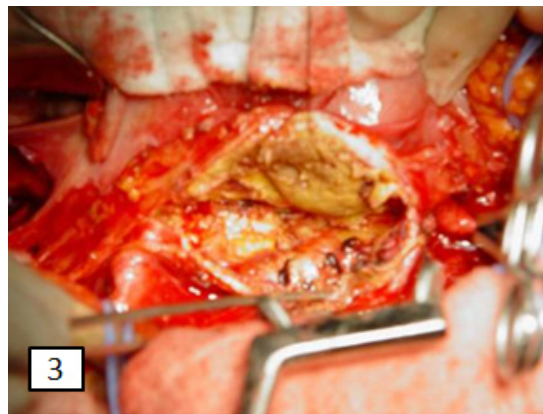


Figure 3: Intraoperative view of the opened aortic aneurysm sac.

IMA pressure measurement was 35 mmHg. The inferior mesenteric artery was anastomosed to the Dacron graft by applying the Carrel patch technique (Figure 4).

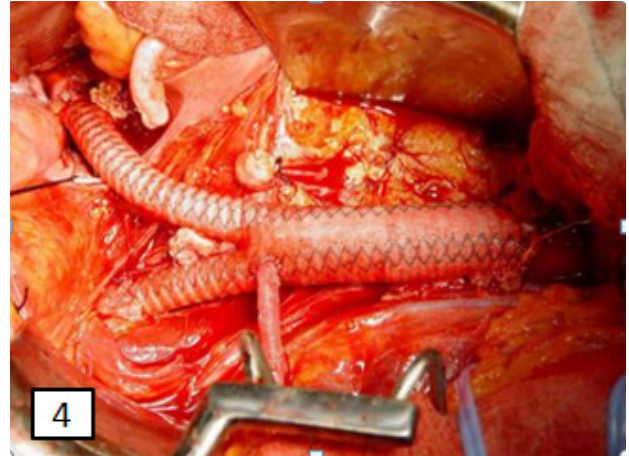


Figure 4: Reimplanted IMA onto a Dacron graft.

The patient was discharged 5 days postoperatively at which time both bifurcation graft and IMA were patent. CTA was repeated six months later confirming the favourable result.

Discussion

The development of Ischemic Colitis (IC) after Abdominal Aortic Aneurysm (AAA) repair is one of the most severe postoperative complications, with a prevalence rate of 1% to 3% [1]. Because of potentially high mortality rates exceeding 50%, it is important to identify possible risk factors that may exacerbate this complication as well as identify patients who could benefit from the IMA reimplantation [5,6]. For this reason, several criteria have been proposed in an effort to predict which patients might be at risk for postoperative ischemic colitis. Most assumptions are based on the fact that direct colonic and / or pelvic revascularization at the time of aortic reconstruction might lessen the risk of postoperative ischemic colitis. Indeed, in one study in which such aggressive revascularization was undertaken, the incidence of endoscopically proven ischemic colitis was reduced to 3% only, being mild and nonfatal [7]. Although various intraoperative methods have been reported to assess sigmoid colonic viability, these methods are not easy to use or not applicable to every patient [8-12]. Intraoperatively, the presence of IMA back-bleeding does not guarantee protection from IC. However, the presence of an IMA stump pressure-to-systemic pressure ratio greater than 0.4 has been reported to be associated with a low likelihood of postoperative colonic ischemia after IMA ligation. Ernst et al. measured IMASP after aortic reconstruction and found a mean pressure of less than 40 mmHg to be predictive of postoperative Ischemic Colitis (IC) [8]. Intravenous

administration of fluorescein has also been reported to help predict benefit from colonic revascularization or immediate colectomy, absence of fluorescence has been reported to be associated with a high risk of IC, whereas “patchy” perfusion has not. Intramural pH measurement by endoluminal tonometry is another method described to detect colonic ischemia intraoperatively. This method measures luminal pCO₂ changes, which are correlated with pH and are in equilibrium with colonic wall pCO₂ values [13]. In one study, a pH lower than 6.86, especially if prolonged, was predictive of postoperative IC [14].

The major blood supply to the pelvic organs is by the IMA. Many authors have proposed re-vascularization of the IMA whenever possible. Systematic re-implantation of IMA diminishes the incidence of IC (15,16). Reimplantation of the inferior mesenteric origin as a button from the aorta to the prosthesis (the Carrel patch technique) and anastomosis of a portion of the aneurysmal sac, including the orifice of the artery into the prosthesis (the inclusion technique, popularized by Crawford) are two techniques that are used for IMA reconstruction. Alternative methods include reimplantation of the IMA without an aortic button, interposition grafting of prosthetic material or autogenous tissue from the aortic graft to the artery. In our case, we have used the Carrel patch technique, which allows for a wider anastomotic orifice between the IMA and Dacron aortic graft and facilitates more precise suturing [17]. ‘Carrel patch technique’ should therefore be preferred for IMA reimplantation.

Conclusion

It is crucial to consider the preoperative state and condition of the hypogastric artery, SMA and IMA at angiography together with intraoperative stump pressure measurements. If the sigmoid colon is ischemic, an attempt should be made to improve flow. This can be done by reimplanting a patent IMA that had been ligated, and by ensuring that hypogastric arteries are perfused. Preservation of as many collateral circuits and restoration of blood flow to as many vital arterial branches as possible are imperative to prevent IC.

References

1. Fitridge R (2012) Complications in vascular and endovascular surgery: How to avoid them and how to get out of trouble. *ANZ J Surg* 82.
2. Björck M, Troeng T, Bergqvist D (1997) Risk factors for intestinal ischemia after aortoiliac surgery: a combined cohort and case-control study of 2824 operations. *Eur J Vasc Endovasc Surg* 13: 531-539.
3. Champagne BJ, Darling RC III, Daneshmand M, Kreienberg PB, Lee EC, et al. (2004) Outcome of aggressive surveillance colonoscopy in ruptured abdominal aortic aneurysm. *J Vasc Surg* 39: 792-796.
4. Seeger JM, Coe DA, Kaelin LD, Flynn TC (1992) Routine reimplantation of patent inferior mesenteric arteries limits colon infarction after aortic reconstruction. *J Vasc Surg* 15: 635-641.
5. Becquemin JP, Majewski M, Fermani N, Marzelle J, Desgrandes P, et al. (2008) Colon ischemia following abdominal aortic aneurysm repair in the era of endovascular abdominal aortic repair. *J Vasc Surg* 47: 258-263.
6. Steele SR (2007) Ischemic colitis complicating major vascular surgery. *Surg Clin North Am* 87: 1099-1114.
7. Matsukura I, Inoue Y, Iwai T (2003) Transanal laser Doppler flowmetry to assess microcirculation in the upper rectum during abdominal aortic aneurysmectomy. *Surgery today* 33: 812-816.
8. Ernst CB, Hagihara PF, Daugherty ME, Griffen WO (1978) Inferior mesenteric artery stump pressure: a reliable index for safe IMA ligation during abdominal aortic aneurysmectomy. *Annals of Surgery* 187: 641-646.
9. Hobson RW, Wright CB, Rich MN, Collins GJ (1979) Assessment of colonic ischemia during aortic surgery by Doppler ultrasound. *Journal of Surgical Research* 20: 231-235.
10. Hobson RW, Wright CB, O'Donnell JA, Jamil Z, Lamberth WC, et al. (1979) Determination of intestinal viability by Doppler ultrasound. *Archives of Surgery* 114: 165-168.
11. Carters MS, Fantini GA, Sammartano RJ, Mitsudo S, Silverman DG, et al. (1984) Qualitative and quantitative fluorescein fluorescence in determining intestinal viability. *American Journal of Surgery* 147: 117-124.
12. Schiedler MG, Cutler BS, Fiddian-Green RG (1987) Sigmoid intramural pH for prediction of ischaemic colitis during aortic surgery. *Archives of Surgery* 122: 881-886.
13. Brinkmann A, Calzia E, Traeger K, Radermaker P (1998) Monitoring the hepatosplanchnic region in the critically ill patient: measurement techniques and clinical relevance. *Intensive Care Med* 24: 542-556.
14. Björck M and Hedberg B (1994) Early detection of major complications after abdominal aortic surgery: predictive value of sigmoid colon and gastric intramucosal pH monitoring. *British Journal of Surgery* 81: 25-30.
15. Marshall JC, Christou NV, Horn R, Meakins JL (1989) The microbiology of multiple organ failure, the proximal gastrointestinal tract as an occult reservoir of pathogens. *Arch Surg* 123: 309-315.
16. Carrico CJ, Meakins JL, Marshall JC, Fry D, Maier RV (1986) Multiple organ failure syndrome: The gastrointestinal tract: The motor of MOF? *Arch Surg* 121: 197-201.
17. Rutherford RB, McCracken T, Foerster J (1993) Atlas of vascular surgery: Basic techniques and exposures. Saunders, Philadelphia 1993.