

## Review Article

### Bloodstain Pattern Analyst -Analyzed a Real Case

Samir Kumar Bandyopadhyay\*, Nabanita Basu

Department of Computer Science and Engineering, University of Calcutta

\*Corresponding author: Samir Kumar Bandyopadhyay, Department of Computer Sc. &Engg, University of Calcutta, Tel: +9831018374; E-mail: 1954samir@gmail.com

Citation: Bandyopadhyay SK, Basu N (2017) Bloodstain Pattern Analyst -Analyzed a Real Case. Forensic Stud 2017: J107. DOI: 10.29011/FSTD-107. 100007

Received: 16 January, 2017; Accepted Date: 21 March, 2017; Published Date: 27 March, 2017

#### Abstract

Strangulation means arrest of circulation in a part of the body due to compression. In manual strangulation, the cause of death is cerebral hypoxia secondary to compression and thereby an occlusion of the vessels supplying blood to the brain. There are cases where it is required to determine between Suicide and Homicide.

This paper considers a case where the cause of death was reported by Investigating Teams suicide since their investigation was that the victim body was on the bed and their findings are that the body was brought down from ceiling of the room to bed after both victims committed suicide. Family members did not satisfy with the decision and they told that it was a case of murder.

After careful observations and analyzing expired spatter blood from mouth and bloodstain patterns on bed, and considering other observations, bloodstain pattern analyst concludes that it is a case of homicide.

In this case none of persons i.e. victims, suspects and experts involved providing their advice are going to be named, because the basic aim of this paper is to explain the incidence happened at the crime. Further in the content of case diary names of victims are not mentioned.

**Keywords:** Bloodstain Pattern Analysis; Expired Blood Spatter; Spatter Patterns; Strangulation

#### Introduction

Bloodstain Pattern Analysis (BPA) studies the interpretation of the shape and distribution of bloodstains connected with a crime. BPA also helps to distinguish between accident, homicide and suicide or to identify bloodstains originating from a perpetrator.

Bloodstain pattern examiners typically adopt the terminology recommended by the Scientific Working Group on BPA (SWG-STAIN). Bloodstain patterns are classified into three categories: passive, transfer and spatter patterns [1].

1. Passive patterns include drip stains, drip trails, drip patterns, flow patterns and blood pools and it is normally caused due to the action of gravitational force.
2. Transfer patterns are due to blood-bearing surface meets another surface.

3. Spatter patterns include cast-offs, splash, expiration, projected etc. Spatter patterns comprise small and tiny bloodstains which are typically smaller than passive stains.

Strangling is compression of the neck that may lead to unconsciousness or death. Then it caused an increasingly hypoxic state in the brain. Strangling can be divided into three general types according to the mechanism used [2]:

- Hanging
- Ligature strangulation
- Manual strangulation

Hanging is that form of asphyxia and caused by suspension of the body by a ligature encircles the neck. In ligature and manual strangulation, the constricting force is also external, but the weight of the body or head plays no part. Ligature strangulation can be suicidal, accidental, or homicidal [3].

Research on manual strangulation most of the cases, the offender and the victim have a family relationship. The most frequent motives for strangulation have been rape, sexual jealousy,

and personal rivalry. Strangling is generally homicidal, hanging commonly suicidal. Some kind of knot is generally present at the neck in almost all cases of hanging particularly suicidal hanging [4,5].

Manual strangulation is a form of violent asphyxia death when the constriction of the air passage at the neck is caused by means of pressure of human fingers, palms or hands upon the throat. In this case murderers use more force to kill the victim than is ordinarily required. The modes of death in case of manual strangulation are asphyxia, congestive suboxia and vagal inhibition; the latter being more common. Evidence of certain typical findings such as head injury sometimes may suggest manual strangulation, even in absence of signs of struggle [6]. It is more natural that struggle between murderer and victim during the incident.

In strangling cases, more than 2-3 turns unusual and generally complex type knot is found tightly at and behind the neck where ligature compression marks are lowdown, horizontally circular except in very rare cases of lifting garroting• when “two ligature ends may’ be obliquely upwards but then multiple turns most unusual [7]. Evidence of suicidal hangings are usually more common and recognizable [8]. There have been cases where the victim has attempted to disguise suicidal hanging as a case of homicide with suspicion of foul play. On dissection of the neck, the underneath soft tissues were soft, whitish and glistening.

In this context, it is mentioned that the first author is a certified bloodstain analyst and the second author analyze the process in consultation with the first author. In this paper a real case diary is reported and describe the process of analysis by bloodstain pattern analyst. The decision must be supported by the evidence, not just on supposition.

## Blood Procurement

Blood procured legally from Kolkata Municipal Slaughter House, Tanagra Kolkata, India. The authors used porcine blood since porcine blood is quite similar to human blood [8,3]. Since fresh blood coagulates over time, 1100 IU of Heparin Injection was added to fresh pig blood to preserve the colloidal consistency of blood. It does not alter the viscosity and specificity of the Non-Newtonian fluid, blood.

## Review Works

Lockard’s exchange principle states that “every time an individual contact another person, place or thing, it results in an exchange of physical materials” [9]. He believed that the criminal leaves something at the crime scene and the same time he is also expected to take something away from the scene with him [9]. When criminal is killing any one there should be bloody stains presence at the crime scene.

The contributions of Professor MacDonnell to the research and interpretation of bloodstain patterns at a crime since 1800s [10]. Forensic Science particularly deals with presentation of evidence within a juridical setting and Stuart H. James’s book on ‘Scientific and Legal Applications of Bloodstain Pattern Interpretation’ depicts the relevance of bloodstain pattern evidence within a juridical setting [11]. Bloodstain Patterns due to neck injuries by manual strangulation distinguishes from other types of blunt injuries including hanging, traumatic blow to the neck, and artifacts of decomposition [12].

Strangulation is in form of violence mostly in the context of domestic violence cases. Sometimes the abuser crushed the victim’s throat with his hands or used a ligature. Serious injuries resulted from strangling often does not have visible injuries [13].

Strangulation is defined as asphyxia or lack of oxygen due to closure of blood vessels and air passages in the neck resulting from external force applied on neck [14]. Strangulation is ligature and manual strangulation in the context of domestic violence [15]. Ligature strangulation is done by the strangler uses a cord-like object such as rope or cable to a scarf or a belt for strangling the victim [16]. In this case, manual strangulation may be done by towel with the help of hands.

Normally suicidal hanging is carried out by attaching one end of a ligature material to a higher point such as ceiling and the other end by forming into either a fixed loop or a slip knot placed around the neck. The person stands on a chair or other support and jumps off or kicking away the support [17,18].

In some cases of manual strangulation where extensive force is applied by the assailant, classical fingernail marks are visualized. In addition to the blunt force injuries of the neck, strangulation produce the signs of asphyxiation, such as pinpoint hemorrhages in the skin, conjunctiva of the eyes, and visceral pleura of deep internal organs [19,20]. Gonzales’s scientific research paper, relying on European references from the 19th century about examination of strangulation victims is considered as best till date [21].

## Case Study at the Crime Scene

A fifty-year lady on 17.03.2016 lodge a written complain to the police station that her grandparents have been found dead in their house and having no sense when she with her mother entered the premises of her grandparents. They noted that door was open. They found that both are lying in two different bed rooms in the flat. There were signs of a struggle by both. Blood stain patterns were seen on both beds. It was alleged by the lady and her mother that some unknown persons entered the house and preplan murder them. The following figures were observed in booth rooms. (Figure 1) showed the male body on the bed whereas (Figure 2) indicated female body on the bed. (Figure 3) indicated that wardrobe

was opened. After searching the inside of the wardrobe the Investigating officer found that some papers are missing and relatives observed that documents related to flat are not there.

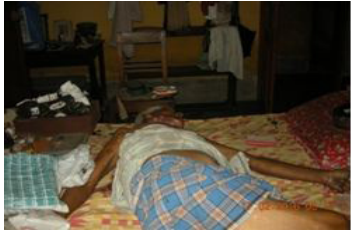

Figure 1: Body of male victim.



Figure 2: Body of female victim.



Figure 3: Image of room.

Based on the complaint case was registered and Investigating Officer came to the premises. He found that there were two different towels around their neck tightly covered and placed body on bed in each room. These were shown in (Figure 4) and (Figure 5). Bloods are ejected from their mouth and nose and bloodstains are found on the bed. He also saw that in each room a plastic rope was found in the ceiling and a chair was placed on the ground just below the ceiling. He also observed that no blood was found on the body. Multiple finger tips contusions and nail scratch abrasions were present over thyroid region over anterior and both lateral aspect of neck, reddish in color. Some insignificant footprints were seen on the floor of both rooms.

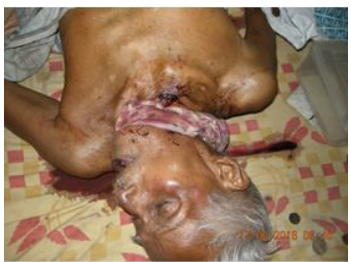

Figure 4: Neck tightly covered by towel.

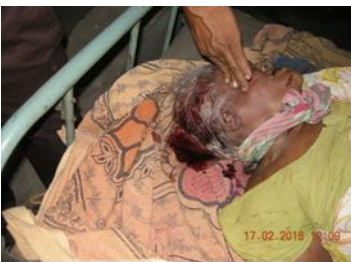

Figure 5: Same situation for female.

The case was controversial because there was no eyewitness to tell that someone had killed both the victims. Also, there was no indication that the deceased had been murdered, or that the body had been moved. It was difficult to understand the actual situation. The following are noted:

- The ceiling fan where the rope was seen was the only point of suspension in the room.

- The condition of the eyes and some marks on the neck were suggestive of hanging.



Figure 6: Suspension seen.



Figure 7: Marks on neck.

The above figures i.e.(Figure 6) and (Figure 7) showed the two noted points described above.

While the investigative process continued an autopsy of both bodies was conducted by a Forensic Pathologist. The Investigating Team talked to doctor who did autopsy. Medical reports showed that both victims had mark on their necks. The basis for their opinion of ligature strangulation was the ligature mark. On autopsy, there was nothing suggestive of hanging, manual or ligature strangulation. The neck was not elongated. It was not grooved. Sub-conjunctiva hemorrhages noticed in both the eyes. Doctor observed that the death was due to mechanical pressure applied on the front and left side of the neck.

## Analysis

The Bloodstain Pattern Analysis always attempts, to the best of his/her ability, to make the correct determination. Family members need to know the truth to reach a point of acceptance. They considered three major components: the physical evidence, the informational pieces and the behavioral aspects. Also, consider what happened before, during and after the incident. It is required to evaluate all other pieces of information in conjunction with the behavioral aspects of the primary persons involved. When analysis the case the analyst collects information from the Investigating Officer and thinks steps to be needed for conclusions based on available clues in the crime spot. These are as follows:

- A. Obtain from Investigating Officer about the view of witnesses regarding the incidence, if any.
- B. Based on these some more questions may be asked to the officer, if required.
- C. Visualize and note the physical evidence obtained from the crime spot or nearby.
- D. Formulate hypotheses about the events that occurred.
- E. Determine whether the witness statements are consistent with the physical evidence.
- F. Through the process of verifying witness statements, admissions/confessions consider the evidence at hand and disprove as many hypotheses as possible.

The Bloodstain Pattern Analysis first understands salient point of the case based on photos which are taken from the crime spot, then create hypotheses/possibilities occurred and analyze the case by considering documents in the case diary, autopsy report and vital/overlooked information available at the crime spot.

The salient points of this case are as described below:

- a) One old man and one old woman were killed in two different rooms.
- b) The main door of the house was open.
- c) Document was stolen.
- d) Signs of a struggle by both.
- e) Two different towels around their neck tightly covered.
- f) Foot prints were present not only in the rooms but also more foot prints were seen from rooms to door in a sequence manner.
- g) Each room a plastic rope was found in the ceiling and also a chair was placed on the ground just below the ceiling.
- h) Condition of the eyes and some marks on the neck of both victims were seen.
- i) No blood /bloodstain were seen in the cloth of both victims.
- j) Expired spatter blood from mouth and bloodstain patterns on bed.

The analyst considers all photos related to his observations in respect of salient points are taken into consideration. The following photos are carefully observed.



Figure 8: (a) and (b) Two bodies are found in different rooms.

(Figure 8) shows that two dead bodies are found in two different rooms. (Figure9) indicates that the main door of the flat is open and it is sure that person or persons came to the flat.



Figure 9: Main door of house.



Figure 10: Wardrobe is open and not in order.

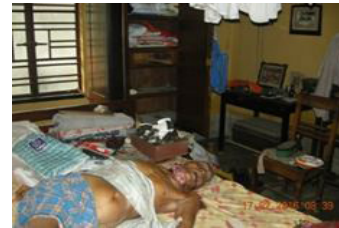

Figure 11: Sign of struggle on bed sheet.

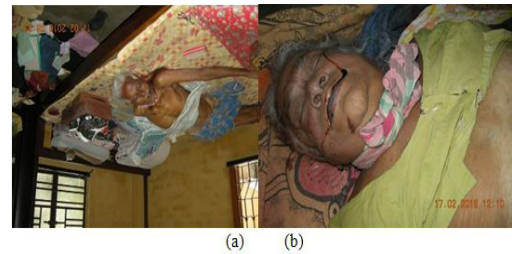


Figure 12: (a) and figure (b) shows towels around their neck tightly covered.




Figure 13: (a), figure (b) and figure (c) indicate single and multiple footprint(s).

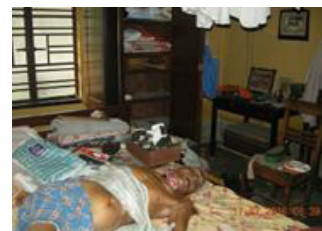

Figure 14: Chair in the room.

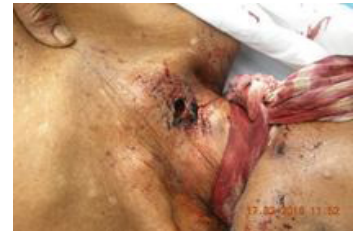

Figure 15: Mark on neck.

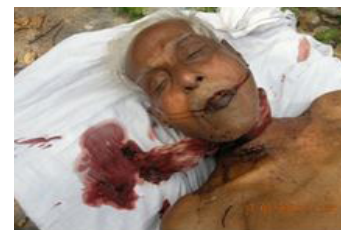

Figure 16: Expired blood from mouth.

It is apparent from above figures that salient points are properly documented and visualized.

After carefully observing the salient points, the Bloodstain Pattern Analyst formulates the following hypotheses:

**Hypothesis 1:** Both of them were dedicated and devoted to his family, friends and community. But there may be some problems so they decided to commit suicide. Before informing Police, Authority relatives may take their body in two different beds so that the story of murder may be created to save the image of the family.

**Hypothesis 2:** Some unknown persons with some motive to force them to commit suicide and placed their bodies in different beds.

**Hypothesis 3:** Some known/unknown persons forced them to commit suicide from ceiling. Due to pressure both victims agreed to do it and hanged themselves from ceiling but due to some unknown reasons they did not die there. Then persons took the bodies from there and carry them to bed. Now these persons forced them with two different towels around their neck tightly covered. Finally, both died.

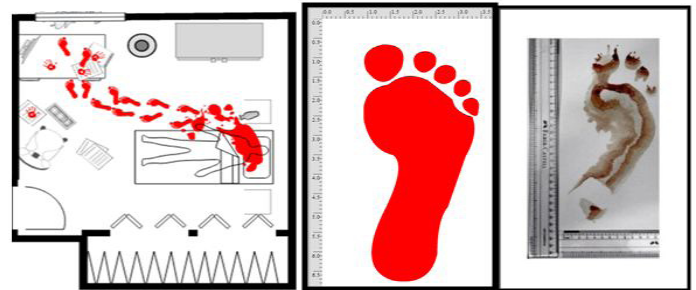
In this particular case the above figures are now used to correlate the crime with the possibilities proposed by bloodstain pattern analyst in terms of hypothesis. Investigating Officer interrogated relatives and neighbors that two persons are happy with each other. Neighbors told relatives, friends and others came to them and sometimes they were staying with them for quite some time and even for whole day.

In the case bloods are ejected from mouth of both victims and bloodstain appears on bed sheet as exposed blood. Bloodstains result from exposed blood that has meet external surfaces in the environment because of a bloodshed event.

After examining the presence of bloodstain patterns in both rooms resulting due to victim has sustained injuries on neck and since pressure applied to his/her neck then exhalation of blood from mouth appears on the bed sheet. In these instances, exhaled or expired bloodstain patterns can result from simple exhalation of blood and air through his/her mouth. The resultant bloodstain patterns can be confused with medium- or high-velocity impact spatter associated with blunt force. There are criteria that may assist with the recognition of bloodstain patterns that have resulted from expired blood.

Investigation Officer examined foot prints in the room and experts of foot prints studied them thoroughly. The observed that foot prints do not match with none of the relatives or neighbors. They suspect that some unknown or known persons entered the rooms and they performed the crime.

Now Bloodstain pattern analyst studied foots prints considering crime reconstruction and measured them the area covered by foot prints present in both rooms. The physical evidence of rooms along with foot prints are shown in (Figure 17).



**Figure 17:** An enlarged view of the room at the crime scene in which the dead bodies of victims and foot prints were present.

The hypothesis1 is nullified since foot prints in the room were not matched with neighbors and relatives. Also, there was no problem between victims. The hypothesis2 is also nullified since there is a sign of a struggle by both at the bed. The hypothesis 3 confirmed the case of murder of two victims for the following conditions:

1. Both initially tried to suicide since chair is just below the ceiling and plastic ropes were found in both ceiling.
2. Condition of the eyes and some marks on the neck indicate they were initially forced to commit suicide.
3. Expired spatter blood from mouth and bloodstain patterns on both beds and two towels around their neck tightly covered. Also, sign of struggle by both with some persons were found since bed sheets were turned. Different foot prints throughout the rooms indicated that both bodies were taken to bed from some place.

The bloodstain pattern analyst concluded that the case is clearly indicated as murder not suicide.

## Conclusions

Suicidal hanging can be misinterpreted as ligature strangulation. Bloodstain Pattern Analysis (BPA) refers to the collection, categorization and interpretation of the shape and distribution of bloodstains connected with a crime. These kinds of stains occur in a considerable proportion of homicide cases. The new facts observed by the bloodstain pattern analyst convinced the police that death of both victims was murdered followed by hanging based on marks on the necks.

## References

1. Scientific Working Group on Bloodstain Pattern Analysis (2009) FBI - Standards and Guidelines - Scientific Working Group on Bloodstain Pattern Analysis: Recommended Terminology.
2. Luke JL (1967) Strangulation as a method of homicide. Arch Pathol 83:64-70.
3. Luke JL (1967) Asphyxial deaths by hanging in New York City, 1964-1965. J Forensic Sci 12: 359-369.

4. James SH (1998) Scientific and legal applications of bloodstain pattern interpretation, Boca Raton, FL: CRC Press
5. James SH, Kish PE, Sutton TP (2005) Principles of bloodstain pattern analysis: Theory and practice. Boca Raton, FL: CRC Press
6. JB Mukharjee 's (2007) Forensic Medicine and Toxicology, 3rd edition
7. Farmer R, Rohde J (1980) Effect of availability and acceptability of lethal instruments on suicide mortality. Acta Psychiatr Scand 62: 436-46.
8. Sen Gupta BK (1965) Studies on 101 cases of death due to hanging. J Indian MedAssoc 45: 135-140.
9. Welding, S. Locard's (2014) Exchange Principle - Forensic Handbook.
10. MacDonell HL(1993) Bloodstain Patterns. Corning, New York: Laboratory of Forensic Science
11. James SH Scientific and Legal Applications of Bloodstain Pattern Interpretation. Boca Raton: CRC Press 320.
12. Kelly M (1997) Trauma to the neck and larynx -Review. CRNA
13. Missliwetz J, Vycudilik W (1997) Homicide by strangling or dumping with postmortem injuries after heroin poisoning? Am. J Forensic Med Pathol 18:211-214.
14. Samarasekera A, Cooke C (1996) The pathology of hanging deaths in Western Australia. Pathology 28: 334-338.
15. Rao VJ, Wetli CV (1988) The forensic significance of conjunctival petechiae. Am. J Forensic Med Pathol. 9: 32-34.
16. Denic N, Huyer DW, Sinal SH, Lantz PE, Smith CR, et al. (1997) Cockroach: the omnivorous scavenger. Potential misinterpretation of post-mortem injuries. Am. J Forensic Med Pathol 18: 177-180.
17. Ortmann C, Fechner G (1996) Unusual findings in death by hanging-reconstruction of capacity for action. Archive fur Kriminologie 197: 104-110.
18. Howell MA, Guly HR (1996) Near hanging presenting to an accident and emergency department. Journal of Accident & Emergency Medicine 13: 135-136.
19. Maxeiner H (1998) "Hidden" laryngeal injuries in homicidal strangulation: How to detect and interpret these findings. J Forensic Sci 43: 784-791.
20. Hood I, Ryan D, Spitz WU (1998) Resuscitation and petechiae. Am. J Forensic Med Pathol 19: 35-37.
21. Gonzales TA (1933) Manual strangulation. Arch Pathol 15: 55-65.