

Research Article

Platelet Rich Plasma Eye Drops: Preparation, Storage and Clinical Use in Dogs and Cats. Preliminary Results

Di Pietro Simona*, Crinò Chiara, Arfuso Francesca, Paci Rosario, Vaccaro Giusi, Giudice Elisabetta

Department of Veterinary Science, University of Messina, Italy

*Corresponding author: Simona Di Pietro, Department of Veterinary Science, University of Messina, Polo Universitario Annunziata, 98168 Messina, Italy. Tel: +390903503509; Fax: +390903503979; E-mail: dipietros@unime.it

Citation: Simona Di Pietro (2017) Department of Veterinary Science, University of Messina, Polo Universitario Annunziata, 98168 Messina, Italy: Arch Vet Sci Technol 2017 AVST: 104. DOI:10.29011/AVST-104/100004

Received Date: 1 February 2017; Accepted Date: 3 February 2017; Published Date: 10 February 2017

Abstract

Several studies demonstrate the effectiveness of Platelet Rich Plasma (PRP) as a promoter of the healing of tissue lesions, due to the high concentration of growth factors. The aim of this study was to evaluate different techniques of preparation and storage of PRP and its effectiveness in corneal lesions in dogs and cats.

Blood samples from ten healthy donor dogs were used for PRP production, with sodium citrate as an anticoagulant. Various centrifugation methods were compared and products obtained were examined microscopically for manual counting and morphological assessment of platelets immediately and after cryopreservation at +4 °C and -20° C for 1, 2, 3, 7, 14 and 30 days. The refrigerated samples remained unchanged until 24 hours, while those frozen up to 14 days. For the clinical trial, two dogs and one cat with unilateral corneal ulcer were enrolled. They were treated with allogeneic PRP obtained from a donor dog and frozen in daily aliquots to be used as eye drop for 7-15 days. PRP was well tolerated in all the animals, which showed rapid improvement of the lesions. Although preliminary, the results support the use of PRP in veterinary ophthalmology, even when the patient's condition prevents the collection of the autologous PRP (small size, bad temperament, hematological disorders).

In conclusion, although the effectiveness of PRP is now widely documented, the new challenge is to obtain a high quality, not too expensive, easy to prepare and stable product, all properties that make it suitable for a routine clinical use.

Introduction

Platelet rich plasma (PRP) is a blood derived product that provides higher concentration of essential growth factors (GF) by concentrating platelets in a small volume of plasma. The GF, including platelet-derived GF (PDGF), transforming GF- β (TGF- β), vascular endothelial GF (VEGF), fibroblastic GF (FGF), insulin-like GF (IGF) and epidermal GF (EGF), have a major role in wound healing and enhance the physiological process at the site of the injury/surgery [1]. Concentrated GF lead to accelerated endothelial and epithelial regeneration and stimulate angiogenesis, collagen synthesis, soft-tissue healing, and homeostasis [2].

PRP currently has much broader clinical applications in humans and animals, extending to orthopedic, oral-maxillofacial, dermatologic surgery and sports medicine. Some researchers have found that autologous PRP promote cutaneous wound healing in

dogs and other species [3-10]. PRP has also been used to repair cartilage, tendons, bone and skin [11-12].

In human ophthalmology some authors reported that PRP eye drops can be used to treat various ocular surface diseases, such as severe dry eye syndrome, persistent epithelial defects, and neurotrophic keratitis [13]. In veterinary ophthalmology corneal ulcer healing was achieved in rabbits using PRP [14].

PRP can be processed for application as gel, clot, and graft or for injection at a site of injury. When the patient's general condition prevents the use of own blood for the production of this concentrates or when it is difficult to collect blood, as in small animals, the heterologous PRP can also repair tissue injuries [12,14,15]. Although the heterologous PRP can be preferable because there is no risk of cross infections, these preparations have varying quality of PRP, compared to allogeneic preparations provided by blood

banks according to standardized criteria [16].

Several protocols to obtain PRP were used, trying to optimize temperature, centrifugation speed and duration. The final products have different platelets concentrations, under-lining the lack of a standardized approach to these procedures [16] and making it difficult to compare results. The ideal PRP should have a platelet concentration equal to 2-8 times the baseline content, with not too high numbers of mononuclear cells, neutrophils, and red blood cells that could affect the clinical efficacy of the product and cause an inflammatory response after its use [1].

The aim of this study was to establish a low-cost method to prepare PRP; different techniques of preparation of PRP from canine donors and storage were evaluated, comparing various centrifugation methods. Obtained products were examined microscopically for manual cell counting and morphological assessment of platelets immediately and after cryopreservation at +4 °C and -20° C for 1, 2, 3, 7, 14 and 30 days.

Furthermore, a preliminary clinical trial was performed to assess the efficacy of the allogeneic PRP in healing corneal lesions in dogs and cats.

Materials and methods

10 healthy adult Labrador retriever dogs (12-27 months of age; mean bodyweight: 26.09 Kg; five neutered males, three spayed and two intact females) were enrolled as blood donors with the informed owner consents. The results of physical examination complete blood cell count and serum chemistry (BUN, creatinine, ALT, AST, GGT, bilirubin, phosphorus, calcium and protein electrophoresis) revealed no abnormalities. The dogs had not undergone drug treatment in the month prior to enrollment and were negative to serological and molecular tests for the canine vector borne disease that could be transmitted by blood products. The sampling was performed during the periodic health examinations. From each dog 10 mL of blood were collected. To obtain the PRP, tubes containing anticoagulant sodium citrate (3.0 mL) were used; samples were subjected to double centrifugation (Thermo Scientific IEC CL10) for different times and revolution per minute (tests from 1 to 7), as reported in Table 1. After first centrifugation ¾ of supernatant plasma were eliminated and the sample was centrifuged again, obtain in supernatant PRP (approximately 450-600 µL in relation to the hematocrit of the blood sample).

N. Test	Centrifugation Methods		References
	First Centrifugation	Second Centrifugation	
1	1200 rpm x 10'	1200 rpm x 15'	Carvalho et al. 2011
2	1000 rpm x 10'	1500 rpm x 10'	Kim et al. 2012

3	1100 rpm x 6'	1400 rpm x 7'	Anitua et al. 2015
4	2300 rpm x 15'	3000 rpm x 10'	Anitua 1999
5	2300 rpm x 10'	1000 rpm x 12'	Personal Procedure
6	1500 rpm x 5'	3200 rpm x 15'	Personal Procedure
7	1200 rpm x 10'	700 rpm x 25'	Personal Procedure

Table 1: Centrifugation methods applied for the preparation of the PRP.

The product was then divided into 8 aliquots, taking care to prevent the activate platelets. A first aliquot was used for the assessment of the number of white and red blood cells (Barker chamber) and of the platelets and their morphology (Thoma chamber). In order to evaluate the storability of PRP, 3 aliquots were chilled to +4°C and analyzed after 24, 48 and 72 h; the remaining 4 aliquots were frozen at -20°C and analyzed after 2, 7, 14 and 30 days.

Subsequently, in order to evaluate the clinical effects of PRP on corneal lesions, 2 dogs and 1 cat were enrolled in the study. The animals, visited at the Veterinary Teaching Hospital of University of Messina because suffering from unilateral ulcerative corneal disease, were treated with allogeneic PRP (homologous in dogs and heterologous incats) by donor dogs, applied topically as drops in the conjunctival sac.

Case 1

An adult intact male Boxer dog (3 years) showed a chronic ulcerative keratitis in the right eye caused by a previous trauma. At the visit keratoconus, bullous keratitis with corneal neovascularization and edema were observed; a round ulcer was localized in the central cornea, positive to the fluorescein stain. The dog had been subjected to antibiotic and anti-inflammatory treatment for at least 7 days, without improvement. The dog was treated with autologous PRP eye drops twice daily for 15 days.

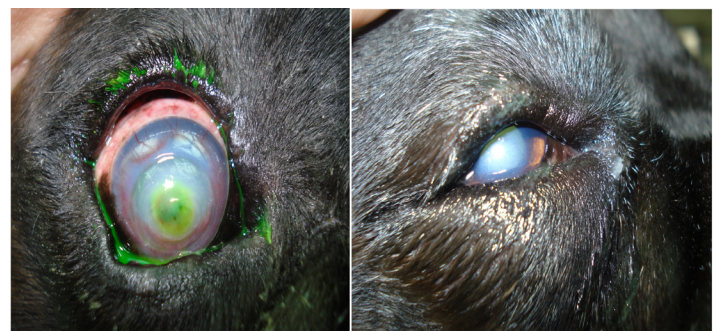

Fig. 1 – A: Adult male Boxer dog with a chronic ulcerative keratitis in the right eye. A bullous keratitis with central fluorescein positive ulcer was observed. **B:** At 15th days follow up disappearance of keratoconus and reduction of corneal vascularization were observed; a moderate corneal edema was still present.

Case 2

An adult intact female Yorkshire terrier dog was affected by a spontaneous chronic corneal epithelial defect, which had caused a superficial recurrent ulceration located in the lateral cornea of the right eye. The dog had already presented two relapses within 15 days. The autologous PRP eye drops was administered twice daily for 7 days.

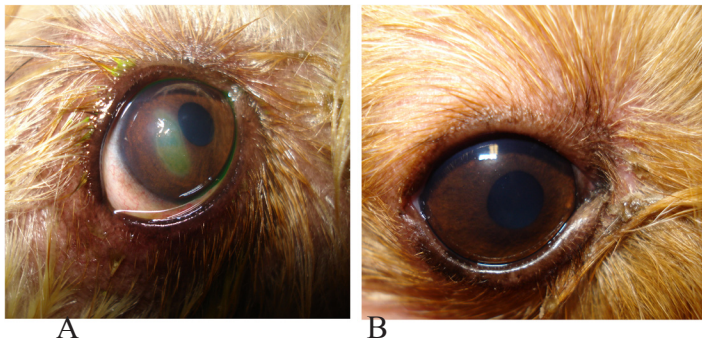
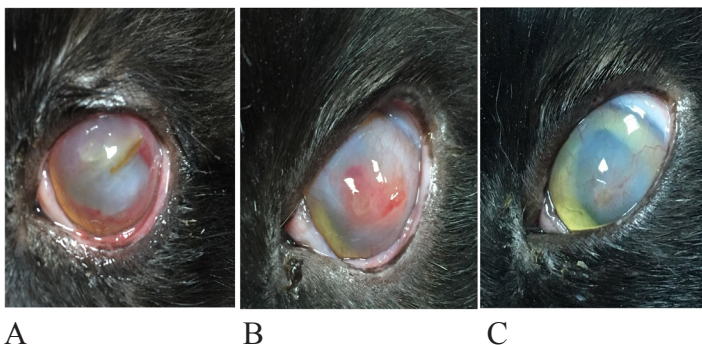


Fig. 2 - Adult female Yorkshire terrier dog affected by a spontaneous chronic corneal epithelial defect.

Case 3

An adult neutered male Domestic Short Hair (DSH) cat showed an infected corneal ulceration, as consequence of an ocular traumatic injury occurred for at least one week. The entire corneal surface appeared edematous with a yellow stromal opacity; in the central cornea melting of the stroma was observed. Deep corneal “hedge-like” vessels were present for 360 degrees around the limbus. The cat was subjected to antibiotic treatment; heterologous PRP was used because it was difficult to collect blood without a sedation of the cat. PRP eye drops were instilled twice daily for 15 days.

After preparation, PRP was divided into daily aliquots (0.1 mL) and immediately frozen. At the time of administration the PRP was defrosted at room temperature and a drop was placed into the affected eye.



Results

Preparation and storage of PRP -The automatic platelet count in donor dogs was on average $308,6 \pm 56,1 \times 10^3/\mu\text{L}$ (range: $228-423 \times 10^3/\mu\text{L}$), so the samples were suitable for the preparation of the PRP. The results showed that the tests 1 to 4, performed according to methods described in the literature [17-20], and the tests 5 and 6, modified in accordance with our experiences, have not produced satisfactory results. In particular, although the number of platelets was increased than the corresponding whole blood, the cell morphology of platelets appeared altered and phenomena of aggregation and/or fragmentation were obvious. Moreover, a high number of red and white blood cells were present. The sample was not considered suitable and, therefore, does not proceed to the next steps of cryopreservation (refrigeration and freezing). The test 7 has provided an adequate sample of PRP: the number of platelets oscillated between $590 \times 10^3/\mu\text{L}$ and $739 \times 10^3/\mu\text{L}$; the cell morphology was maintained, with a very low percentage of elements fragmented and/or activated. The number of red and white blood cell count was equal to $0/\mu\text{L}$. The PRP, refrigerated at 4°C , after 24 hours showed number and morphology of platelets similar to that of fresh PRP; after 48 hours it was noted an apparent increase in the number of platelets per field, due to the presence of platelet scattered fragments and agglomerates, proving the activation of platelet; after 72 hours a visible clot was present; the samples, therefore, not retained. The PRP, frozen at -20°C , after 48 hours, 7 and 14 days was unchanged, both in platelets number and cell morphology; after 30 day of storage the number and morphology of platelets could not be evaluated; numerous fragments and agglomerates were present in every sample.

Clinical trial-The PRP was well tolerated in the three animals investigated, which showed rapid improvement of the lesions. Case 1 at the first follow up visit (7th days) showed an improvement of the lesion with disappearance of keratoconus and significantly reduction of corneal edema and vascularization. At the second visit (15th days) the superficial corneal vessels were disappeared and a moderate degree of edema was still present in the central portion of cornea. Case 2 at the first follow up visit the epithelial ulcer was disappeared, as tested by negative fluorescein stain. Case 3 at the 7th day follow up showed a moderate improvement of the lesion, with the corneal stroma slightly harder than before the therapy; the diffuse corneal edema and the deep vessels from the limbus were still present. Only at 15th days follow up a significant healing with reduction of the corneal edema and vascularization was observed. In this case the therapy was extended for one month, obtaining an almost complete recovery of the corneal tissue at this time, remaining a corneal leukoma in the central area, with some vessels from limbus.

All animals showed no adverse effects with the use of these

products that were generally well tolerated, as referred by their owners.

Discussion

PRP is known to be powerful, effective, and safe cure for various wound-healing processes. Multiple commercial PRP separation systems have been developed for both human and veterinary use [1]. New challenge is to obtain a high quality product, easy to prepare and stable, all properties that make it suitable for a routine clinical use, although most methods require expensive and sophisticated technical equipment. In this report we obtained effective, safe and inexpensive eye PRP drops to be used in clinical practice as therapeutic tool to enhance epithelial wound healing in ocular surface disease in dogs and cats. In our experience the storage conditions greatly influenced the quality of PRP. After 30 days of storage at -20°C PRP samples showed various alterations. Therefore, based on these findings, the PRP should not be stored for a long time.

Our results support the use of allogeneic PRP also in veterinary ophthalmology, even when the patient's condition prevents the collection of the autologous PRP (small size, bad temperament, hematological disorders).

PRP has shown beneficial effects in the corneal healing of the treated animals and no serious adverse effects have been described. The mechanism of action of PRP is likely based on the high concentration of epithelia-trophic growth factors, which might lead to faster healing. The high concentrations of growth factors also have an effect on tightening the epithelial adhesion complex that represents the basic principle of treatment of spontaneous chronic corneal epithelial defects.

Conclusions

The study reported in this paper is certainly not without limitations. First, the sample size was very small and further studies on larger patient series involving longer follow-up are needed in order to confirm our findings, standardize the preparation procedures of the PRP and determine the ideal duration of treatment.

Despite this limitation this preliminary study could encourage the use of PRP in the field of veterinary ophthalmology as a routine tool to improve the outcome of corneal ulcerative disease in dogs and cats.

Acknowledgement

This research received no specific grant from any funding.

References

1. Carr BJ, Canapp SO Jr, Mason DR, Cox C, Hess T (2015) Canine Platelet-Rich Plasma Systems: A Prospective Analysis 2: 73.
2. Cho-Hee J, Na-Young E, Hyo-Mi J, Hae-Won J, Eul-Soo C, et al. (2016) Effect of autologous platelet-rich plasma application on cutaneous wound healing in dogs. *J Vet Sci* 17: 79-87.
3. Kim JH, Park C, Park HM (2009) Curative effect of autologous platelet-rich plasma on a large cutaneous lesion in a dog. *Vet Dermatol* 20: 123-126.
4. Sardari K, Emami MR, Kazemi H, Movasagi AR, Goli AA, et al. (2011) Effects of platelet-rich plasma (PRP) on cutaneous regeneration and wound healing in dogs treated with dexamethasone. *Comp Clin Pathol* 20: 155-162.
5. Alishahi MK, Mofidpoor H, Alishahi MAK (2014) Histopathological evaluation of the effect of platelet-rich fibrin on canine cutaneous incisional wound healing. *World Appl Sci J* 31: 676-680.
6. Al-Bayati AH, Al-Asadi RN, Mahdi AK, Al-Falahi NH (2013) Effects of autologous platelet-rich plasma on full-thickness cutaneous wounds healing in goats. *Int J Anim Vet Adv* 5: 233-239.
7. DeRossi R, Coelho ACAO, Mello GS, Frazílio FO, Leal CRB, et al. (2009) Effects of platelet-rich plasma gel on skin healing in surgical wound in horses. *Acta Cir Bras* 24: 276-81.
8. Monteiro SO, Lepage OM, Theoret CL (2009) Effects of platelet-rich plasma on the repair of wounds on the distal aspect of the forelimb in horses. *Am J Vet Res* 70: 277-282.
9. Fathi WK (2012) The effect of hyaluronic acid and platelet-rich plasma on soft tissue wound healing: an experimental study on rabbits. *Al-Rafidain Dent J* 12: 115-125.
10. Kimura A, Ogata H, Yazawa M, Watanabe N, Mori T, et al. (2005) The effects of platelet-rich plasma on cutaneous incisional wound healing in rats. *J Dermatol Sci* 40: 205-208.
11. Bazzano M, Piccione G, Giannetto C, Tosto F, Di Pietro S, et al. (2013) Platelet Rich Plasma Intralesional Injection as Bedside Therapy for Tendinitis in Athletic Horse. *Acta Scientiae Veterinariae* 41: 1145.
12. Abegão KGB, Bracale BN, Delfim IG, dos Santos ES, Laposy CB, et al. (2015) Effects of heterologous platelet-rich plasma gel on standardized dermal wound healing in rabbits. *Acta Cir Bras* 30: 209-215.
13. Lee JH, Kim MJ, Ha SW, Kim HK (2016) Autologous Platelet-rich Plasma Eye Drops in the Treatment of Recurrent Corneal Erosions Korean. *J Ophthalmol* 30: 101-107.
14. Kaffashi Elahi R, Mousavi GH, Mohajeri D (2012) Effects of topical heterologous blood serum and bovine thrombin activated platelet rich plasma on experimental corneal stromal ulcers in rabbit. *Adv Environ Biol* 6: 95-99.
15. Rezende UM, Silva RBB, Bassit ACF, Tatsui NH, Sadigursky D, et al. (2011) Efeito do plasma rico em plaquetas na apoptose pós-traumática de condrocitos. *Acta Ortop Bras* 19: 102-105.
16. Piccin A, Di Piero AM, Canzian L, Primerano M, Corvetta D, et al. (2016) Platelet gel: a new therapeutic tool with great potential. *Blood Transfus* 38
17. Carvalho MD, Suaid FF, Santamaria MP, Casati MZ, Nociti Jr FH, et al. (2011) Platelet-rich plasma plus bioactive glass in the treatment of intra-bone defects: a study in dogs. *J. Appl. Oral Sci* 19: 82-89.
18. Kim KM, Shin YT, Kim HK (2012) Effect of autologous platelet-rich plasma on persistent corneal epithelial defect after infectious keratitis. *Jpn J Ophthalmol* 56: 544-550.
19. Anitua E (1999) Plasma Rich in Growth Factors: Preliminary Results of Use in the Preparation of Future Sites for Implants. *Int J Oral Maxil-*