

## Research Article

# Effects of Methylene Blue Mediated Photodynamic Therapy on Solid Ehrlich Tumor and Second Ehrlich Tumor Implant in Mice

MuriloPenteado Del-Grande, Lucas Martins Chaible, Maria Lucia ZaidanDagli\*

Laboratory of Experimental and Comparative Oncology, Department of Pathology, School of Veterinary Medicine and Animal Science, University of São Paulo, São Paulo, SP, Brazil.

\***Corresponding author:** Maria Lucia ZaidanDagli, Laboratory of Experimental and Comparative Oncology, Department of Pathology, School of Veterinary Medicine and Animal Science, University of São Paulo, São Paulo, SP, Brazil; Tel: +00-55 11 3091 7712; Fax: +00-55 11 3091 7829; E-mail: mlzdagli@usp.br

**Citation:** Del-Grande MP, Chaible LM, ZaidanDagli ML (2017) Effects of Methylene Blue Mediated Photodynamic Therapy on Solid Ehrlich Tumor and Second Ehrlich Tumor Implant in Mice. Arch Vet Sci Technol, 2017: AVST-122. DOI:10.29011/AVST-122/100022

**Received Date:** 20 June, 2017; **Accepted Date:** 21 June, 2017; **Published Date:** 28 June, 2017

### Abstract

PhotoDynamic Therapy (PDT) uses interaction of light, photosensitizing agent and production of reactive oxygen species, leading to cell death. Methylene Blue (MB) issued for PDT due to its photochemical properties. Here we investigated the effects of Methylene Blue Mediated Photodynamic Therapy (MB-PDT) on the solid Ehrlich tumor and second Ehrlich tumor implant in mice. For MB-PDT, MB at 1% and diode laser were used. Swiss male mice received dorsal inoculation of Ehrlich tumor cells and, 9 days after, mice were separated into 3 groups: MB-PDT (Group 1) surgically removed (Group 2), or untreated (Group 3). One day after treatment, all groups received a second Ehrlich tumor implant on the left footpad, measured for 17 days. Spleen, lymph nodes and tumor mass were weighed upon necropsy and processed for histopathology. Group 1 Ehrlich tumors showed significant size reduction after MB-PDT. Morphometry of second Ehrlich tumor in Group 1 mice showed significantly lower volume fraction of tumor cells, higher inflammatory infiltrate and necrosis. Relative spleen weight was higher in Group 1 mice, with white pulp hyperplasia. Per these results, MB-PDT reduced primary Ehrlich tumor growth and impacted the growth of a second tumor. These results point towards possible biotechnological applications of MB-PDT.

**Keywords:** Photodynamic Therapy, Methylene Blue, Ehrlich Tumor, Cancer Treatment.

### Introduction

Current treatment of solid tumors is mainly based on their surgical excision. Radiotherapy and chemotherapy are adjuvant treatment modalities commonly used, depending on tumor type. PhotoDynamic Therapy (PDT) is a method to treat cancer based on the interaction between a photosensitizing agent, light and molecular oxygen. There are numerous types of photosensitizers, which can be administered by intravenous, oral or topical routes. The illumination of the tumor with visible light in order to activate the photosensitizer is taken after certain time of agent administration, leading to production of Reactive Oxygen Species (ROS), determining cellular death by necrosis and/or apoptosis [1]. Methylene Blue (MB) is a molecule that has been considered as a drug for photodynamic therapy (PDT). According to [2], MB

has the potential to treat a variety of cancerous and non-cancerous diseases, with low toxicity and no side effects. An interesting feature of PDT is that it may activate the immune system against tumor cells. The phototoxic effects on cell membrane release a number of inflammatory mediators leading to innate immune system activation. Local inflammation and neoplastic cell death provoke tumor antigen presentation [3]. Antigen presentation promotes activation of adaptive immune system and there is sensitization of T lymphocytes (CD8+) leading to a specific response to the treated tumor. This adaptive immune response would be involved in the killing of tumor cells. In addition, B lymphocytes are sensitized to tumor antigens, promoting a long-term tumor control. The production of antitumor antibodies may be suggested, although this has not yet been shown through experimental models in this study [4], we aimed to verify if treating a primary Ehrlich tumor with Methylene Blue (MB) at 1% based PDT (MB-PDT) could present any systemic influence on the growth and behavior of a second Ehrlich tumor implant in mice.

## Materials and Methods

### Animals

Male Swiss mice, weighing 25-35g, were obtained from the Animal Facility of the Department of Pathology, School of Veterinary Medicine and Animal Science, University of São Paulo, Brazil. During the experiment, animals were kept in polycarbonate boxes covered with wood shavings, kept in a room with ventilation, exhaust and controlled climate with temperatures between 22 and 24 °C, relative humidity 55% and light night/day cycle of 12 hours. Animals were fed with a balanced diet and water *ad libitum*. Animal use was in accordance with the ethical principles of animal experimentation of the Ethics Committee on Animal Use of the School of Veterinary Medicine and Animal Science of the University of São Paulo, protocol number 2235/2011.

### Experimental Design

Thirty Swiss male mice were inoculated with Ehrlich tumor cells on the subcutaneous region of the dorsum. Nine days after, Group 1 mice (n=10) received one session of MB-PDT (described ahead), and Group 2 mice (n=10) were submitted to surgical excision of primary tumor. A third group of mice, Group 3 (n=10) received no treatment and primary tumor kept growing. Twenty-four hours after MB-PDT, or surgery of primary tumor, Group 1, Group 2 and Group 3 mice received a second Ehrlich tumor implant on the left footpad; these tumors were measured with a caliper for 17 days, when mice were euthanized [5]. At necropsy, spleen and lymph nodes were weighed and processed for histological analysis. Tumor samples were collected, routinely processed for embedding in paraffin, and the 5µm H&E sections were analyzed through quantitative morphometry, according to [6]. In addition, blood samples were taken for leukocyte count before euthanasia.

### Ehrlich Tumor Inoculation

Animals were physically restrained and with sterile syringes and needles were given 0.05 ml of suspension containing 2.5 x 10<sup>6</sup> tumor cells on the subcutaneous dorsal region (primary Ehrlich tumor) or left footpad (second Ehrlich tumor).

### Ehrlich Tumor Treatment

#### Group 1-Methylene Blue Photodynamic Therapy

At ninth day of primary tumor growth, the Group 1 animals received one session of MB-PDT. Animals were anesthetized with intraperitoneal administration of ketamine hydrochloride (100 mg/kg) associated with xylazine (20 mg/kg). The tumor site was shaved and local antisepsis was performed with iodized 70° alcohols. With sterile needles and syringes, 0.05 ml of 1.0% methylene blue solution (Synth®) in sterile 0.9% NaCl was administered by intratumoral injection. After 10 minutes, tumor was irradiated for 9 minutes at a dose of 54 J, using an InGaAlP medium diode laser

emitting visible red light at a wavelength of 660 nm and power output of 100 mW. During irradiation, all researchers wore safety goggles.

#### Group 2-Surgical Excision

At ninth day of primary tumor growth, the dorsal Ehrlich tumors from Group 2 animals were surgically excised. Animals were anesthetized with intraperitoneal administration of ketamine hydrochloride (100 mg/kg) associated with xylazine (20mg/kg). The tumor site was shaved and local antisepsis performed with iodized 70° alcohols. The tumors were surgically excised, with margins of approximately 2 mm. Skin sutures were performed with nylon (4-0) in simple uninterrupted sutures. Quantitative morphometric analysis of the second Ehrlich tumor Volumetric Fraction (VF) of footpad cellular components Images of H&E sections of the left footpad were taken with a Nikon DXM1200c® camera coupled to a light microscope Nikon Eclipse E800®. With 20x magnification lenses, 8 fields were photographed and images were digitized by IMAGE PRO PLUS® software. Using open source ImageJ software, a grid with 35 points was overlapped on each field. Each point was determined as tumor cells, inflammatory infiltrate, necrosis and other (Vessels, Muscle, Subcutaneous, etc.).

#### Footpad Necrosis Area

Images of H&E sections of the left footpad were taken with a Nikon DXM 1200c® camera coupled to a light microscope Olympus model SZX2-ILLK®. With 0,25x magnification lenses, the entire footpad area was photographed using open source ImageJ software, total area and necrosis area were determined.

#### Statistical Analysis

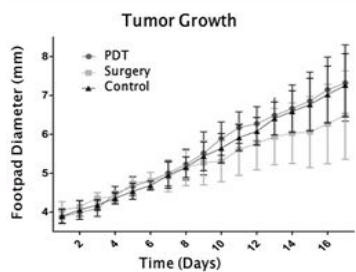
For data analysis, the statistical software Minitab 16® (Minitab Inc., PA, USA) and GraphPad Prism 5.00® (GraphPad Software, Inc., San Diego, USA) were used. Normality was verified using the Anderson-Darling test. Homoscedasticity was verified by Bartlett test. For parametric data, we used analysis of variance ANOVA followed by the Tukey's test for comparison between experimental groups. Kruskal-Wallis test followed by Dunn's test for comparison between groups was used for non-parametric data. The growth curve of the Ehrlich tumor was analyzed by two-way ANOVA. Differences of p < 0.05 were considered statistically significant. Data were expressed as mean ± standard deviation.

## Results

Analysis of Group 1 Ehrlich tumor growth the primary Ehrlich tumor inoculated at the dorsum of Group 1 animals, which received MB-PDT, presented ulceration and necrosis; the epithelium healed in a few days. Therefore, the tumors were not completely cured, and continued to grow. The Group 2 animals, which received surgical excision of primary tumor, did not show any signs of local recurrence, with no further primary tumor growth. The untreated

animals of Group 3 showed continuous primary tumor growth to the end of the experiment.

Analysis of Second Ehrlich Tumor Growth as previously stated, 24 hours after the initial treatment, animals from Group 1, Group 2 and Group 3 were inoculated with second Ehrlich tumor cells on the left footpad, and the tumor growth was evaluated with a caliper for 17 days. (Figure 1) shows the left footpad growth curve (diameter in mm) by time (days) of mice bearing Ehrlich solid tumor treated either with PDT, surgery or no treatment (control). Data are presented as mean  $\pm$  standard deviation. There was no significant difference between groups PDT and Surgery and Control ( $p > 0.05$ ).

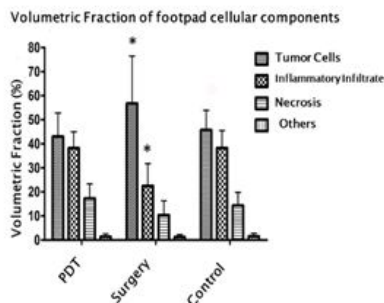


**Figure 1:** Ehrlich tumor growth in mouse left footpad (diameter in mm) by time (days) of mice bearing Ehrlich Solid tumor treated either with MB-PDT (Group 1), surgery (Group 2) or no treatment (Control-Group 3). Data are presented as mean  $\pm$  standard deviation. There was no significant difference between groups (two-way ANOVA  $p > 0.05$ ).

### Quantitative Morphometric Analysis

#### Volumetric Fraction of Footpad Cellular Components: Tumor Cells and Inflammatory Infiltrate

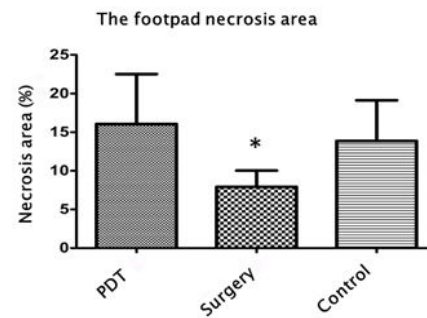
The second tumor transplant was evaluated through morphometric analysis using images of H&E sections of the left footpad. (Figure 2)



**Figure 2:** Volume Fraction (VF) of the cellular components in Ehrlich tumor in footpads of mice. The ANOVA revealed a significant difference in VF of tumor cells ( $p < 0.0001$ ) and inflammatory infiltrate ( $p < 0.0001$ ). The Turkey post-test showed that VF of tumor cells is significantly higher in the surgery group ( $p < 0.05$ ), with a VF of inflammatory infiltrate significantly lower in this group ( $p < 0.05$ ). The VF of necrosis showed no significant difference between groups ( $p = 0.0669$ ).

### Footpad Necrosis Area

The necrotic areas in the left footpad were measured and the results are shown in (Figure 3). Using the Kruskal-Wallis test the results are significant differences in the necrotic area in different groups ( $p = 0.0007$ ). The Dunn test showed a significantly smaller area of necrosis ( $p < 0.05$ ) in the surgery group compared with PDT and control groups.

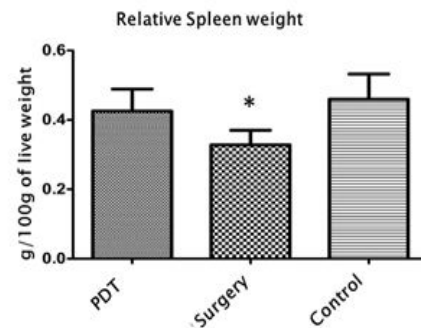


**Figure 3:** Necrotic area within solid Ehrlich tumor in the left footpad of mice. The Kruskal-Wallis test revealed a significant difference in the necrotic area on different groups (Groups 1, 2 and 3) ( $p = 0.0007$ ). The Dunn test showed a significantly smaller area of necrosis ( $p < 0.05$ ) in the surgery group compared with MB-PDT and control groups.

### Lymphoid Organ Analysis

#### Relative Spleen Weight

(Figure 4) illustrates data on relative spleen weight. The ANOVA revealed significant difference between groups ( $p < 0.0001$ ). The Tukey post test showed that relative spleen weight of the surgery group (Group 2) was significantly lower ( $p < 0.05$ ) when compared to PDT (Group 1) and control (Group 3) groups.



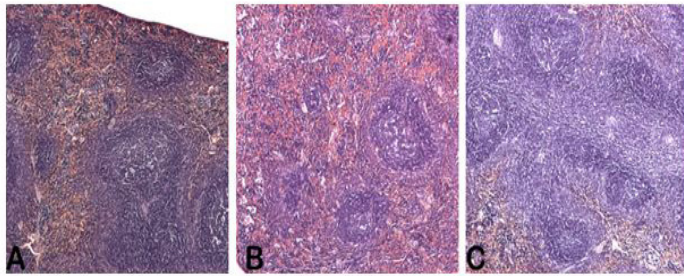
**Figure 4:** Relative spleen weight of mice bearing Ehrlich tumor and treated with MB-PDT (Group 1) or surgery (Group 2). The ANOVA revealed significant differences between groups ( $p < 0.0001$ ). The Turkey post test showed that the relative spleen weight of the surgery group was significantly lower ( $p < 0.05$ ) compared with MB-PDT and control groups.

### Spleen Histological Analysis

(Figure 5) illustrates histological pattern found in mice bearing Ehrlich solid tumor spleen. Surgery group spleens (Group 2) did not show any significant morphological changes (Figure 5B). Group



1 (MB-PDT) (Figure 5A) and Group 3 (control group) (Figure 5C) mice revealed organ architecture preservation; however, lymphoid follicles and its germinal center and marginal zone had apparently become more prominent, with coalescent areas between follicles. Findings suggest lymphoid hyperplasia in the spleen of Group 1 (MB-PDT) animals.



**Figure 5:** Histological pattern in the spleen of mice bearing Ehrlich solid tumor and treated with MB-PDT (Group 1) or surgery (Group 2). Surgery group didn't show any significant morphological changes (Figure 5A). MB-PDT (Group 1) (Figure 5B) and control group (Group 3) (Figure 5C) mice revealed preserved organ architecture, however lymphoid follicles, their germinal centers and marginal zone had apparently become more prominent, with coalescent areas between follicles. It has also been observed an expansion of the cellular cuff around the central arteries. The findings suggest a lymphoid hyperplasia in the spleen of these animals.

#### Relative Lymph Node Weight

The ANOVA regarding the relative weight of the left popliteal lymph node revealed no significant differences between groups ( $p = 0.0622$ ).

#### Left Popliteal Lymph Node Histological Analysis

Histological sections of popliteal lymph nodes showed similar patterns between groups. There was marked hyperplasia of lymphoid follicles and germinal center increase. There were many mononuclear cells phagocytosing cellular debris (tangible body macrophages) in lymphoid follicles. The pattern is characteristic of reactive lymph node hyperplasia. Para cortical and interfollicular region hyperplasia were observed and caused by increase of lymphoid cells with eccentric nuclei, similar to plasma cells. There was also sinusoidal histiocytosis characterized by medullary cord hyperplasia and hypercellularity of medullary sinuses, filled with reticular cells. All groups had cells with the phenotypic characteristics of the Ehrlich tumor, including atypical mitoses. Those cells were observed in the sub capsular and interfollicular regions, although no large tumor proliferation foci that would characterize metastasis were found.

#### Blood Leukocyte Count

The ANOVA for leukocyte count revealed no significant differences between groups (data not shown).

## Discussion

In this study, we aimed to verify if treating primary tumor with MB-PDT could present any influence on the growth and behavior of a second tumor. For this purpose, a model of subsequent implants of Ehrlich tumor was used. While the treatment of the solid tumor with MB-PDT caused necrosis in Group 1 mice, the footpad tumor growth curve analysis showed no significant difference among experimental groups 1, 2 or 3, during the 17-day measurement. It is possible to see a trend on Group 1 approaching the Group 3 group from day 13. The final mean diameter of the surgery group is below the others, but comparing only this final diameter, there was no statistically significant difference.

The diameter increases of the footpad inoculated with Ehrlich solid tumor is mainly due to the proliferation of tumor cells, but the inflammatory reaction is also involved in increasing tumor size. According to literature, PDT induces adaptive immunity against treated tumor and neoplastic cells that did not die during treatment. Tumor immunity is systemic, long-term and does not happen only on primary tumor. The response is observed against metastasis and recurrence of spontaneous tumors. This was also seen on experimental models with transplantable cells inoculated at distant site from the primary tumor. Treated fibro sarcomas MS-2 in mice with CASPc photo sensitizer and diode laser with an irradiation scheme similar to the present study [7]. There was no difference in the survival rate when compared to surgical treatment, but when animals received a second tumor challenge, surgically treated animals soon died while those treated with PDT survived for up to 100 days [8] used BALB/c mice and transplantable tumors (Colon 26 and EMT6). PDT was performed with HpD and Argon laser. These tumors produce lung metastases but those diminished after 10 days on PDT treated animals when compared to surgically treated mice. In the present experimental model, a difference among the growth curve of animals previously treated with MB-PDT, surgical excision or without treatment of the primary tumor was expected. The lack of difference in tumor size can be explained by differences of inflammatory response; thus, tumor proliferation and necrosis. Although tumor growth curve did not differ between groups, the morphometric analysis showed significant differences on the VF of footpad cellular components between surgically treated animals and animals treated with MB-PDT or without treatment of the primary tumor, as described in literature [7-9].

Surgically treated animals had higher tumor proliferation, less inflammatory infiltrate and a minor production of tumor necrosis. These results indicate that animals treated with surgical excision of the primary tumor did not develop acute inflammation and the activation of innate immune system like that produced by PDT. On surgically treated animals there was no induction of adaptive immune response against the treated tumor; therefore, tumor pro-

liferation was larger and occurs without inducing important inflammation, unlike that observed on animals treated with PDT.

Relative spleen weight showed a significant difference between groups. Values were higher in MB-PDT and control groups, which may indicate a more stimulated immune system in those animals. Histopathology showed hyperplasia of white pulp, confirming the suspicion of a greater immune stimulation in these groups. These results corroborate with Koberlik et al [4] who demonstrated the role of spleen cells in the induction of tumor immunity produced by PDT through transferring spleen cells from animals previously treated with PDT to immunosuppressed animals. In these animals, the PDT did not promote healing; however, when receiving spleen cells, the cure rates were back to the levels of the immune competent animals. The analysis of the left popliteal lymph node, the lymphoid organ, revealed no significant statistical difference between relative weights on experimental groups. However, the significance level of  $p = 0.0622$  found is quite close to the value considered to show significant difference among groups. Kousis et al. [10] found similar results when assessing by flow cytometry the cellular components of lymph node from animals treated with PDT. After PDT, the population of CD8<sup>+</sup> T lymphocytes in the regional lymph node was higher than in animals treated with surgical excision of the tumor.

Histopathological analysis showed no differences on lymph node architecture within different groups. The presence of cells with phenotypic characteristics of the Ehrlich tumor were observed occupying the sub capsular space in all animals inoculated on the footpad, as noted earlier by Dagli et al. [11]. The results obtained clearly show that animals treated with surgical excision of the primary Ehrlich tumor, when challenged with a new inoculation of tumor cells, present different local and systemic immune responses than animals treated with PDT or not treated. The similarity of responses between animals treated with MB-PDT and those receiving no treatment of the primary tumor can be explained by the fact that the Ehrlich tumor is immunogenic. As reported by Guerra (1983) [12] when animals bearing Ehrlich solid tumor after 12 days of inoculation receive a second tumor challenge, there is no progression of secondary tumor. Here, animals were treated after 9 days of primary tumor progression. In animals treated with surgical excision, the immune stimulation ceased before the 12 days required to induce immunity; therefore, we observed growth of secondary tumor and a poor activation of the immune system (seen in the analysis of lymphoid organs and morphometry).

Animals treated with MB-PDT had a similar response to untreated animals. When compared to surgically treated animals, they showed less tumor proliferation and more inflammation and necrosis of secondary tumor, in addition to greater systemic response

seen in the analysis of lymphoid organs. In conclusion, the present study demonstrates that applying MB-PDT to a primary Ehrlich tumor leads to a different inflammatory and cell death behavior of a second Ehrlich tumor implant, possibly due to activation of adaptive immune system.

These results led us to think that MB-PDT can possibly impact the development of micro metastatic or metastatic growth in a variety of tumors. Therefore, biotechnological applications of MB-PDT, mainly for the production of cancer vaccines, are currently under investigation.

## References

1. Castano AP, Demidova TN, Hamblin MR (2004) Mechanisms in photodynamic therapy: part one - photosensitizers, photochemistry and cellular localization. *Photodiagnosis Photodyn Ther* 1: 279-293.
2. Tardivo JP, Del Giglio A, De Oliveira Cs, Gabrielli Ds, Junqueira Hc, et al. (2005) Methylene blue in photodynamic therapy: From basic mechanisms to clinical applications. *Photodiagnosis Photodyn Ther* 2: 175-191.
3. Gomer CJ, Ferrario A, Murphree AL (1987) The effect of localized porphyrin photodynamic therapy on the induction of tumour metastasis. *Brit. J. Cancer* 56: 27-32.
4. Korblick M (1996) Induction of Tumor Immunity by Photodynamic Therapy. *J. Clin Laser Med & Surg* 14: 329-334.
5. Castano AP, Mroz P, Hamblin MR (2006) Photodynamic therapy and antitumor immunity. *Nat Rev Cancer* 6: 535-545.
6. Weibel WR, Kistler GS, Scherle WF (1966) Practical stereological methods for morphometric cytology. *J. Cell Biol* 30: 23-38.
7. Cubeddu R, Canti G, Musolino M, Pifferi A, Taroni P, et al. (1996) In vivo absorption spectrum of disulphonated aluminium phthalocyanine in a murine tumour 16 model. *J. Photochem Photobiol* 34: 229-235.
8. Kabingu E, Vaughan L, Owczarczak B, Ramsey KD, Gollnick SO (2007) CD8<sup>+</sup> T cell-mediated control of distant tumours following local photodynamic therapy is independent of CD4<sup>+</sup> T cells and dependent on natural killer cells. *Brit J Cancer* 96: 1839-1848.
9. Calin MA, Parasca SV (2006) Photodynamic therapy in oncology. *J. Optoelectr Adv Mat* 8: 1173-1179.
10. Kousis PC, Henderson BW, Maier PG, Gollnick SO (2007) Photodynamic therapy enhancement of antitumor immunity is regulated by neutrophils. *Cancer Res* 67: 10501-10510.
11. Dagli, Zaidan ML, Guerra, Luiz, Saldiva, et al. (1992) An experimental study on the lymphatic dissemination of the solid Ehrlich tumor in mice. *Braz J Vet Res and a Sci* 29: 97-103.
12. Guerra JL (1983) Aspectos do processo inflamatório em camundongos portadores de tumor de Ehrlich. 79 f. Tese (Doutorado em Patologia)-Faculdade de Medicina Veterinária e Zootecnia, Universidade de São Paulo, São Paulo.