

## Case Report

# Cutaneous Sarcoidosis Presenting as Pyoderma Gangrenosum-like Ulcers

Tyler Geers<sup>1\*</sup>, Jyoti Burruss<sup>2</sup>, Janine C. Malone<sup>2</sup>, Courtney R. Schadt<sup>2</sup>

<sup>1</sup>University of Louisville, School of Medicine, Louisville, USA

<sup>2</sup>University of Louisville, School of Medicine, Department of Internal Medicine, Division of Dermatology, Louisville, USA

**\*Corresponding Author:** Tyler Geers, University of Louisville School of Medicine, 323 E Chestnut St, Louisville, USA, KY 40202, Tel: +502-424-8696; E-mail: t0geer01@louisville.edu

**Citation:** Geers T, Burruss J, Malone JC, Schadt CR (2017) Cutaneous Sarcoidosis Presenting as Pyoderma Gangrenosum-like Ulcers. Clin Expt Der Therapies 2017: CEDT-117. DOI: 10.29011/2575-8268/100017

**Received Date:** 17 February, 2017; **Accepted Date:** 24 March, 2017; **Published Date:** 30 March, 2017

### Abstract

Sarcoidosis is a multisystem inflammatory disorder characterized by the accumulation of noncaseating epithelioid granulomas resulting in a variety of clinical manifestations, including skin lesions. We describe a unique case of a patient presenting with ulcerative sarcoid of the lower extremities clinically mimicking pyoderma gangrenosum. This case highlights a less common presenting clinical variant of cutaneous sarcoidosis and emphasizes the need to biopsy suspected pyoderma gangrenosum, as this is a diagnosis of exclusion.

### Introduction

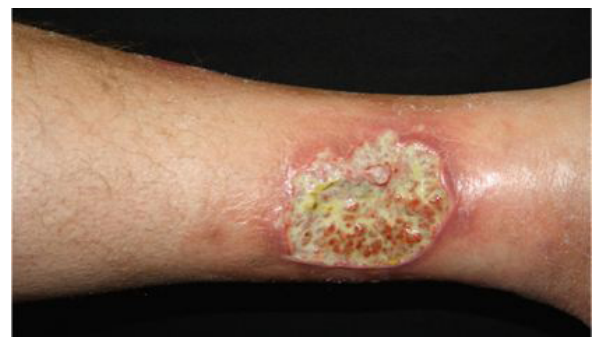Sarcoidosis is a multisystem disorder characterized by accumulation of lymphocytes and mononuclear phagocytes resulting in formation of noncaseating epithelioid granulomas. It can have a wide variety of clinical manifestations in the skin, including reddish brown to purple papules and plaques and subcutaneous nodules<sup>1</sup>. Herein, we describe a case of cutaneous sarcoidosis presenting as facial plaques and less frequently pyoderma gangrenosum-like leg ulcers. Pyoderma gangrenosum (PG), a diagnosis of exclusion, is a neutrophilic dermatosis characterized by painful ulcers often found on the lower extremities and in association with systemic illnesses, such as inflammatory bowel disease, rheumatoid arthritis, and hematologic malignancies<sup>2</sup>. This case not only illustrates a unique case of sarcoid with both multiple and an unusual clinical presentation, but also supports the need to always rule out other diagnoses before diagnosing PG.

### Report of a Case

A 66-year-old gentleman presented with progressive, painful ulcers on his lower legs for three years. The largest ulcer on his left pretibial region had developed over five months. The ulcers began as pustules with rapid development to ulcers. Failed treatments included chlorhexidine, trimethoprim-sulfamethoxazole, amoxicil-

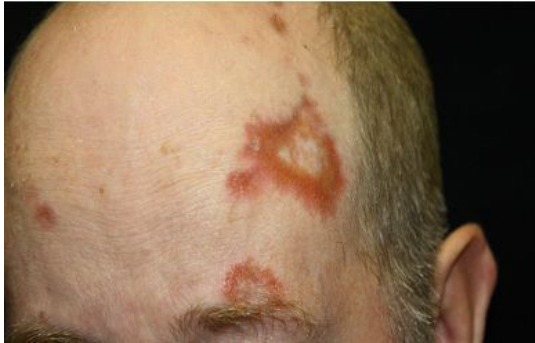lin, and mupirocin. The patient had a history of non-rheumatoid arthritis and denied a history of inflammatory bowel disease or malignancy. He had an otherwise unremarkable review of systems. He also had plaques on the face and forehead that were minimally symptomatic and present for years.

Physical examination revealed multiple 1-6cm ulcers with granulation tissue and rolled borders on the legs, the largest on the left medial distal leg (Figure 1a).



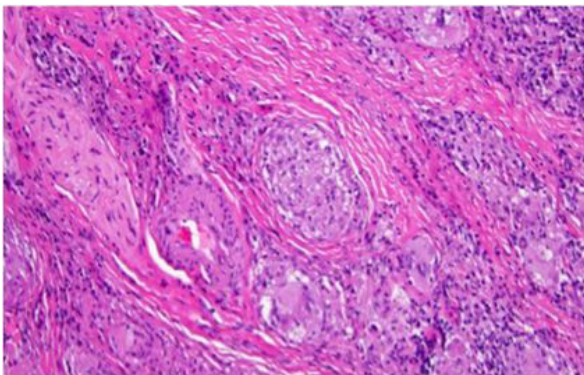
**Figure 1a:** Left medial distal leg

He also had multiple indurated dermal plaques with a reddish-brown hue on the face and frontal scalp (Figure 1b).



**Figure 1b:** Left frontal scalp.

Biopsies of the leg and forehead showed similar findings: features of granulomatous dermatitis with well-formed granulomas not associated with well-developed necrobiosis, a pattern consistent with sarcoidosis (Figure 1c). PAS and Fite stains were negative for fungal forms and mycobacteria, respectively. Tissue cultures for atypical mycobacteria, bacteria, and fungi were negative. Additional evaluation included a normal CBC, CMP, ACE level, chest x-ray, and pulmonary function studies. The patient was started on hydroxychloroquine for cutaneous sarcoidosis. However, he has since been lost to follow up.



**Figure 1c:** Biopsy of leg: 200X H&E, well-formed sarcoidal granulomas present within the dermis

## Discussion

Sarcoidosis is a multisystem inflammatory disorder characterized by the accumulation of noncaseating epithelioid granulomas. Cutaneous manifestations, including papules, plaques, and nodules, are present in up to 25% of cases [1]. Sarcoidosis presenting as ulcers mimicking PG, however, is a rare clinical variant. PG is a neutrophilic dermatosis commonly associated with systemic illness [2], and histopathologic evaluation to rule out other diagnoses and guide appropriate therapy.

Current treatment of cutaneous sarcoidosis is difficult given high rates of local recurrence. The most commonly accepted

therapies include corticosteroids, methotrexate, and hydroxychloroquine. Other treatment options include tetracyclines and adalimumab [3]. Adalimumab is a monoclonal antibody with anti-TNF-alpha activity, a cytokine with an active role in formation and persistence of granulomatous disease. Adalimumab has been found to be effective in refractory sarcoidosis, including a patient with ulcerative sarcoidosis who failed hydroxychloroquine and methotrexate [4]. Minocycline's success in treatment is thought to be secondary to its anti-inflammatory properties, including down-regulation of IL-2 and matrix metalloproteases [3]. In one clinical trial involving 12 patients with cutaneous sarcoidosis receiving minocycline, full remission was observed over a 12-month treatment period and 2 year follow up in 8 patients [5]. Unfortunately, the patient described in this report has been lost to follow up, so efficacy of prescribed hydroxychloroquine cannot be determined.

Ulcerative sarcoid is an uncommon manifestation of sarcoidosis with approximately 1 percent of Caucasians developing ulcerative disease. Out of 147 patients with known sarcoidosis retrospectively evaluated by Yoo et. al., only 7 demonstrated features of ulcerative sarcoid [6]. Of those with cutaneous ulceration, the majority of patients also have systemic findings of sarcoidosis [7,8]. Noileset. al. reported two patients with known sarcoidosis that developed ulcerative sarcoid with atypical histological features that included necrotizing granulomas, emphasizing that a lack of classical histopathologic features should not rule out a diagnosis of sarcoidosis [8]. Another patient reported by Hunt et. al. developed painful ulcers within erythematous papules and plaques on her anterior lower legs, and was found to have prominent hilar adenopathy on chest x-ray [7]. While ulcerative sarcoid is a rare cutaneous manifestation of the disease, ulcerative sarcoid mimicking PG is even rarer, with our case being the first reported in the literature to our knowledge.

This case highlights a patient with Cutaneous sarcoid presenting with multiple clinical morphologies, including PG-like leg ulcerations. In addition, this report emphasizes the importance of histo-pathologic evaluation in determining the etiology of an ulcerative dermatosis mimicking PG.

## References

1. English JC, Patel PJ, Greer KE (2001) Sarcoidosis. J Am Acad Dermatol 44:725-743; quiz 744-726.
2. Ahronowitz I, Harp J, Shinkai K (2012) Etiology and management of pyoderma gangrenosum: a comprehensive review. Am J Clin Dermatol 13: 191-211.
3. Doherty CB, Rosen T (2008) Evidence-based therapy for cutaneous sarcoidosis. Drugs 68: 1361-1383.
4. Philips MA, Lynch J, Azmi FH (2005) Ulcerative cutaneous sarcoidosis responding to adalimumab. J Am Acad Dermatol 53: 917.

5. Bachelez H, Senet P, Cadranet J, Kaoukhov A, Dubertret L (2001) The use of tetracyclines for the treatment of sarcoidosis. Arch Dermatol 137: 69-73.
6. Yoo SS, Mimouni D, Nikolskaia OV, Kouba DJ, Sauder DN, et al. (2004) Clinicopathologic features of ulcerative-atrophic sarcoidosis. Int J Dermatol, 43: 108-112.
7. Hunt RD, Gonzalez ME, Robinson M, Meehan SA, Franks AG, Jr. (2012) Ulcerative sarcoidosis. Dermatol Online J, 18: 29.
8. Noiles K, Beleznyay K, Crawford RI, Au S (2013) Sarcoidosis can present with necrotizing granulomas histologically: two cases of ulcerated sarcoidosis and review of the literature. J Cutan Med Surg, 17: 377-383.