

Case Report

Umeda A, et al. Ann Case Rep 2017: J121.

DOI: 10.29011/2574-7754/100021

Contradictory Results between T-Spot, Tb and Qft-3g in Patients with Respiratory Symptoms

Akira Umeda¹, Tateki Yamane¹, Yasushi Inoue¹, Kazumi Nishio², William M. Stauffer³

¹Department of Internal Medicine, International University of Health and Welfare (IUHW) Shioya Hospital, Yaita-City, Japan

²Department of Internal Medicine, Kawasaki Municipal Ida Hospital, Kawasaki-City, Japan

³Departments of Medicine and Pediatrics, Division of Infectious Diseases and international Medicine, University of Minnesota, Minneapolis, MN, USA

***Corresponding author:** Akira Umeda, Department of Internal Medicine, IUHW Shioya Hospital. Tomita 77, Yaita-City, Tochigi 329-2145, Japan, Tel: +81 287441155, Fax: + 81 287439822, E-mail: umeda@iuhw.ac.jp

Citation: Akira U, Yamane T, Inoue Y, Nishio K, Stauffer WM (2017) Contradictory Results between T-Spot.Tb and Qft-3g in Patients with Respiratory Symptoms. Ann Case Rep 2016: G121. DOI: 10.29011/2574-7754/100021

Received Date: 03 November, 2016; **Accepted Date:** 22 November, 2016; **Published Date:** 28 November, 2016

Abstract

A 60-year-old male presented with cough and fever (case 1), and a 77-year-old female patient with hemoptysis (case 2) were admitted to IUHW Shioya Hospital. Interferon gamma release assay (IGRA: QFT-3G and T-SPOT.TB) were both performed on each patient; the QFT-3G was positive and T-SPOT.TB was negative in both cases despite different final diagnosis. While case 1 was determined to have active tuberculosis, in case 2 active tuberculosis was eliminated as the diagnosis. The contradictory results in these patients should serve as a reminder to clinicians that they should not rely on the results of IGRA testing for the diagnosis of active tuberculosis.

Keywords: Interferon Gamma Release Assay; Negative; Tuberculosis; T-SPOT; QFT

Introduction

Interferon-Gamma Release Assays (IGRAs) have been advocated for diagnose of active Tuberculosis (TB) infection and latent TB infection (LTBI) [1-3]. Two types of IGRAs (QFT-3G and T-SPOT.TB) are currently available in Japan. The sensitivity and specificity have been reported to be 0.70-0.93 and 0.79-0.99 for QFT-3G, and 0.81-0.98 and 0.59-0.99 for T-SPOT.TB, respectively [1-3]. In low- and middle-income countries, where there is a high pre-test probability of TB, it was reported that neither the Tuberculin Skin Test (TST) nor IGRAs have value for predicting active TB diagnosis in adults, especially in the context of HIV coinfection [4]. In Japan, QFT-3G was initially approved for use in the public insurance system for the diagnosis of active or latent TB infection in 2009, and the T-SPOT.TB was subsequently approved in 2012.

We report 2 patients with respiratory symptoms, both of whom had a positive QFT-3G and a negative T-SPOT.TB. One patient had active tuberculosis, the second did not. These contradictory results in an intermediate pre-test probability setting should be a cautionary warning in relying on the results of IGRA testing in the diagnosis of active tuberculosis [5].

Case Report

Case 1

A 60-year-old Japanese male patient with a cough, decreased appetite, weight loss, and fever (> 40°C) was admitted to International University of Health and Welfare (IUHW) Shioya Hospital in July, 2015. He had a past medical history of a cerebral infarction, hypertension, hyperlipidemia, and perianal abscess formation with a resulting diversion and stoma. The perianal abscess was not due to TB. His chest CT showed bilateral multiple inflammatory shadows with prominent bronchiectasis (Fig. 1a).

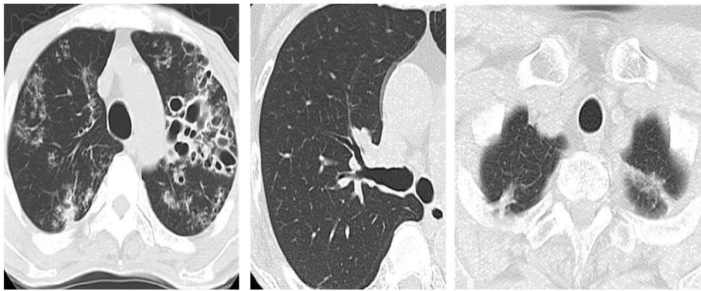


Fig. 1: Chest CT.

- (a) Case 1: Prominent bronchiectasis mainly in the left lung and inflammatory shadows in the bilateral lung fields are seen.
- (b) Case 2: Bronchiectasis in the right upper lung field is seen.
- (c) Case 2: Inflammatory shadows in the bilateral upper lung fields are seen.

Blood tests revealed leukocytosis (24,000/ μ l) with the following differential (Neutrophils 92.8%, Lymphocytes 2.4%, Monocytes 4.7%, Eosinophils 0%, Basophils 0.1%). His HIV antibody was negative, CRP was elevated (23.07 mg/dl). Results of IGRAs (QFT-3G and T-SPOT.TB) and TST were: positive, negative and positive (0x0/20x10), respectively (Table 1).

Case	QFT-3G	T-SPOT.TB	TST
1	Positive (0.4, 2.22, 2.77)	Negative (0, 0, 2, 478)	Positive (0x0/20x12)
2	Positive (0.56, 2.08, >10)	Negative (0, 1, 3, 291)	Positive (0x0/12x12)

Table 1: Results of IGRAs (QFT-3G and T-SPOT.TB) and TST were: positive, negative and positive (0x0/20x10), respectively.

Results of interferon-gamma reaction assays (IGRAs, underlined) and Tuberculin Skin Tests (TST). The data of QFT-3G parenthesis (IU/ml): negative control (Nill), stimulation with three Mycobacterium tuberculosis specific antigens (ESAT-6,CFT-10, and TB7.7) - Nill, and positive control (stimulation with phytohemagglutinin) - Nill. The data of T-SPOT.TB parenthesis (spots): negative control, stimulation with EAST-6, stimulation with CPT-10, and positive control (stimulation with phytohemagglutinin).

Sputum yielded negative Acid Fast Bacilli (afb) staining for TB. Gastric aspirate yielded a positive afb smear (gaffky 4) with a subsequent positive Polymerase Chain Reaction (PCR) for TB. This patient was treated with a standard 4 drug TB regimen of isoniazid, rifampicin, ethambutol, and pyrazinamide with resolution of infection.

Case 2

A 77-year-old Japanese female patient was admitted to

IUHW Shioya Hospital because of hemoptysis approximately 40 ml/d, for 3 days in March, 2016). She had been treated with anti-tubercular drugs for 6 months 15 years prior because of suspected pulmonary TB. Five days prior to the hemoptysis, the patient had developed respiratory tract symptoms including cough, sputum production, nasal discharge and a sore throat. Her chest CT showed bronchiectasis and old inflammatory shadows in bilateral upper lobes (Figure 1b,c). Blood test yielded elevated CRP levels (1.03 mg/dl) with normal white blood cell counts (5,040/ μ l) with decreased neutrophils population (Neutrophils 20.2%, Lymphocytes 62.5%, Monocytes 9.4%, Eosinophils 7.1%, Basophils 0.7%). Bronchoscopy was performed and redness on the lumen of right upper lobe bronchus and bleeding from left B4+5 were observed. Bronchoscopy samples were negative for afb staining, PCR for TB was negative. Gastric aspirate was also negative by afb and PCR. Results of IGRAs (QFT-3G, T-SPOT.TB) and TST were: positive, negative and positive, respectively (Table 1). Additional bacterial and fungal evaluation yielded no significant pathogens. She was treated with antibiotics (garenoxacin 400mg/d for 1 week and then levofloxacin 500mg/d for 1 week) and hemoptysis resolved. She did not develop any further symptoms of tuberculosis and none of her mycobacterial cultures grew.

Discussion

Although IGRAs have not been accepted as part of the criterion for diagnosis of active TB, it is common in Japan to use IGRA results to help in ruling in, or ruling out TB. These cases, which demonstrate contradictory results in one patient with and one without TB, highlight the pitfalls of over-reliance on the IGRA when diagnosing active TB. The hazard is over treatment for TB in the case of a false positive IGRA, or ruling out the diagnosis in a patient with a false negative test [6]. False negative tests are more likely in high pre-test probability setting (e.g., high prevalence countries), and false positives in low probability settings. Japan is currently a country with intermediate TB incidence (18 per 100,000 populations) [5].

There may be many explanations why these results may differ in the same patient. First is to understand the tests are methodologically different. While the combination of three Mycobacterium tuberculosis specific antigens (ESAT-6, CFT-10, and TB7.7) is used for the stimulation to the samples in QFT-3G, the separate stimulation with ESAT-6 or CFT-10 is used in T-SPOT.TB. While the total interferon-gamma concentration is measured in QFT-3G, the number of spots is counted in T-SPOT.TB. In addition, the effect of granulocytes agglutination detergent: T-Cell Xtend (Xtend) used in T-SPOT.TB might be important for the discrepant results. Second, the tests must be performed in a timely manner and delay or preservation may affect results. According to the T-SPOT.TB

manufacturer's instruction, the stimulation by ESAT-6 or CFT-10 should be started within 8 hours after the blood sampling from patients. If the reactions are started at 8 to 32 hours after the blood sampling, the instruction guides to add Xtend to the samples. Xtend has been reported to allow the storage of whole blood for up to 33 hours without an impact on the results of the T-Spot.TB test [7]. Dr. Fukushima described the sensitivity of T-Spot.TB was lower than previously reported when Xtend was added to the samples [8]. It is possible that the previously reported sensitivity for T-SPOT.TB was obtained from the data measured within 8 hours from blood sampling. The effects of Xtend have not been fully investigated or reported. Third, a positive IGRA may reflect past infection simply including LTBI and therefore may confound a current diagnosis since a substantial number of people will be positive at baseline regardless of current symptoms. Lastly there are data indicating that IGRA testing in persons with current TB disease may not be accurate, particularly under certain circumstances (e.g., age of older than 60 years and female sex for QFT-3G, Malay for T-SPOT.TB, immunocompromised and Indian for both) [4,9]. These data did not explain why case 1, an active TB patient, not immunocompromised 60-year-old Japanese male, showed a false negative result of T-SPOT.TB only.

These two patients should remind physicians not to rely on the results of IGRAs for the diagnosis of active tuberculosis. Already established diagnosing methods (staining, culture, and PCR) cannot be replaced with IGRAs.

Conflict of interests

The authors have no conflict of interest to declare.

References

1. Pai M, Zwerling A, Menzie D (2008) Contradictory Results between T-Spot.Tb and Qft-3g in Patients with Respiratory Symptoms, Systematic review: T-Cell-based Assays for the Diagnosis of Latent Tuberculosis Infection: An Update. *Ann Intern Med* 149: 177-84.
2. Sester M, Sotgiu G, Lange C, Giehl C, Girardi E, Migliori GB, et al (2011) Contradictory Results between T-Spot.Tb and Qft-3g in Patients with Respiratory Symptoms, Interferon- γ release assays for the diagnosis of active tuberculosis: a systematic review and meta-analysis. *Eur Respir J* 37: 100-111.
3. Diel R, Loddenkemper R, Nienhaus A (2010) Contradictory Results between T-Spot.Tb and Qft-3g in Patients with Respiratory Symptoms, Evidence-based comparison of commercial interferon- γ release assays for detecting active TB. *Chest* 137: 952-68.
4. Metcalfe JZ, Everett CK, Steingart KR, Cattamanchi A, Huang L, Hopewell PC, Pai M (2011) Contradictory Results between T-Spot.Tb and Qft-3g in Patients with Respiratory Symptoms, Interferon- γ release assays for active pulmonary tuberculosis diagnosis in adults in low- and middle-income countries: systematic review and meta-analysis. *J Infect Dis* 204: 1120-1129.
5. Key TB indicators for individual countries and territories (2015) WHO regions and the world. In: *Global tuberculosis report, 20th Edition*, World Health Organization: 155-92.
6. Centers for Disease Control and Prevention (2015) Interferon-Gamma Release Assays (IGRAs) - Blood Tests for TB Infection.
7. Wang SH, Stew SS, Cyktor J, Carruthers B, Turner J, Restrepo BI (2012) Contradictory Results between T-Spot.Tb and Qft-3g in Patients with Respiratory Symptoms, Validation of increased blood storage times with the T-SPOT.TB assay with T-Cell Xtend reagent in individuals with different tuberculosis risk factors. *J Clin Microbiol* 50: 2469-2471.
8. Fukushima K (2016) Contradictory Results between T-Spot.Tb and Qft-3g in Patients with Respiratory Symptoms, Progress and the present situation of diagnostic examinations in tubercular infection. *Respiratory Medicine* 29: 57-64.
9. Chee CB, Gan SH, Khinmar KW, Barkham TM, Koh CK, Liang S, Wang YT (2008) Contradictory results between T-Spot.Tb and Qft-3g in Patients with Respiratory Symptoms, Comparison of sensitivities of two commercial gamma interferon release assays for pulmonary tuberculosis. *J Clin Microbiol* 46: 1935-1940.