

Brief Report

Where the Sun Does Polish Excessively

Ebtisam Elghblawi^{1*} and Cliff Rosendahl²

¹STJ Hospital, Hay Alandalas, Tripoli, Libya

²The University of Queensland, Australia

***Corresponding author:** Ebtisam Elghblawi, STJ Hospital, Hay Alandalas, Tripoli, Libiya, Tel: +218 913201315; E-mail: Ebtisamya@yahoo.com

Citation: Elghblawi E, Rosendahl C (2016) Where the Sun Does Polish Excessively. Gavin J Dermatol Res Ther 2016: 1-2.

Received: 22 February, 2016; **Accepted:** 15 March, 2016; **Published:** 29 March, 2016

Introduction

While malignant tissue disobeyed natural laws and grows slowly and expands to erode. In most instances, patients are unaware of that and ignore it to keep the momentum. In here a case of a lady who thought it is a trivial skin allergy that kept on and off and she was applying OTC steroids which had worked for some time is presented.

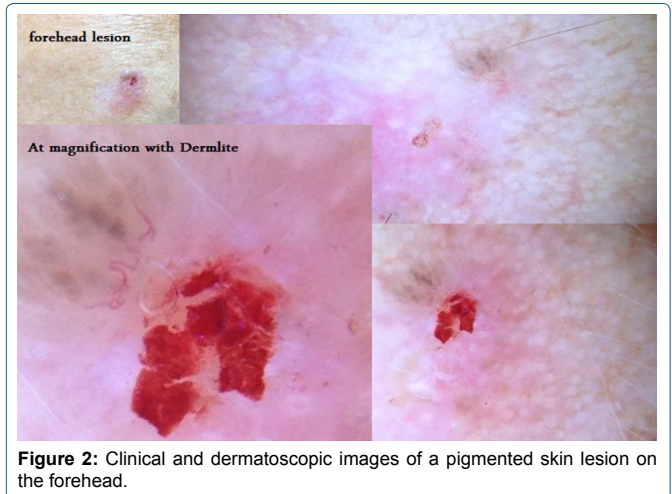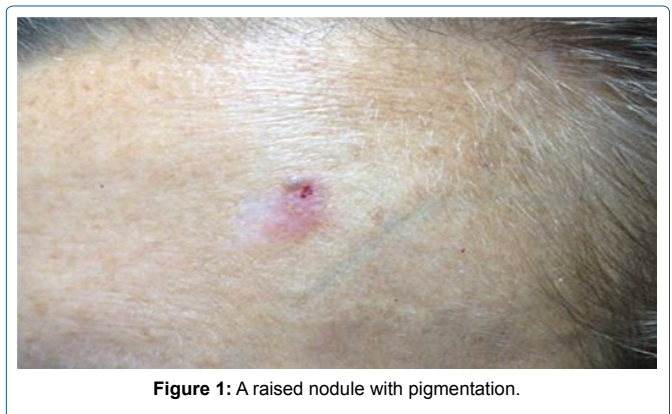
The only clue in such cases is a dermatoscopic examination.

Case Report

A fair skin type-II 46-years American lady with obviously visible chronic sun damaged skin, presented with a red none itchy annoying skin lesion with a scab on the forehead (Figure 1). She had no other lesions of concern and no past history or family history of skin cancer. Her only main worrying is the aesthetic look on her forehead. The patient expressed been given a cryocautery four years back in the USA for a lesion she does not know on the forehead. On learning of this a thinking of a possibility of (Solar or Actinic Keratosis) SK/AK, where from the history of cumulative sun exposure and the skin lesion that can be treated as such. She said after having the cryocautery, the lesion never healed up properly and left her with a scab with redness that irritate her from time to time. It is not itchy though and not painful. By naked eye examination, incidentally, a small nodule with barely brownish pigmentation can be appreciated at the superior margin of the lesion which could confuse with melanoma for anyone who is not expertise (Figure 1).

Examination of forehead lesion was performed by dermlite II pro HR dermatoscope, revealed pinkish white structureless area with small focal pigmented lesion, few gray clods and a typical ulceration and some grey line of pigmented BCC (Figure 2).

Treatment options have been explained to her. However the patient was opposing and did not believe it could a cancer at all.



That left with only one option where a 6 mm punch biopsy was performed to enable taking out the maximum part of the lesion including the hemorrhage area with the surrounding margin, to give the pathologist a decent bit of tissue to examine and explore thoroughly.

The biopsy signed out revealed a superficial BCC as predicted. Even the report of the pathologist state that the

margin is free which would explain the mass had been fully removed however, in such cases we remain skeptical as in fact it is hard sometimes to be certain that margin is all clear, and would mandate Mohs surgery to ensure that. This facility is not available in Libya as the USA does. The lady is aware of that and stated that she will look after it abroad as she exclaimed.

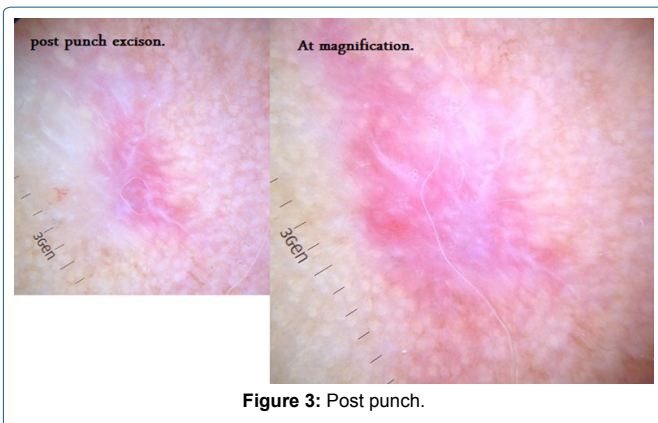
Discussion

BCC is well known to grow slowly and infiltrate locally, and it's radiosensitive and thus can be applied in feeble elderly patients if surgery is contraindicated or rejected. According to the pathology report type she is ideal candidate for Aldara cream (Imiquimod) for a better cosmetic result.

The question why the diagnosis has not been critically reviewed or explained to the patient by the clinician who examined four years back and treated on what basis since she don't know at all.

However knowing the fact she has an unknown lesion since four years would make it fall in the category of recurrent BCC and would means an elliptical excisions which she declined already.

Post excision dermatoscope examination revealed pink strawberry structureless pattern area with white lines which could explain the consistent scar tissue from previous treatment (cryocautery) and that would not possibly rule out the removal of all mass (Figure 3).



Practice Points and Conclusion

- Examine your patients according to a well-designed protocol ensuring they are informed about the detail.
- The diagnosis of BCC can be clinical in many instance, however this case as had a raised nodule with pigmentation at the superior margin might confuse for MM.
- Most skin cancers of the head and neck are Non-Melanoma Skin Cancers (NMSCs). Basal cell carcinoma and squamous cell carcinoma are the most frequent types of NMSCs.
- Avoidance of sunburns and acute sun damage, sunscreen protection, and early identification and evaluation of suspicious lesions remain the first line of defence against skin cancers.
- Treatment decision should be based solely on what is best for the patient irrespective sometimes of the cosmetic outcome in such cases.
- Treatment options including wide local excision, Mohs surgery, sentinel lymph node biopsy, and cervical lymphadenectomy and adjuvant radiation when warranted offer a high cure rate, while balancing excellent functional and cosmetic outcomes.
- Mohs examination for 48 hours to ensure all tumours has been removed.
- Hole of punch and scar cannot be mask or concealed.
- Solar or Ultraviolet (UV) light exposure is the most common carcinogen.
- Sunscreen is protective, tanning devices are causative, and the routine screening of high-risk individuals is preventative.
- Insist on biopsy to confirm your suspicion.
- Refer to plastic surgeon when patient concern about aesthetic impact as in this case main worrying.