

## Case Report

## When Colonoscopy goes Wrong: A Rare Case of Splenic Rupture

Roger Christopher Gill\*, Fatima Mannan, Adeel Samad, Amir H. Shariff

Department of Surgery, The Aga Khan University Hospital, Karachi, Pakistan

**\*Corresponding author:** Roger Christopher Gill, Trauma Fellow, Department of Surgery, The Aga Khan University Hospital, Karachi, Pakistan. Tel: +923009234726; Email: christo214@gmail.com

**Citation:** Gill RC, Mannan F, Samad A, Shariff AH (2018) When Colonoscopy goes Wrong: A Rare Case of Splenic Rupture. Arch Surg Clin Case Rep: ASCR-108. DOI: 10.29011/ASCR-108/100008

**Received Date:** 09 August, 2018; **Accepted Date:** 27 August, 2018; **Published Date:** 04 September, 2018

## Summary

An elderly gentleman presented with a history of altered bowel habits with significant weight loss without any family history of cancers. He underwent Colonoscopy which was non-specific. Post procedure he became hemodynamically unstable and workup revealed a drop-in haemoglobin level. He had abdominal pain for which a CT scan was performed which revealed grade III splenic injury which was treated conservatively.

## Background

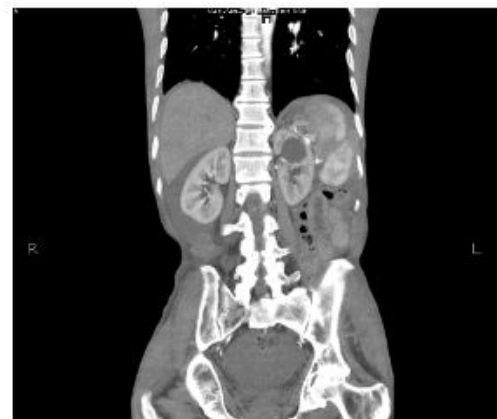Splenic rupture as a complication of colonoscopy is an extremely rare event. Many of these cases are of a minor trivial nature going un-noticed. However, some may have a significant injury leading to haemorrhage and requiring intervention. We present this case to highlight the importance of reducing loops and avoiding un-necessary manipulation if encountering difficulty in negotiating scope beyond acute turns like flexures. These injuries may be devastating and go unnoticed since the lumen of the intestine may not get compromised. It is always wise to withdraw scope and re start the procedure again at the same time involving more expert opinion and help. There is always a chance these finding may get missed at the time of the procedure and present late with some blame to the sedation being generously used during these procedures. Knowledge of such complications always helps in identifying these patients on time and promptly treating them to avoid mortality.

## Case Presentation

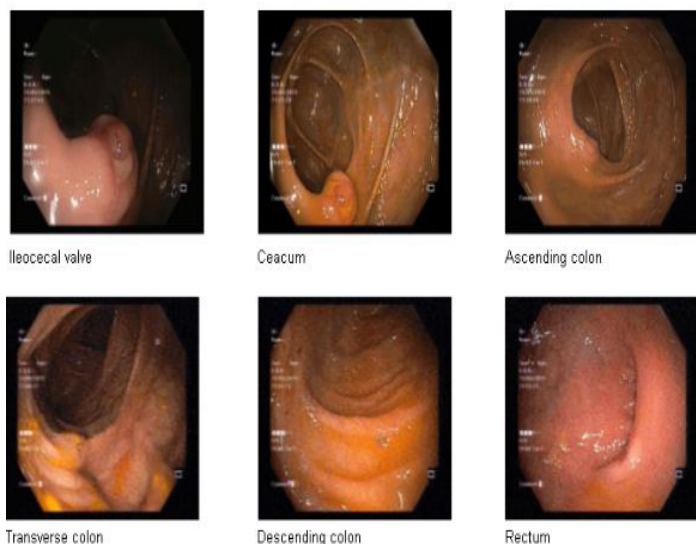
74-year-old gentleman presented to our facility with history of alteration in bowel habits with associated on and off bleeding per rectum and associated undocumented weight loss for over a year. He had not sought any treatment and investigations for these complaints in the past and was managing on his own without any

medications. Now the frequency of constipation was increasing day by day and he felt bloated and lacked the desire to eat. His examination revealed a thin built elderly gentleman with good functional class not requiring any assistance. Patient was fully oriented with time, place and person. At arrival his heart rate was around 65bpm, Blood Pressure of 105/64 mm Hg, Respiratory rate of 20 breaths per minute with O2 saturation of around 99%. His general physical examination was unremarkable. Chest was clear and Cardiovascular and CNS examination were within normal limits. On abdominal examination there were bilateral inguinal hernias visible with a positive cough impulse. On palpation the belly was soft, non-tender and there were no palpable masses or any abnormal visceromegaly felt. Keeping his age and history in mind a high suspicion of ruling out colonic malignancy was anticipated. His initial blood labs were sent which included complete blood counts, serum creatinine and electrolytes and coagulation profile the values of which have been mentioned in the investigation section. He initially underwent a Contrast enhanced CT Scan due to suspicion of malignancy and sub-acute intestinal obstruction which was unremarkable. Later a diagnostic Colonoscopy and upper GI endoscopy was planned to screen for malignancy and check the source of bleeding for iron deficiency anaemia. After appropriate bowel prep patient underwent both UGI endoscopy and Colonoscopy under conscious sedation. The UGI endoscopy revealed a superficial ulcer in the distal oesophagus with no evidence of bleeding. Colonoscopy was performed without any technical difficulty and the procedure was completed within 20 minutes. Colonoscopy revealed an ulcer at ileocecal valve (see figure 1) which was biopsied and internal haemorrhoids (Figure 2). Post procedure the patient started complaining of abdominal pain which was generalized without any guarding or rigidity on examination and his Gut sounds were sluggish. He had mild drop in his Blood pressures of around 106-60mm Hg and his heart rate was round 86 with normal saturations at room air and normal temperature.

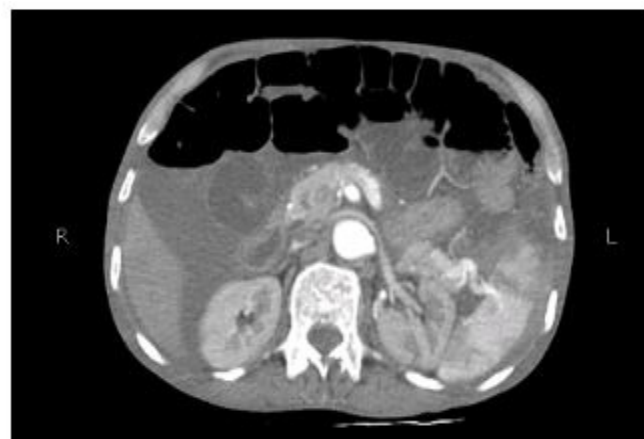Urine output was adequate. Blood labs were sent and they showed a drop in Hb from 10.7 to 6.8 g/dl. His coagulation profile sent again was normal. There was a high suspicion of bleed and blood products were arranged. Patient was shifted to special care unit for increased hemodynamic monitoring. Initially two litre boluses of normal saline was administered which improved his blood pressure. He was then taken for a CT scan of the abdomen and pelvis which revealed splenic laceration with peri splenic hematoma with haemo-peritoneum (See Figures 3&4). Once blood products were arranged he was transfused four units of packed red blood cells. Since the patient has grade III splenic injury with no evidence of contrast extravasation indicating active bleed. It was decided to pursue a conservative course. He stayed in special care unit for a few days and later shifted in ward.



**Figure 3:** Sagittal View CT scan abdomen and pelvis showing splenic laceration with peri splenic hematoma and high-density haemorrhagic ascites. Also seen is a benign cyst in the left kidney.



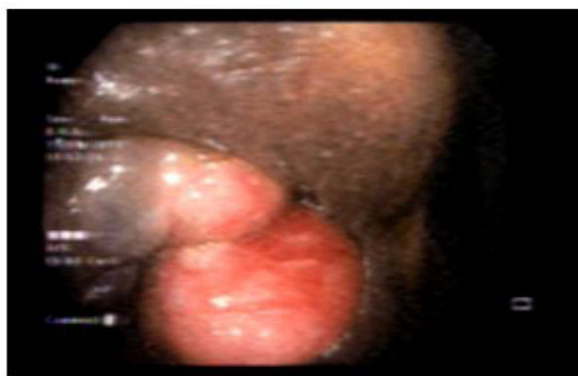**Figure 1:** Colonoscopy images normal rectum, descending, transverse and ascending colon with ulcer at the ileocecal valve which was biopsied



**Figure 4:** Contrast Enhanced CT Scan Cross-sectional View Showing Splenic Laceration with high density ascites indicative of haemorrhage with no evidence of active bleed.

## Outcome and Follow-Up

Patient was discharged after ten days of admission. After his CT scan revealed splenic laceration induced post colonoscopy which was responsible for bleeding within the abdominal cavity he was managed conservatively with frequent Hb monitoring and blood transfusions. The patient gradually recovered and at discharge was tolerating regular diet and was fully mobile. At his first follow up in clinic after a week the patient was remarkably improved, and he was advised to resume activities of daily living.



**Figure 2:** Image taken with colonoscope showing prolapsed haemorrhoids with visible mucosa from the anal verge.

## Discussion

Colonoscopy is a procedure commonly used for diagnostic and therapeutic purposes considered to be very safe [1]. The commonly reported complications are intraluminal bleeding (0.3% - 2.1%) and perforation (0.1% - 2.5%) [2]. Rare complications include pneumothorax, pneumomediastinum, appendicitis, retroperitoneal abscess; colonic volvulus and splenic rupture [3]. We present a case of splenic rupture following a diagnostic colonoscopy at our setup. Our literature search revealed slightly more than a hundred case reports on this complication which may be owing to the under reporting or bias towards the publication of severe cases [4].

Splenic rupture secondary to colonoscopy was first reported in 1974 by Wherry and Zehner [5]. It has an incidence of around 0.00005-0.017% and a mortality rate of 5 % [6]. It has higher incidence in females [7,8]. Although a rare complication, it can be potentially fatal. Hence it should be diagnosed promptly. Most patients with a colonoscopy-induced splenic rupture present with the typical symptoms of a trauma-induced splenic rupture within 24 hours of their colonoscopy [9]. However, some patients have presented up to 10 days later [10]. There is usually abdominal pain, which is generalized or localized to the left upper quadrant [11,12]. Pain may also be felt in left shoulder (Kehr's sign) [13]. Kehr's sign is believed to be due to the irritation of left diaphragm or splenic capsule distension [14]. It was reported to occur in up to 90% of the patients but was also reportedly present in 50% of uncomplicated colonoscopies, thereby limiting its usefulness [15,16]. Significant drop in haemoglobin and symptoms of drop in blood pressure can occur and should be taken as warning signs [17]. Abdominal distension is a common finding on abdominal exam [18,19].

It has been suggested that loop formation and excessive torqueing might induce significant stress over the spleno-colic attachments and trigger splenic surface avulsion [18,20,21]. Excessive traction to straighten the endoscope and entry into ileum to take biopsy have been suggested to increase traction on spleno-colic ligament [22]. Left lateral decubitus can reduce the probability of this complication by shifting the spleen to left and decreasing the opposing splenic and colonic tension [18,23]. Previous abdominal surgery has been associated with increased risk of this complication due to formation of strictures [19,24]. Splenomegaly, neoplasms and inflammation are also been associated with increased risk of this complication [25].

Splenic rupture should always be considered as a possible complication following colonoscopy. It is a clinical diagnosis and high index of suspicion is needed to establish diagnosis [9]. Ultrasound and CT scan can be used to confirm the diagnosis however CT scan remains the gold standard [26]. CT scan is considered

the most sensitive modality for confirmatory diagnosis. CT scan is also indicated to be the best management option, as it is highly accurate for the detection of splenic injury, and is able to delineate the extent of injury and hemoperitoneum, and differentiate between perisplenic clot and hemoperitoneum, which helped to determine the need for laparotomy [27]. The current helical and spiral scanning CT methods allow for a more precise delineation of organ fracture and intra- parenchymal vascular disruption [17].

The commonly used modes of management are splenectomy, splenic artery embolization and non-operative treatment. The treatment of choice indicated in most case reports is splenectomy. Conservative management with bed rest, hemodynamic monitoring, fluid replacement and IV antibiotics has also been reported successfully however it is associated with high rate of failure [24,28,29]. Embolization of splenic artery has been safe and effective in management of splenic rupture [30,31]. In our patient the conservative route was undertaken which he endured quiet well. The patient's histopathology yielded non-specific inflammation and was later discharged.

## Learning Points/Take Home Messages

- Splenic injury post colonoscopy can be fatal, and a high index of suspicion should be anticipated in difficult procedures including those with prior surgeries and with diseases of the spleen.
- Treatment following injury is based on patients' clinical condition and hemodynamic stability.
- All unstable patients and those with active evidence of intra-abdominal bleed should undergo emergent splenectomy.
- Stable patients and those with AST grade I to III splenic injury can safely undergo conservative management.

## References

1. Goitein D, Goitein O, Pikarski A (2004) Splenic rupture after colonoscopy. IMAJ-RAMAT GAN 6: 61-62.
2. Ha JF, Minchin D (2009) Splenic injury in colonoscopy: a review. International Journal of Surgery 7: 424-427.
3. Han SH, Lee JH, Kim SH (2015) Splenic rupture following colon polypectomy: a case report and review of literature. The Korean Journal of Gastroenterology 65: 123-126.
4. de Tejada AH, Giménez-Alvira L, Van den Brule E, Sánchez-Yuste R, Matallanos P, et al. (2014) Severe splenic rupture after colorectal endoscopic submucosal dissection. World Journal of Gastroenterology: WJG 20: 9618-9620.
5. Wherry D, Zehner H Jr (1974) Colonoscopy-fiberoptic endoscopic approach to the colon and polypectomy. The Medical annals of the District of Columbia 43: 189-192.

6. Zappa MA, Aiolfi A, Antonini I, Musolino CD, Porta A (2016) Splenic rupture following colonoscopy: case report and literature review. *International journal of surgery case reports* 21: 118-120.
7. Singla S, Keller D, Thirunavukarasu P, Tamandl D, Gupta S, et al. (2012) Splenic injury during colonoscopy-a complication that warrants urgent attention. *Journal of Gastrointestinal Surgery* 16: 1225-1234.
8. Smith LE (1976) Fiberoptic colonoscopy: complications of colonoscopy and polypectomy. *Diseases of the Colon & Rectum* 19: 407-412.
9. Chow MD, Shih RD (2013) Acute colonoscopy-induced splenic rupture presenting to the emergency department. *Case reports in emergency medicine* 2013.
10. Corcillo A, Aellen S, Zingg T, Bize P, Demartines N, et al. (2013) Endovascular treatment of active splenic bleeding after colonoscopy: a systematic review of the literature. *Cardiovascular and interventional radiology* 36: 1270-1279.
11. González-Soler R, Castro-Ortiz E, Lancho-Seco Á, García-Suárez C, Santos-Blanco E, et al. (2012) Splenic rupture following diagnostic colonoscopy. *Revista española de enfermedades digestivas: organo oficial de la Sociedad Española de Patología Digestiva* 104: 219-20.
12. Luebke T, Baldus SE, Holscher AH, Monig SP (2006) Splenic rupture: an unusual complication of colonoscopy: case report and review of the literature. *Surgical Laparoscopy Endoscopy & Percutaneous Techniques* 5: 351-354.
13. De Vries J, Ronnen H, Oomen A, Linskens R (2009) Splenic rupture following colonoscopy, a rare complication. *Neth J Med* 67: 230-233.
14. Rao KV, Beri GD, Sterling MJ, Salen G (2009) Splenic injury as a complication of colonoscopy: a case series. *The American journal of gastroenterology* 104: 1604.
15. Duarte CG (2008) Splenic rupture after colonoscopy. *The American journal of emergency medicine* 26: 117. e1-. e3.
16. Saad A, Rex DK (2008) Colonoscopy-induced splenic injury: report of 3 cases and literature review. *Digestive diseases and sciences* 53: 892-898.
17. Shankar S, Rowe S (2011) Splenic injury after colonoscopy: case report and review of literature. *The Ochsner Journal* 11: 276-281.
18. Guerra JF, San Francisco I, Pimentel F, Ibanez L (2008) Splenic rupture following colonoscopy. *World Journal of Gastroenterology: WJG* 14: 6410.
19. Al Alawi I, Gourlay R (2004) Rare complication of colonoscopy. *ANZ journal of surgery* 74: 605-606.
20. Janes SE, Cowan IA, Dijkstra B (2005) A life threatening complication after colonoscopy. *BMJ* 330: 889.
21. Espinal E, Hoak T, Porter J, Slezak F (1997) Splenic rupture from colonoscopy. *Surgical endoscopy* 11: 71-73.
22. Johnson C, Mader M, Edwards DM, Vesly T (2006) Splenic rupture following colonoscopy: two cases with CT findings. *Emergency radiology* 13: 47-49.
23. Holubar S, Dwivedi A, Eisendorfer J, Levine R, Strauss R (2007) Splenic rupture: an unusual complication of colonoscopy. *The American Surgeon* 73: 393-396.
24. Tsoraides SS, Gupta SK, Estes NC (2007) Splenic rupture after colonoscopy: case report and literature review. *Journal of Trauma and Acute Care Surgery* 62: 255-257.
25. Ahmed A, Eller PM, Schiffman FJ (1997) Splenic rupture: an unusual complication of colonoscopy. *American Journal of Gastroenterology* 92(7).
26. Olshaker JS, Deckleman C (1999) Delayed presentation of splenic rupture after colonoscopy. *Journal of Emergency Medicine* 17: 455-457.
27. Lahat E, Nevler A, Batumsky M, Shapiro R, Zmora O, et al. (2016) Diagnosis and management of splenic injury following colonoscopy: algorithm and case series. *Techniques in coloproctology* 20:163-169.
28. Köksal N, Uzun MA, Müftüoğlu T (2000) Hemodynamic stability is the most important factor in nonoperative management of blunt splenic trauma. *Ulusal travma dergisi= Turkish journal of trauma & emergency surgery: TJTES* 6: 275-280.
29. Tsugawa K, Koyanagi N, Hashizume M, Ayukawa K, Wada H, et al. (2002) New insight for management of blunt splenic trauma: significant differences between young and elderly. *Hepato-gastroenterology* 49: 1144-1149.
30. Parker WT, Edwards MA, Bittner IV JG, Mellinger JD (2008) Splenic hemorrhage: an unexpected complication after colonoscopy. *The American Surgeon* 74: 450.
31. Stein DF, Myaing M, Guillaume C (2002) Splenic rupture after colonoscopy treated by splenic artery embolization. *Gastrointestinal endoscopy* 55: 946-948.