

Research Article

Vascularized Transposition of the Ulnar Nerve in Entrapment Syndrome at the Elbow

Messina Antonino*

Former Chief Orthopaedic Surgeon and Founder of the Hand Surgery Centre and Microsurgery Laboratory of the Orthopaedic Trauma Centre (C. T. O.), Turin, Italy

***Corresponding author:** Messina Antonino, Former Chief Orthopaedic Surgeon and Founder of the Hand Surgery Centre and Microsurgery Laboratory of the Orthopaedic Trauma Centre (C. T. O.), Turin, Italy

Citation: Antonino M (2023) Vascularized Transposition of the Ulnar Nerve in Entrapment Syndrome at the Elbow. Arch Surg 3: 118 DOI: 10.29011/ AOS-118.000018

Received Date: 14 August, 2023; **Accepted Date:** 16 October, 2023; **Published Date:** 19 October, 2023

Abstract

Background and Purpose: The surgical treatment of Cubital Tunnel Syndrome still has unsatisfactory results due mainly to arteriovenous ischemia of the nerve in the Epitrochlear Canal. The purpose of our biological procedure is to restore the vascularization of the nerve, transposed together with its vascular pedicle anteriorly to epicondyle, to immediately reactivate the axonal conduction of the Ulnar Nerve and thereby improve clinical results.

Methods: From 1987 to 2022, a vascularized Anteposition was performed on 87 limbs for Ulnar Nerve Entrapment Syndrome at the elbow in 82 patients.

Results: Fifty-seven Patients returned for follow-up, 52 Patients obtained excellent and good results and effective recovery of sensibility and muscular activity; the electromyographic examination showed many positive changes in the SCV and MCV with increased nerve conduction velocity. Patients with fair results (5 Patients) showed worthwhile recovery of the hand but they recorded many sensory and motor disturbances already present before the operation, even if more attenuated.

Conclusions: Our surgical technique of Vascularised Anteposition of the Ulnar Nerve at the Elbow is able to resolve the mechanical aspect of the chronic neuritis of the Ulnar Nerve at the Elbow but also (preserving its vascularity) the biological aspect of its nutrition. The procedure, allowing effective, quick recovery of hand function in most of the patients of our Study-an improvement in all of them-is a step forward in the treatment of this disease.

Keywords: Biological ulnar nerve transposition; Ulnar nerve entrapment; Ulnar nerve palsy; Vascularized anteposition cubital nerve; Vascularized ulnar nerve transposition

Introduction

Subcutaneous Anteposition Technique at the Elbow has been proposed from 1898 (125 years ago as of the time of writing) by Curtis B.F. for Cubital nerve pathologies.

To day the only more important and innovative surgical methods for treating this condition in the world are :

- Traumatic ulnar neuritis:Transplantation of the nerve, Curtis B,F.1898 (125 years ago) [1];
- The Epitrochlear Canal Opening-Buzzard E,F, 1922 (101

years ago) [2];

- The Submuscular Transposition-Learmonth G,R.1942 (81 years ago) [3];
- The Intramuscular transposition---Gay J.R,and Love J.G (1947) (76 years ago) [4];
- The Epitrochlear removal--King 1950 (73 years ago) [5];
- La Trasposizione microchirurgica del Nervo Ulnare e del suo peduncolo vascolare nella Sindrome compressivo-paretica canalicolare del Gomito (Microsurgical Transposition of the Ulnar Nerve and its Vascular Pedicle in compressive-paretic canalicular syndrome of the elbow)--- Messina A. 1991 (32 years ago) [6]. Although the aetiology of this pathology does not seem to be important, many investigations have been

made into its definition [7,8] giving only generic titles such as: “cubital nerve syndrome,” “cubital tunnel entrapment,” “ulnar nerve entrapment,” “ulnar nerve compression,” “cubital tunnel syndrome,” etc. McGowan [9] distinguished three degrees of lesion severity. However, this this classification, which useful pre-operatively, is not exhaustive for the clinical assessment of the results in the postoperative evaluation.

Foster RJ and Edshage S. conducted a thorough study on Subcutaneous, Submuscular and Intramuscular intervention stating that the overall results are the same above 90%; [10]. Adelaar R,S, et al. state that there is no statistical difference in results between subcutaneous and submuscular transposition [11]. In the King’s Epitrochlear removal, although the nerve remains adjacent to its artery, many potential disadvantages can come [12,13]. Holtzman R,N, et al. suspect that ulnar nerve neuropathy may depend on compression associated with ischaemia or hypoxia of the nerve in the cubital canal [14,15]. Many studies conducted by different authors show compression causes ischaemia and oedema, resulting in deposition of collagen in the epineurium and endoneurium, and underline the importance of the extrinsic blood supply [16-23]. Lastly, the procedure of simple decompression of the ulnar nerve without transposition aims to preserve the nerve’s vascularity, but does not remove the traction-tension during elbow flexion with continuous trauma and possible subluxation of the nerve.

From the analysis of clinical and operative literature, all simple neurolysis, neurolysis and anteposition, neurolysis and transposition performed for different types and stages of clinical pathology showed variable outcomes: some resulted in good functional recovery, others in slight or no improvement or some deterioration and some-time secondary persistent hyperpathy [16,17]. In our experience and in the majority of studies, ulnar nerve neuritis at the elbow is due to continuous traction of the ulnar nerve during elbow flexion which produces a perineural fibrous reactivity, adhesions, and canalicular fibrosis which over time also affects the ligament of Osborne, and strangles it together with its vascular pedicle [11,14,18]. Anteposition procedures currently in use today by performing neurolysis of the entire extra-compartmental segment of the nerve at the elbow isolates and disconnects its longitudinal and epineural vascularity up to 10-15 cm long. The disconnection of the nerve nutrition (in addition to the neuritis pathology) causes impairment of axonal conduction, lengthening of the restoration of the sensory-motor fascicles, secondary dysesthesias and functional failure. So too can it often be observed that chronic compression results in altered epi and endonervial vascularisation of the ulnar nerve, and that in some cases the nerve thickness together with its vascular bundle was severely reduced to an hourglass shape by Osborne’s ligament. In my research published in 1995 by J. H. Surg, I was the first to show in chronical neuritis by mean of an intraoperative arteriography, the blockage of the collateral artero-venous blood flow of the Ulnar Nerve at the Elbow before the opening of the epitrochlear

canal and the immediate restoration of the vascularization of the compressed Ulnar Nerve, immediately after the opening of Osborne’s ligament [18].

The aim of the study, then, is to highlight and update the records and technical details of the procedure. Solving the mechanical aspect of compression in the treatment of ulnar nerve entrapment syndrome at the elbow, this Procedure also represents a biological method: the nerve together with its vascular pedicle preserving its blood supply is transposed anteriorly to the epitrochlear canal, thus enhancing axonal recovery of the nerve. This ensures better functional recovery in all the various degrees of severity and complications of this canalicular pathology in our care [6,18].

Materials and Methods

Operative Technique

A longitudinal curved incision is performed posterior to the epitrochlear epicondyle, extending for 15 centimeters below the condyle. The ulnar nerve and its vascular bundle are inspected above the condyle and dissected proximally by opening the fibro-aponeurotic sheath and the medial intermuscular septum (Figure 1). The ulnar nerve, together with its vascular bundle coming from brachial artery and composed of the ulnar collateral artery and of one or two satellite veins, is dissected and mobilized distally to free it and mobilized under optical magnification [6,17,18]; the use of magnifying glasses is only necessary during vascular time (Figure 2).

After opening of Osborne’s ligament a longitudinal incision of the epineurium is performed on the opposite side of longitudinal collateral blood supply if there exists any constriction of the nerve (MacGowan’s grade 3). The space between the humeral and ulnar insertions of the flexor carpi ulnaris is split and enlarged distally, so that the ulnar nerve together with its vascular bundle after anterior submuscular or intramuscular transposition [3,4] will not be sharply angulated as it enters this muscle group [19]; the motor innervation of the flexor carpi ulnaris must be protected (Figure 2). Immediately after removal of Esmach’s band, the nerve trunk, transposed by intramuscular transposition (Gay and Love) [4], regains its vascularity and becomes red throughout its entire extracompartmental length (Figure 3). The ensuing operative technique of anterior submuscular or intramuscular transposition is essentially that described by Learmonth J.R. (1942) [3]. The elbow is now extended and flexed to assure that there is free movement and no kinking of the nerve and its vascular collateral bundle from the medial intermuscular septum anterior to the epicondyle. The wound is then closed and the limb immobilized in a posterior splint for two weeks with the elbow in 120 degrees of flexion. Range-of-motion exercises are then initiated to reach complete articular motion.

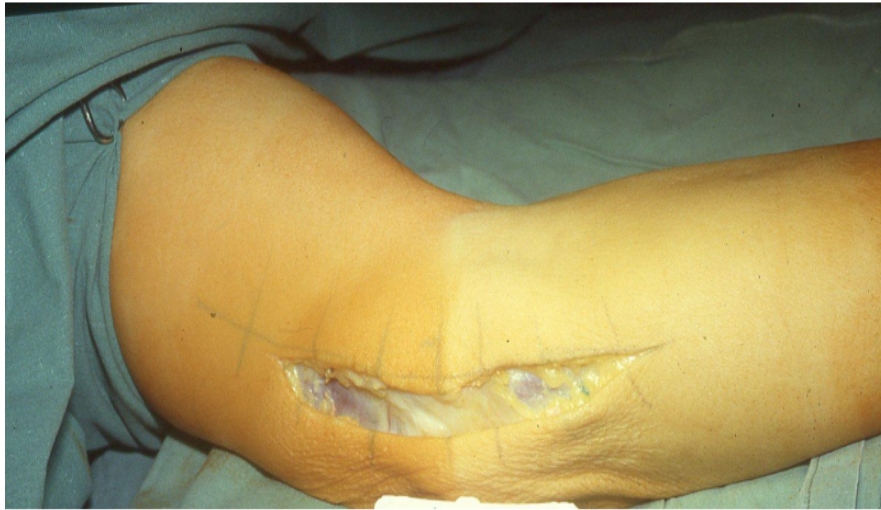

Figure 1: Classic arcuate skin incision at the Elbow for Vascularised Anteponition Technique of the Ulnar Nerve at the Elbow since 1987. “ In addition to the mechanical effect of Anteponition, there is the advantage of the biological effect for nerve fascicles nutrition and early restoration of axonal nerve conduction”.

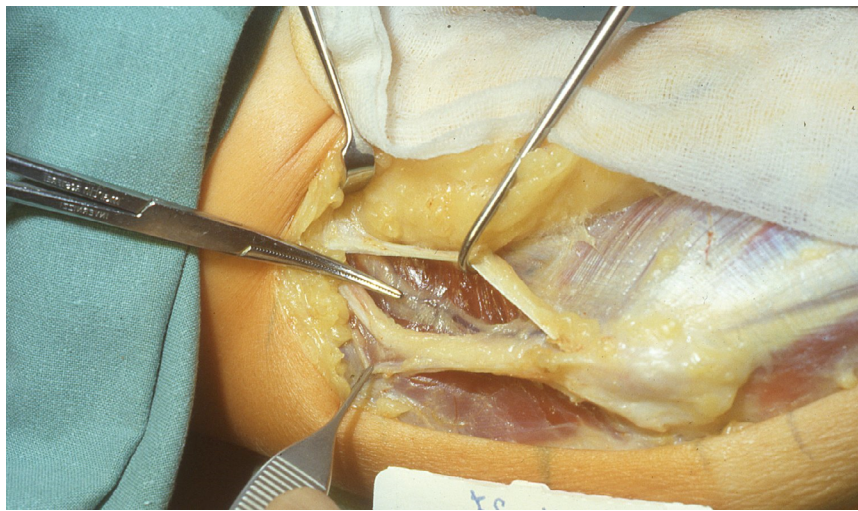


Figure 2: Opening of the fibro-aponeurotic fascia and medial intermuscular septum proximal to the epicondyle; isolation of the ulnar nerve, finding and isolation of its vascular pedicle.

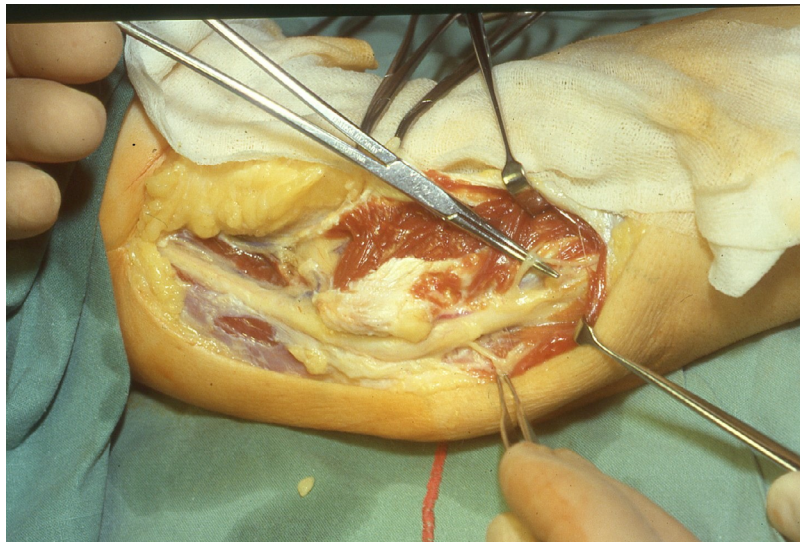


Figure 3: After opening Osborne’s ligament, the ulnar nerve is isolated, which presents, together with its collateral vascular pedicle, a narrowing at the level of the epitrochlear canal and proximally to it, a neuroma.

Materials

From 1987 to 2022, a vascularized Anteposition was performed on 87 limbs for Ulnar Nerve Entrapment Syndrome at the elbow in 82 patients, five of whom were bilaterally affected. Male patients formed a majority (11 female, 71 male); the age ranged from 16 to 83 years. Vascularized Anteposition was done almost exclusively on the right. The cases operated on had a varied and diversified aetiology, 3 cases had hyperpathy as a result of elbow fracture, 7 cases for elbow valgus; the remainder and most had neuritis of various origins ranging from diabetes to elbow overuse; the duration of symptoms ranged from 6 months to 10 years. Patients coming to follow-up with recent disease and belonging to McGowan severity stage 1 were not included in this study. Preoperative sensory symptoms complained of in most patients were: pain (in 9 cases lancinating) spontaneous and continuous, in some cases evidenced by digital pressure. It was located on the ulnar border in the proximal third of the forearm and in the region of the cubital canal; in five cases it was also present in Guyon’s canal; the majority of patients presented hypoesthesia of the ring and little finger, hyperesthesia in the ulnar distribution of the hand, hyperpathy at the cubital canal of the elbow, tiredness and reduced hand muscle strength (grip), difficulty in fine hand movements and gripping objects. Preoperative muscular impairment experienced in most patients were: all patients presented muscular wasting with ulnar hand grapple of varying degrees, atrophy of the hypothenar eminence, interosseous muscles and thumb adductor; various

impairment was present both in subacute cases (symptomatology since about 6 months together with early trophic changes of the hypothenar skin) and obviously in cases of chronic paralysing neuritis.

All patients had a positive Tinel’s sign (more or less intense) at the level of the cubital canal, some of them with distal irradiation to the fourth and fifth fingers. In others the Tinel’s sign was localised only at the level of the epitrochlear canal, while some others complained only of proximal irradiation. The sensory tests were positive in all modes of execution; the maximum elbow flexion test reproduced the symptoms of ulnar entrapment by stretching the ulnar nerve at the elbow of about one cm (the bending determines closing down or narrowing of the epitrochlear tunnel); the signs of Froment and Wartenberg were always present but with varying intensity; reduction in finger abduction-adduction; impairment of figurative tests (nail alignment of long finger, O, C, and glasses Figures 4-7); weakness of lateral key pinch; deficit of active MP flexion and DIP and PIP extension; tactile discrimination and Weber Test were at 15-8 mm. on average. All patients underwent electromyography with nerve sensory and motor conduction velocity; all showed altered nerve conduction time from ulnar neuropathy with increased conduction time at the elbow; all showed alterations of the sensory-motor nerve conduction velocity (NCV) with marked reduction from 32 to 48 m/sec; SCV was always lower than NCV, no conduction in the more severely involved limb. The patients were divided according to MacGowan’s classification [9].

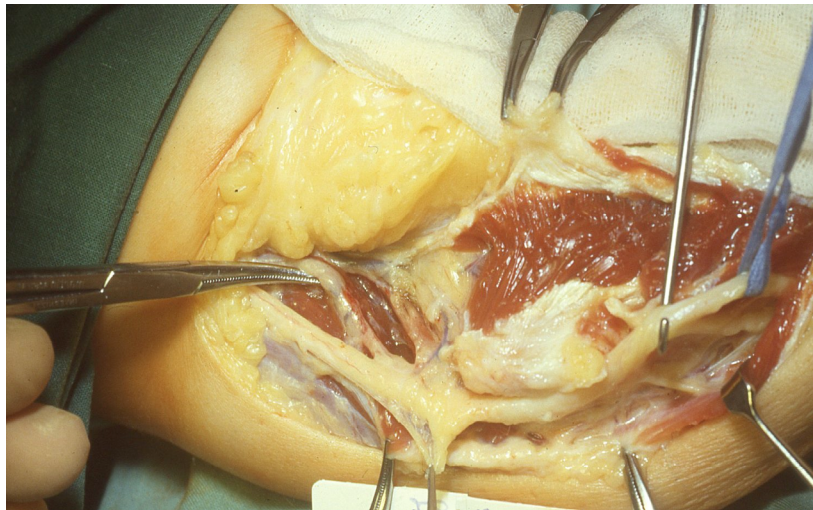


Figure 4: Opening and widening of the ulnar and humeral insertion fascia of the flexor-pronator muscles. Neurolysis of the Ulnar Nerve and Arteriolytic of its collateral vascular pedicle (the use of magnifying glasses is only necessary during vascular time).

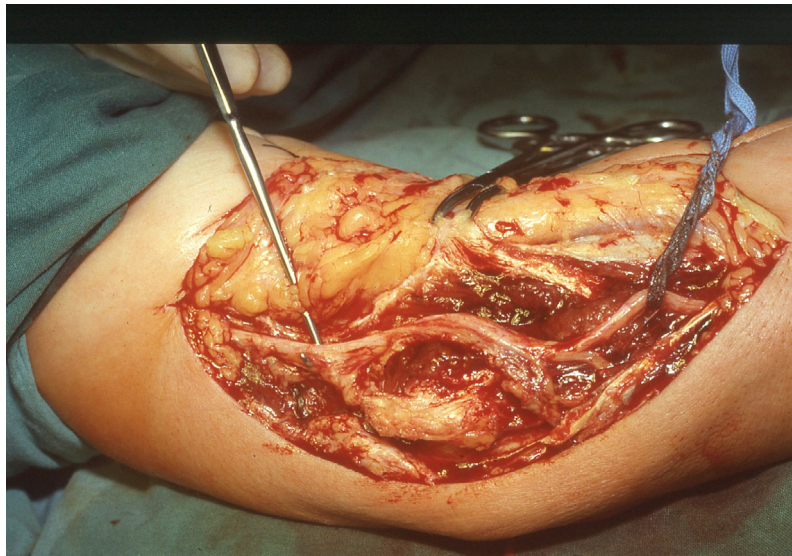


Figure 5: After removal of the Esmarch fascia, the ulnar nerve, anteriorly transposed by means of Intramuscular Transposition according to Gay and Love, regains the vascularity of its collateral arteriovenous pedicle. The entire extracompartmental segment of the vascular collateral pedicle remains adherent to the anteriorly transposed Ulnar Nerve.

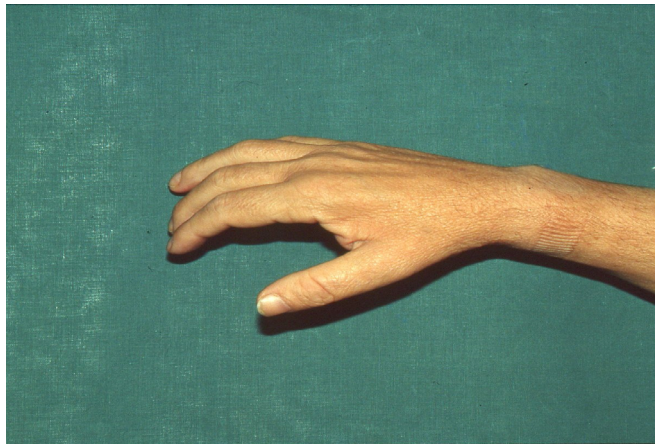


Figure 6: Severe ulnar nerve paralysis at the Elbow: atrophy of the thumb Adductor muscle and all Intrinsic muscles of the Hand; positive Froment Test.



Figure 7: Functional postoperative test two weeks after Vascular Anteposition Surgery: A rapid subjective and objective improvement was recorded in most cases immediately after the procedure. Immediate recovery of Pinch and balance of all muscles of the Thumb Column (although hypotrophy of the Adductor and Interosseus muscles of the hand obviously still persists, patients significantly improve their pain symptoms gaining better function in the fingers, hand, and upper limb).

Surgical Indications

The clinical cases performed presented a striking uniformity, all requiring Vascularized Anteposition of the Ulnar Nerve (the use of magnifying glasses was only necessary during vascular time) and the surgical indications for which were:

- Chronic, paralytic canalicular Entrapment of the Ulnar Nerve at the Elbow.
- Presence proximal to Osborne's ligament of Neuroma or Hourglass narrowing (with possible need for epinerviotomy and interfascicular Neurolysis)
- Paralytic sensory-motor recurrences (treated endoscopically)
- Previous failures of nerve transposition with or without persistent hyperpathy: in seven cases, an intramuscular nerve and vascular pedicle repositioning was performed on the side of the nerve. Six cases that benefit from epicondyle removal procedure were also treated with our technique. Four paralytic sensory-motor recurrences treated endoscopically required our procedure avoiding fixation of ulnar nerve by adhesions in the site of the epitroclear tunnel.

A variety of ulnar nerve pathology was found at surgery: marked hyperaemia, fibrous adhesion of nerve at the epitroclear tunnel, epinervial thickening for 2-3 cm along the canal, compression of the nerve at Osborne's ligament, pseudoneuroma proximal to the compression site. There were no post-operative infections and all wounds healed uneventfully. The results were graded as follows:

- Excellent: complete resolution of symptoms with no post-operative motor or sensory deficit.
- Good: General resolution of symptoms but occasional tenderness at the incision site, mild residual decreased sensibility, and residual motor weakness.
- Fair: Improved after surgery but with persistent sensory changes, residual motor loss, muscle wasting, persistent claw deformity.
- Poor: No improvement after the surgical procedure, or worse.

Results

Fifty-seven patients returned for follow-up; the average follow-up was 7 years and 3 months and ranged from 8 months to 21 years and 5 months. In the observed patients, we recorded 92 per cent excellent and good results; 8 per cent were rated as fair results (5 Patients). A rapid subjective and objective improvement was recorded in most cases immediately after the procedure: Patients with excellent and good results (52 Patients) obtained an immediate, effective recovery of sensibility and muscular activity; fingers soon regained their agility, numbness of the ulnar side of the hand disappeared, as did within a few days pain and paresthesia symptoms in the fingers (probably due to revascularization and repolarization of the axonal membrane). Patients experienced less muscle fatigue in the hand; improved functionality of fine movements of the fingers and grasping of objects; improved functionality of the Elbow and the entire upper limb. In a great many cases, effective and quick sensory and motor recovery was achieved immediately after a few days: early recovery of tactile sensitivity, pain, cotton Test, hot-cold, tactile discrimination and Weber Test at 5-6 mm.; disappearance of Tinel's Sign at the Elbow; Improved prehensile strength of the fingers and positive functional tests; immediate or early disappearance of the initial and mild clawing; progressive recovery of Froment's Sign, Wertemberg's Sign and figurative tests.

The Patients with fair results (5 Patients) showed worthwhile recovery of the hand but they recorded many sensory and motor disturbances already present before the operation, although sometimes more attenuated. These include sensory-motor discomfort as well as dysesthesias, intrinsic muscle weakness, reduced lateral key pinch, and clawing of the fourth and fifth fingers. The 17 cases that were re-operated using the Vascularized Anteposition went from poor to fair grade (McGowan 2 and 3), significantly improving their pain symptoms and gaining better function in the fingers, hand, and upper limb. The hand regained strength and looseness, pain disappeared, sensitivity improved in

the fingers and throughout the ulnar side of the hand and forearm. The atrophy of the hypothenar eminence, the interossei muscles and the thumb adductor muscle remained visible but with function and muscle power still preserved. In the Patients with excellent and good results reviewed, the electromyographic examination showed many positive changes in the SCV and MCV with increased nerve conduction velocity (SCV more appreciable), but overall difficult to assess globally on the treated cases (i.e.-examinations with different age, distance from surgery, execution of the EMG examination difficult to assess for operators, insecure methods used, severity of lesions, length of time between the onset of symptoms and the date of surgery). In the Patients with fair results Electromyography showed evidence of persisting denervation of the muscles pertaining to the ulnar nerve and especially the muscle conduction velocity (MCV).

Discussion

Although every author studying this entrapment pathology fails to define this neuritis of Ulnar Nerve at the elbow, we would like to point out a more appropriate definition for the disorder itself as "Compressive-Paretic Syndrome of Ulnar Nerve at the Elbow." In this definition, the four elements of the pathology are identified and represented: compression, sensory-motor palsy, definition, and the anatomic site of the nerve entrapment. Additionally, it is clear that the disorder can only be defined a Syndrome. Even McGowan's classification of stages of severity, although generic but useful pre-operatively, is not usable for the specific post-operative assessment of each case treated. This is due to the fact that the various stages of clinical severity of the syndrome treated with the main types of intervention show highly variable results overall: chronic compression of the ulnar nerve added to many different factors (age of patients, time of symptoms appearance, pathological local mechanism, profession of the patient, sport or work overuse of the elbow, diabetes, etc) and the state of nerve compression due to inflammatory reaction inside the cubital canal, chronic pathology, proximal neuroma to Osborne's ligament, severe ischemia, perinervial adhesion, hourglass narrowing of the nerve etc, may lead to an aggravation of axonal conduction with impairment and degeneration. That determines a poorer prognosis and more prolonged or impossibility of recovery; remyelination may take many months after the procedure; axonal regrowth is slow and more than a 1 mm/day; in a few old cases of inveterate neuritis wasting of intrinsic hand muscles with severe palsies will be irreversible!

Foster RJ and Edshage S. conducted a thorough study on Subcutaneous, Submuscular and Intramuscular Intervention stating that the overall results are the same above 90%; but almost all cases treated belonged to McGowan gravity stages 1 and 2 and in 87% of the treated patients, the symptoms had appeared on average within the previous 12 months and none of them were examined by electromyographic examination including SVC and MVC. Adelaar R,S, et al. state that there is no statistical difference in results between three types of interventions such as in situ neurolysis, subcutaneous anteposition and submuscular

transposition. Their prospective study also states that preoperative physical examination and electromyogram can predict patients' final outcome. They do not actually consider cases with a need for epineural dissection, perineural dissection, cases needing secondary surgery and state that age and duration of symptoms do not correspond statistically with outcomes. In the King's Epitrochlear removal, many disadvantages can come such as bone tenderness at the osteotomy site, vulnerability of the ulnar nerve, ulnar collateral ligament instability, and weakness from disruption of the flexor pronator origin.

Holtzman R,N, et al. suspect that ulnar nerve neuropathy may depend on compression associated with ischaemia or hypoxia of the nerve in the cubital canal, but this hypothesis actually attributes it to Staal A. [20] and for Holtzman R.and Eaton [14,15] it remains only a hypothetical mechanism. The Procedure of simple decompression of the ulnar nerve without transposition preserves the nerve's vascularity, but does not remove the traction-tension during elbow flexion with continuous trauma and possible subluxation of the nerve. Many basic studies conducted by different authors show that the Entrapment Syndrome causes a progressive peri- and endoneural fibrosis: chronic compression causes ischaemia and oedema, resulting in deposition of collagen in the epineurium and endoneurium: that underlines the importance of the extrinsic blood supply [11,21-23]. Lastly, operative findings in almost all of our treated cases show adhesion of the compressed nerve and perineural thickening together with blockage of the flow of the collateral arteriovenous pedicle and consequently of the peri-epi and endonervial supply.

Finally, the classical Procedures of Anterior Transposition used today cause an additional iatrogenic reduction or blockage of blood flow along the extracompartmental segment of the cubital nerve (for at least 15 cm.) because of the separation of the nerve from its vascular bundle, worsening the axons conductivity [18]. In Conclusion, the procedure of Vascularised Anteposition of the Ulnar Nerve at the Elbow is able to resolve the mechanical aspect of the chronic neuritis of the Ulnar Nerve at the Elbow but also (preserving its vascularity) the biological aspect of its nutrition. Indeed, the maintenance and reactivation of arterial and collateral venous vascular flow, impaired by canalicular compression, perineural fibrosis, and nerve constriction from Osborne's ligament to the elbow, contributes to reactivating axonal conduction of sensory and motor nerve fascicles. The procedure, allowing effective, quick recovery of hand function in most of the patients of our Study, produces an improvement in all of them and in our clinical experience is a step forward in the treatment of this pathology.

References

1. Curtis BF (1898) Traumatic ulnar neuritis: Transplantation of the nerve. *J. Nerv. Ment. Dis* 25: 480.
2. Buzzard EF (1922) Some varieties of traumatic and toxic ulnar neuritis. *Lancet* 1: 317-319.
3. Learmonth JR (1942) A Technique for transplanting the ulnar nerve. *Surgery Gynecology and Obstetrics* 75: 792-793.
4. Gay JR, Love JG (1947) Diagnosis and Treatment of tardy Paralysis of the Ulnar Nerve. *J. Bone and Joint Surg* 29-A: 1087-1097.
5. King TS, Morgan FP (1950) The Treatment of Traumatic Ulnar Neuritis. Mobilization of the Ulnar Nerve at the Elbow by removal of the medial Epicondyle and adjacent bone. *Australian and New Zealand Journal of Surgery* 20: 33.
6. Messina A (1991) La Trasposizione microchirurgica del Nervo Ulnare e del suo peduncolo vascolare nella Sindrome compressivo-paretica canalicolare del Gomito. *Riv. Chir. della Mano* 3: 229-234.
7. Feindel W, Stratford J (1958) The role of the cubital tunnel in tardy ulnar palsy. *Canad. J. Surg* 1958: 278-300.
8. Apfelberg DB, Larson SJ (1973) Dynamic anatomy of the ulnar nerve at the Elbow. *Plast. Reconstr. Surg* 51: 76-81.
9. McGowan AJ (1950) The result of transposition of the ulnar nerve for traumatic ulnar neuritis 32: 293-301.
10. Foster RJ, Edshage S (1981) Factors related to the outcome of surgically managed compressive ulnar neuropathy at the elbow level 62: 181-192.
11. Adelaar RS, Foster WC, McDowell C (1984) The Treatment of the cubital tunnel Syndrome 1: 90-95.
12. McGowan AJ (1950) The results of transposition of the ulnar nerve for traumatic ulnar neuritis. *J.B&J.S* 32: 293-301.
13. Jones RE, Gauntt C (1979) Medial Epicondylectomy for ulnar nerve compression Syndrome at the Elbow. *Clinical Orthopaedics and Related Research* 139: 174-178.
14. Holtzman RNN, Mark MH, Patel MR, Wiener LM (1983) Ulnar nerve entrapment neuropathy in the forearm 1983: 576-578.
15. Eaton RG, Crowe JF, Parkes JC (1980) Anterior Transposition of the Ulnar nerve using a no-compressing fasci dermal sling 5: 820-825.
16. Mooij JJA (1982) Ulnar Nerve Pathology at the Elbow: the place of Anterior Transposition today. *Acta Neurochirurgica* 64: 75-85.
17. Messina A (1994) La Trasposizione microchirurgica del Nervo Ulnare e del suo peduncolo vascolare nella Sindrome compressivo-paretica canalicolare del Gomito. *Giornale Italiano di Ortopedia e Traumatologia* 4.
18. Messina A, Messina JC (1995) Microsurgical Transposition of the Ulnar Nerve and its Vascular Pedicle in compressive-paretic canalicular syndrome of the elbow. *Journal of Hand Surgery (British and European Volume)* 5: 638-648.
19. Amadio PC, Beckenbaugh RD (1986) Entrapment of the ulnar nerve by the deep flexor-pronator aponeurosis 11: 83-87.
20. Staal A (1970) General discussion on pressure neuropathies. In Vinken PJ, Bruyn GW, Editors: *Handbook of clinical neurology. Diseases of nerves*, Vol 7, part 1. Amsterdam, 1970, North-Holland Publishing Co 1970: 276-284.
21. Weisl H, Osborne GV (1964) The pathological changes in rats nerve subjected to moderate compression 46: 297-306.
22. Lundborg G (1975) Structure and function of the intraneural microvessels as related to trauma, edema formation and nerve function 37: 938-948.
23. Ogata K, Naito M (1986) Blood flow of peripheral nerve effects of dissection, stretching and compression 1: 10-14.