

## Case Report

# Unique Treatment Considerations for Chest Wall Desmoid Tumor Invading the Breast

Miriam Steinberger MD<sup>1</sup>, Jody M. Kaban MD, FACS<sup>1</sup>, Miriam David MD<sup>2</sup>, Maria Castaldi MD, FACS<sup>1\*</sup>

<sup>1</sup>Department of Surgery, Jacobi Medical Center, Bronx, New York, USA

<sup>2</sup>Department of Radiology, Jacobi Medical Center, Bronx, New York, USA

\*Corresponding author: Maria Castaldi MD, FACS, Department of Surgery, Jacobi Medical Center, Bronx, New York, USA. Tel: +1-7189185566; Email: Maria.Castaldi@nychhc.org

**Citation:** Steinberger M, Kaban JM, David M, Castaldi M (2018) Unique Treatment Considerations for Chest Wall Desmoid Tumor Invading the Breast. Arch Surg Clin Case Rep: ASCR-110. DOI: 10.29011/ASCR-110/100010

**Received Date:** 10 October, 2018; **Accepted Date:** 16 October, 2018; **Published Date:** 24 October, 2018

## Abstract

Desmoid Tumors (DT) are rare tumors, characterized by infiltrative growth and a tendency toward local recurrence but with an inability to metastasize. Although surgery is the primary treatment modality, there remains significant controversy amongst surgeons regarding the management of disease involving adjacent breast given the possibility for significant functional and aesthetic compromise [1]. This is a rare and interesting case of a young woman with a massive chest wall DT displacing the breast necessitating extensive chest wall resection and right partial mastectomy.

## Keywords

Chest Wall; Desmoid Tumor; Fibromatosis

## Abbreviations

DT : Desmoid Tumor

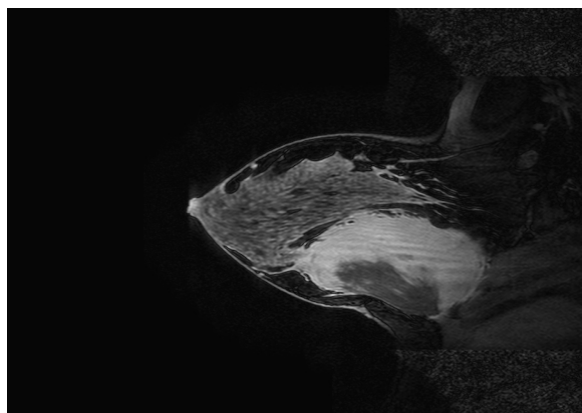
## Introduction

Desmoid tumors (DT), a fibromatous proliferative disease, are defined by the World Health Organization as “clonal fibroblastic proliferations that arise in the deep soft tissues and are characterized by infiltrative growth and a tendency toward local recurrence but an inability to metastasize.” Desmoid tumors are rare tumors, seen in only about three to four cases per 1 million of the U.S. population. They occur between 15 and 60 years of age, more commonly during adolescence. Local recurrence rates for extra-abdominal desmoids range from 24% - 77% in reported series. Fibromatosis or DT of the chest wall represents 8-10% of all cases. Although surgery is the primary treatment modality, there remains significant controversy between surgeons regarding

the management of disease involving adjacent breast given the possibility for significant functional and aesthetic compromise [1]. This is a rare case of a 21 year old female with a massive chest wall desmoid tumor necessitating extensive chest wall resection and right partial mastectomy. We present her clinical course and discuss some of the controversies reported in the literature regarding appropriate treatment for this particularly aggressive and sensitive DT site.

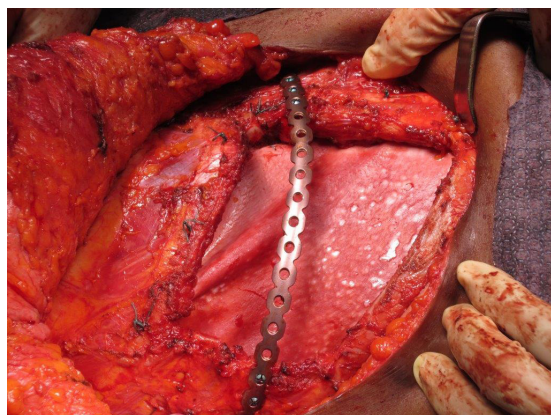
## Case report

A 21 year old woman presented with right breast pain and a gradually increasing mass over 3 months duration. On examination, a 9 cm to 12 cm right breast mass encompassed the entire outer quadrant of the right breast, seemingly adherent to the chest wall. Breast ultrasound showed a complex 8.4 cm by 6.0 cm by 10.3 cm hypoechoic mass with mild increased Doppler flow. Mammography and breast MRI revealed a chest wall mass anteriorly displacing the breast tissue, originating from the pectoralis major muscle (Figure 1).



**Figure 1:** MRI scan (Sagittal View) demonstrating a 10 cm by 10 cm retro mammary complex mass with predominantly enhancing solid components as well as cystic areas. The mass is inseparable from the chest wall muscle and anteriorly displaces the right breast.

Core needle biopsy revealed a spindle cell lesion. Immunohistochemical analysis of the core needle biopsy was negative for markers AE1/AE3, supporting a diagnosis of fibromatosis. Surgical excision of the DT, including partial right mastectomy, and chest wall resection and reconstruction, was undertaken with both breast and thoracic surgeon involvement. The mass was mobilized and noted to originate from the pectoralis major muscle. Resection of the fifth and sixth ribs was necessitated by adherent tumor. A chest wall reconstruction was performed using a rib plate and strattice mesh to reconstruct the chest wall contour and prevent lung herniation. Strattice mesh was fixed to the thoracic cage as an underlay to re-approximate the parietal pleura and protect the lung from direct contact with the rib plate and subcutaneous tissues. This was secured in place with sutures placed through drill holes within the ribs and sternum. A plan for delayed muscle flap reconstruction of the breast was anticipated due to large volume loss in the breast (Figure 2).



**Figure 2:** Photo of tumor cavity post excision and rib resection necessitating a rib plate fixation.

Anatomic pathology revealed a 15 cm tumor with WHO classification of desmoid type Fibromatosis (intermediate, locally aggressive, 2/10 mitosis per high-power field, no necrosis, 2 cm margins). The patient was discharged after a short hospital stay without complication. On return visit the patient was found to be pregnant, delaying breast reconstruction and precluding hormonal treatment typically recommended for DT. At follow up three years post surgery, the patient remains without recurrence of tumor on PET CT imaging. On exam, the scar is well healed, with significant loss of volume in her right breast compared to the left, but with preserved chest wall contour. Three years post procedure there is no evidence of plate failure. The rib plate remains in good position and the patient is pain free. Reconstructive breast surgery with muscle flap is planned to provide a breast mound.

## Discussion

Chest wall tumors have long represented a unique challenge for surgeons. In the past, inability to perform successful reconstruction for large thoracic wall defects led to high perioperative morbidity from infection of the pleural cavity, respiratory failure and paradoxical breathing. Since improvements in surgical reconstruction, antibiotics prophylaxis and anesthesia, the role of surgical treatment for primary malignant tumors is now established. DT is treated as a primary malignant chest wall tumor with regard for adequate margins. For resections involving a defect greater than 5 cm in diameter, thoracic wall solidity must be reconstituted, and can best be achieved with a combination of myocutaneous flaps and mesh materials that provide solidity, stability, protection of endothoracic organs and prevent paradoxical breathing [1,2]. A study in patients undergoing microvascular breast reconstruction suggested that rib plating adds limited additional morbidity and effectively prevents chest contour deformity [3]. While surgery has become the therapeutic mainstay for resectable, localized DT, because of clinical course variability where many tumors spontaneously regress or grow, varying site behavior and an absence of a prospective randomized trial to compare different treatment methods, the exact application of the above mentioned surgical intervention has recently been extensively debated [4]. Support for aggressive surgical resection for extra-abdominal DT with safe margins of 2 cm to 3 cm stems from the potential of fibromatosis to grow locally and invade surrounding structures, causing symptoms, and high rates of local recurrence [5]. Support of more conservative treatment stems from a less optimal cosmetic outcome and risk of loss of function, an absence of reports showing DT can metastasize or evidence that residual tumor has a negative impact on five year disease free or overall survival [6]. A review of standard treatments of truncal sarcomas, including DT shows that age (younger), tumor site (chest wall) and size (>10 cm) are the strongest predictors of tumor recurrence (50% after 5 years), with margin status (RO compared to RI) not considered predictive. While initial surgical resection for chest wall desmoids is justifiable

given their higher rate of symptomatic progression and recurrence, consideration should be given to non-operative management of recurrence rather than repeat resection which may lead to significant morbidity [1]. Our patient met criteria for resection based on rapid tumor growth, DT chest wall location, tumor size exceeding 10cm, and significant risk factors for recurrence, including young age. Studies have shown that optimal chest wall reconstruction achieves stability and maintains pulmonary functionality [2-4]. Given our patient's necessity for complete excision of chest wall DT involving a multiple rib resection, we opted to utilize rib plating to achieve optimal aesthetic and functional outcome.

## References

1. Wilder F, D'Angelo S, Crago A (2015) Soft tissue tumors of the trunk: Management of local disease in the breast and chest and abdominal walls. J Surg Oncol 111: 546-552.
2. Incarbone M, Pastorino U (2001) Surgical Treatment of Chest Wall Tumors. W J Surg 25: 218-230.
3. Ahdoot MA, Echo A, Otake LR, Son J, Zeidler KR, et al. (2013) The matrix rib plating system: Improving aesthetic outcomes in microvascular breast reconstruction. Ann Plast Surg 70: 384-388.
4. Kasper B, Strobel P, Hohenberger P (2011) Desmoid tumors: Clinical features and treatment options for advanced disease. Oncologist 16: 682- 693.
5. Shen C, Zhou Y, Che G (2013) Management of a female with recurrence of fibromatosis of the chest wall adjacent to the breast: A case report. J Cardiothorac Surg 8:41.
6. Neuman HB, Brogi E, Ebrahim A, Brennan MF, Van Zee KJ (2008) Desmoid tumors (fibromatoses) of the breast: A 25 year experience. Ann Surg Oncol 15: 274-280.