

## Case Report

# Unintentional Resetting Phenomenon Caused by Catheter-induced Mechanical Stimulation of the Left Anterolateral Accessory Pathway during Orthodromic Atrioventricular Reciprocating Tachycardia

Hidenori Matsusaka\*, Masashi Sada, Kunio Morishige, Toshihiko Kubo

Department of Cardiovascular Medicine, Matsuyama Red Cross Hospital, Matsuyama, Japan

\***Corresponding author:** Hidenori Matsusaka, Department of Cardiovascular Medicine, Matsuyama Red Cross Hospital, 1 Bunkyo-Chou, Matsuyama, Ehime 790-8524, Japan. Tel: +81899241111; Fax: +81899226892; Email: h-matsu@cardiol.med.kyushu-u.ac.jp

**Citation:** Matsusaka H, Sada M, Morishige K, Kubo T (2017) Unintentional Resetting Phenomenon Caused by Catheter-induced Mechanical Stimulation of the Left Anterolateral Accessory Pathway during Orthodromic Atrioventricular Reciprocating Tachycardia. Cardiol Res Cardiovasc Med 2: 127. DOI: 10.29011/2575-7083.000027

**Received Date:** 28 October, 2017; **Accepted Date:** 07 November, 2017; **Published Date:** 14 November, 2017

## Abstract

An 80-year-old woman was admitted to our hospital for treatment of paroxysmal supraventricular tachycardia which had been increased sharply after the antiarrhythmic drug was decreased. Electrophysiological study demonstrated orthodromic atrioventricular reciprocating tachycardia via the left anterolateral accessory pathway with relatively slow concealed conduction, which we supposed to be a target for catheter ablation. Interestingly, only while the ablation catheter tip was being placed just on the accessory pathway, the tachycardia cycle length was occasionally altered with the atrial sequence advancing forward a little, and the culprit pathway was successfully ablated at this point. We concluded, based on some electrophysiological findings, that this phenomenon was caused by electrophysiological mechanism of resetting, certainly induced by direct mechanical stimulation onto the accessory pathway.

**Keywords:** Accessory Pathway; Atrioventricular Reciprocating Tachycardia; Mechanical Stimulation; Resetting Phenomenon; Slow Concealed Conduction

## Introduction

For the last few decades, catheter ablation targeting an atrioventricular Accessory Pathway (AP) has been well established as the first choice of treatment when needed. It has produced favorable results based on the findings of many conventional methods to investigate electrophysiological characteristics and anatomic locations [1,2] as well as more recent technology including three-dimensional mapping [3]. The resetting phenomenon, which we describe herein, is an electrophysiological finding induced by direct mechanical stimulation of the AP during related tachycardia. Although it cannot be universally applied to all cases, it will surely be useful in limited situations for detecting an optimal ablation point and providing appropriate contact force.

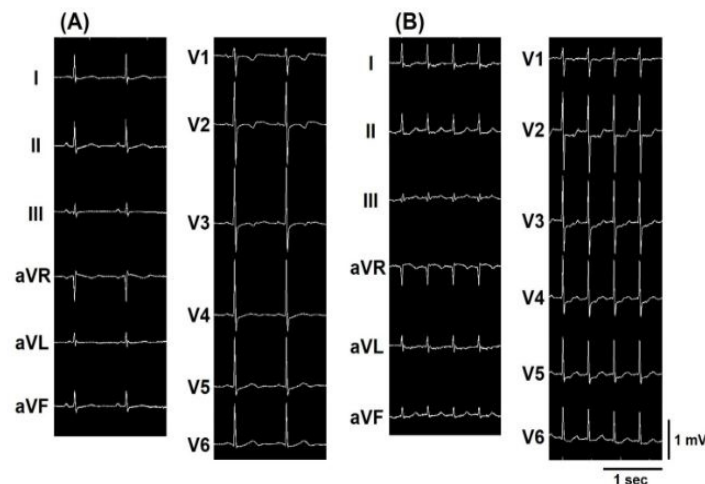
## Case report

An 80-year-old woman had undergone medical therapy for paroxysmal Supraventricular Tachycardia (SVT) and had experi-

enced arrhythmic attacks only rarely for many years. A few days after her pilsicainide was decreased from 150 to 100 mg/day because her chest symptoms were well controlled, she began to suffer from incessant palpitation and was emergently admitted to our hospital. Electrocardiographic monitoring in her doctor's office had revealed regular narrow QRS tachycardia with a heart rate of 120 beats per minute (bpm). It was difficult to differentiate in detail, however, because the electrographic atrial component during the tachycardia was undetectable. No structural heart disease was found on physical examination or transthoracic echocardiography. Considering that the frequency of her symptom had been obviously increasing under a relatively high dose of antiarrhythmic drug for her age, we performed radiofrequency catheter ablation the next day.

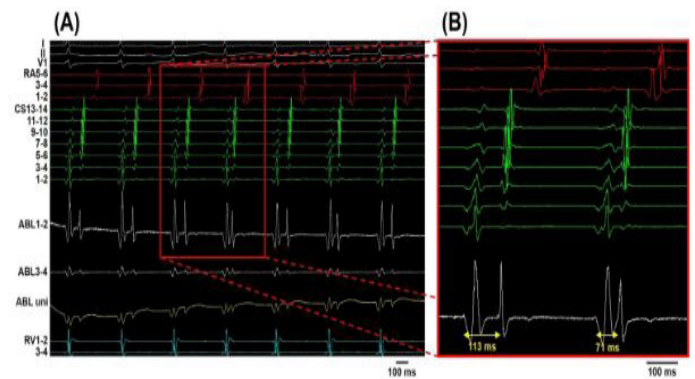
The electrophysiological study was performed in a routine manner without deploying a three-dimensional mapping system. A 12-lead surface electrocardiogram during sinus rhythm showed no marked abnormalities such as a delta wave (Figure 1A). Ventricular pacing revealed a left anterolateral concealed AP with a minimum local Ventriculo Atrial (VA) conduction time of 220 ms. A spontaneous premature atrial beat induced SVT of around 140

bpm (Figure 1B), with the earliest atrial activation at the anterolateral mitral annulus. Right ventricular overdrive pacing during the SVT revealed concealed entrainment with the atrial sequence unchanged, and the difference between the post-pacing interval and the SVT cycle length was 84 ms. Frequent premature atrial beats then began to provoke SVT incessantly, which prevented us from further promoting electrophysiological study concerning the detailed characteristics of the atrioventricular conduction or the AP. We judged, based on the limited findings shown above, that the clinically documented SVT was most likely to be orthodromic Atrioventricular Reciprocating Tachycardia (AVRT) via the left anterolateral AP, which we considered to be a target for catheter ablation.



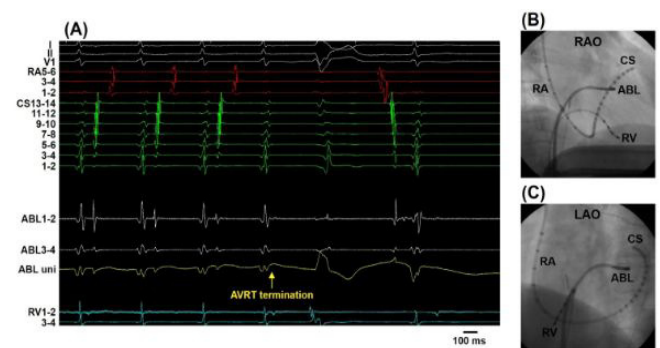**Figure 1(A-B):** Twelve-lead electrocardiogram recorded during an electrophysiological study. (A) Sinus rhythm. (B) Supraventricular tachycardia.

Transseptal puncture was performed with a radiofrequency-powered transseptal needle (NRG™ Transseptal Needle; Baylis Medical Company, Montreal, QC, Canada) under the navigation guidance of intracardiac echocardiography (AcuNav; Siemens, Erlangen, Germany). A non-irrigated 4-mm tip ablation catheter (Ablaze Fantasia 4ML; Japan Lifeline, Tokyo, Japan) was inserted into the left atrium. Interestingly, it was only while the ablation catheter tip was being placed at the anterolateral mitral annulus, possibly just on the targeted AP, that the tachycardia cycle length was occasionally altered, with the atrial sequence advancing forward somewhat. The local VA conduction time was shortened from 113 to 71 ms at the minimum (Figure 2), which seemed to be acceleration or resetting of the AVRT. An AP potential was not detected during the AVRT or ventricular pacing.



**Figure 2:** Intracardiac electrogram during atrioventricular reciprocating tachycardia. (A) The resetting phenomenon is observed at the fourth and sixth beats at a sweep speed of 100 mm/s. (B) Magnification of the third and fourth beats in (A) at a sweep speed of 150 mm/s. The local ventriculoatrial conduction time of the native beat was 113 ms but was shortened to 71 ms because of the resetting phenomenon. RA, right atrium; CS, coronary sinus; ABL, ablation catheter; uni, unipolar recording; RV, right ventricle.

Application of only 4.5 s of 20 W radiofrequency energy to this point terminated the AVRT followed by the VA block (Figure 3). We then applied additional 30 W energy at contiguous points under ventricular pacing. VA conduction via the treated AP never recurred even after bolus administration of adenosine triphosphate or continuous infusion of isoproterenol. Furthermore, dual atrioventricular nodal pathways were ruled out and no other types of tachycardia were induced by programmed stimulation thereafter. During the following 6 months, she was free from palpitation without the use of antiarrhythmic drugs. We thus concluded that the AVRT was cured.



**Figure 3:** (A) Intracardiac electrogram shows that the atrioventricular reciprocating tachycardia (AVRT) was terminated soon after applying radiofrequency energy and the sinus rhythm was recovered. (B) Right

Anterior Oblique view (RAO) and (C) Left Anterior Oblique view (LAO) of fluoroscopic images at the moment of AVRT termination. It shows that the ablation catheter (ABL) was located at the anterolateral mitral annulus. RA, right atrium; CS, coronary sinus; uni, unipolar recording; RV, right ventricle.

## Discussion

We showed in this case report that orthodromic AVRT was successfully treated by ablating the left anterolateral AP with relatively slow concealed conduction. The unique phenomenon of an occasionally shortened VA conduction time, observed only when the ablation catheter tip was located on the culprit AP, was an intriguing and meaningful finding, ultimately leading treatment to success.

VA conduction observed in the present case appeared to be slower than usual APs [4]. We therefore thought that one of the causes of this phenomenon was VA conduction delay. Although a relatively slow concealed conduction might be intrinsic to this patient, it might also have been secondary to a residual pharmacological effect of pilsicainide. She had been taking this drug until the day before treatment, and it could not have completely washed out of her system. This speculation is supported by a previous report proving that class I antiarrhythmic drugs prolong the retrograde conduction time of the concealed AP [5].

It is extremely difficult, and has been rarely attempted, to stimulate the AP alone deliberately-whether electrically or mechanically-as it would affect the myocardium of the adjacent chambers. In the present case, it is clear that the ablation catheter was properly placed on the mitral annulus because the intracardiac electrographic amplitudes of the ventricle and atrium were almost comparable. There is following evidence that the stimulated tissue exhibiting this phenomenon was not the adjacent atrial myocardium but the AP per se. First, among all the electrode catheters, this focused location indicated the earliest atrial activation during the AVRT. Also, the atrial sequence and the wave forms of the beats involved in this phenomenon were nearly identical to those of the AVRT native beats. Second, this phenomenon was observed quite reproducibly only at the interested site, not when the ablation catheter was shifted even slightly to other sites nearby. Finally, the culprit AP was easily and successfully ablated at the very point where this phenomenon was recorded, which also excludes the possibility of broad/multiple pathways [6] or atrial tachycardia as a result.

Accordingly, we speculated that ventricular contraction during the AVRT occasionally vibrates the ablation catheter tip enough to stimulate the AP alone, which generates excitation that travels upward to the atrium, before the reciprocating excitation of the AVRT returns from the ventricle to the point of interest on the AP. Thus, this phenomenon was provoked by an electrophysiological mechanism of resetting. To the best of our knowledge, this sort of

resetting phenomenon has not yet been reported elsewhere. If an AP potential (a well-established indicator of successful ablation [1,7]) had been detected during the procedure, our speculation would be more decisively substantiated. And we admit it to be the limitation of this case report that His potential as a reference should have been recorded during the SVT and more detailed electrophysiological examination, if possible, was needed to definitely diagnose the AVRT or to investigate the characteristics of the AP. Incidentally, if the antegrade conduction of the AP were preserved, this resetting phenomenon might not have occurred because catheter-induced excitation would go dominantly downward to the ventricle and offset the AVRT.

Sometimes during catheter ablation, inappropriate catheter-induced mechanical stimulation of targeted points causes unintentional conduction block, the “Bump” phenomenon, which has been described as indicating the target location [8]. This phenomenon, however, tends to make subsequent procedures difficult and may eventually render treatment unsuccessful [9]. Meticulous catheter handling is then required, especially around the sites of interest, although recently available technology addressing contact force is expected to be useful for overcoming this drawback to some extent [10]. From this viewpoint, the resetting phenomenon observed in the present case certainly demonstrates that the ablation catheter tip was kept in direct contact with the AP moderately enough not to cause the “bump” phenomenon. We acknowledge that this resetting phenomenon is a less common sort of catheter-induced mechanical stimulation and may seem trivial enough to be overlooked or may be simply treated as supernormal conduction. We emphasize, however, that this rather incidental finding is of great importance for identifying the optimal ablation point-surely as useful as an AP potential-and applying the appropriate contact force, so it should not be missed if a satisfactory outcome is the goal.

## Teaching point

Appropriate catheter-induced mechanical stimulation can directly activate an accessory pathway without unfavorably causing its conduction block and also reset orthodromic atrioventricular reciprocating tachycardia with slow ventriculoatrial conduction. The resetting phenomenon is an important clue to pinpointing the optimal ablation target and confirming the appropriateness of a catheter’s contact force on the culprit accessory pathway.

## References

1. Haïssaguerre M, Gaita F, Marcus FI, Clémenty J (1994) Radiofrequency catheter ablation of accessory pathways: a contemporary review. *J Cardiovasc Electrophysiol* 5: 532-552.
2. Jackman WM, Wang XZ, Friday KJ, Roman CA, Moulton KP, et al. (1991) Catheter ablation of accessory atrioventricular pathways (Wolff-Parkinson-White syndrome) by radiofrequency current. *N Engl J Med* 324: 1605-1611.

3. Worley SJ (1998) Use of a real-time three-dimensional magnetic navigation system for radiofrequency ablation of accessory pathways. *Pacing Clin Electrophysiol* 21: 1636-1645.
4. Manita M, Kaneko Y, Kurabayashi M, Yeh SJ, Wen MS, et al. (2004) Electrophysiological characteristics and radiofrequency ablation of accessory pathways with slow conductive properties. *Circ J* 68: 1152-1159.
5. Fujiki A, Tani M, Yoshida S, Inoue H (1996) Electrophysiologic mechanisms of adverse effects of class I antiarrhythmic drugs (cibenzoline, pilsicainide, disopyramide, procainamide) in induction of atrioventricular re-entrant tachycardia. *Cardiovasc Drugs Ther* 10: 159-166.
6. Iturralde P, Guevara-Valdivia M, Rodríguez-Chávez L, Medeiros A, Colin L (2002) Radiofrequency ablation of multiple accessory pathways. *Europace* 4: 273-280.
7. Otomo K, Gonzalez MD, Beckman KJ, Nakagawa H, Becker AE, et al. (2001) Reversing the direction of paced ventricular and atrial wavefronts reveals an oblique course in accessory AV pathways and improves localization for catheter ablation. *Circulation* 104: 550-556.
8. Tai YT, Lee KL, Lau CP (1994) Catheter induced mechanical stunning of accessory pathway conduction: useful guide to successful transcatheter ablation of accessory pathways. *Pacing Clin Electrophysiol* 17: 31-36.
9. Belhassen B, Viskin S, Fish R, Glick A, Glikson M, et al. (1999) Catheter-induced mechanical trauma to accessory pathways during radiofrequency ablation: incidence, predictors and clinical implications. *J Am Coll Cardiol* 33: 767-774.
10. Akca F, Janse P, Theuns DA, Szili-Torok T (2015) A prospective study on safety of catheter ablation procedures: contact force guided ablation could reduce the risk of cardiac perforation. *Int J Cardiol* 179: 441-448.