

Research Article

Ultrasound-Assisted Mastopexy

Luis V. Vecilla Rivelles*

Doctor, Specialist in Plastic, Reconstructive and Aesthetic Surgery, Dermalia Clinicas, Spain

***Corresponding author:** Luis V. Vecilla Rivelles, Doctor, Specialist in Plastic, Reconstructive and Aesthetic Surgery, Dermalia Clinicas, Av/ Sajonia 25, 28420 Galapagar, Madrid, Spain. Tel: 607726264; E-mail: vecivelles@gmail.com

Citation: Vecilla Rivelles LV (2017) Ultrasound-Assisted Mastopexy. Plast Surg Mod Tech 2: 116. DOI: 10.29011/2577-1701.100016

Received date: 1 April, 2017; **Accepted date:** 29 April, 2017; **Published date:** 6 May, 2017

Abstract

The goal of any surgeon when performing a Mastopexy is to find a technique that allows you to achieve an aesthetically correct anatomical shape with minimal scarring. This does not appear to be easy since more than fifty techniques have been used over the last century. The correction of Ptosis of the breast, either accompanied by an increase or reduction of breast size usually involves large scars due to the skin resection needed to raise the breast to its proper position. In addition these techniques frequently entail complications and the asymmetries inherent there in.

On the other hand, the surgical procedures are long and require general anaesthesia and hospitalization. Patients are often disappointed, not in vain is this type of surgery one that causes the highest number of lawsuits in our specialty, usually due to complications, scarring and asymmetries. To prevent this, I propose an Ultrasound Assisted Liposuction (UAL) technique, with a Mentor Contour Genesis system as main device, that is based on the assumption that breast Ptosis is due to the effect of gravity on the fibrous scaffold supporting the gland. Retensing said network by applying ultrasound is the basis of my technique, and this is what distinguishes it from those developed so far by other authors who have used this energy with the purpose of reducing breast fat volume and tightening the skin.

Anatomical Memory

Figure one

The mammary gland is suspended from the surrounding skin by a fibrous web which, starting from the dermis is inserted into the fibro-glandular crests of Duret [1]. These are structures that go across the glandular surface mostly parallel to the milk ducts. These bands form a network of support ligaments called Cooper's ligaments defining spaces between the skin and the gland filled with adipose tissue which are called cavities of Duret [1].

At the back, the gland is covered with superficial fascia infiltrated by adipose tissue, forming the retro mammary bursae of Chassaignac [1]. When adipose tissue is well developed, the breast is projected forward, according to Tripier [1] leading to mammary hypertrophy of adipose origin. This also indicates that this retro glandular space is physiologically the most suitable place to position the implant when we want to increase the breast volume. It is also the objective of liposuction in cases of adipose hypertrophy.

The retro glandular superficial fascia is attached to the fascia

of the Pectoralis major muscle and together they reach the lower clavicular edge, forming the suspensory ligament [1]. The collagen fibers present in the dermis, Cooper's bands or ligaments and the fibro-glandular crests of Duret go from their primitive convoluted state to a longitudinal alignment by the effect of gravity forces [2]. This gradually stretches these structures and their length increases allowing glandular sagging or Ptosis of the breast.

Back ground

The use of ultrasound energy in liposuction was published by Zocchi M.L. [3]. Its use in breast reduction was developed by Goes J.C. [4] and subsequently by other authors, such as Di Giuseppe [5].

Material and Methods

23 patients with Regnault's grades I and II Ptosis may be classified in three groups:

First group: 3 patients with Ptosis that also require increasing the breast volume (Figure 2a and 2b).

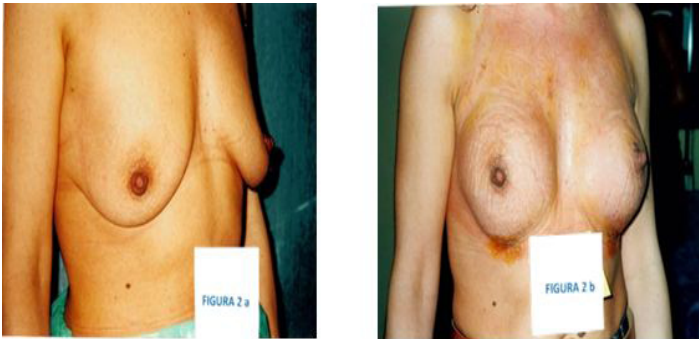

Figure 2: Illustration of before (a) and after (b) in a case of Ptosis needing volume enlargement. It therefore refers to the first group.

Second group: 12 patients with Ptosis which mainly require Re-tensing Cooper's ligaments, and in which there is no considerable excess or lack of volume (Figure 3a and 3b).

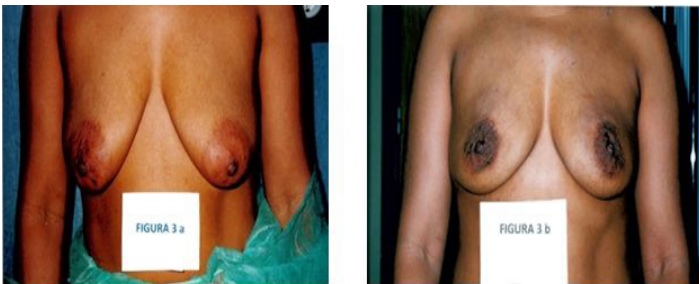

Figure 3: A case of before (a) and after (b) pexy without requiring a significant increase or reduction of volume; it refers to the second group. Compare the distance changes of the areola in relation to the flexure of the elbow.

Third group: 8 patients with Ptosis requiring concomitant reduction in volume (Fig.4a and 4b).

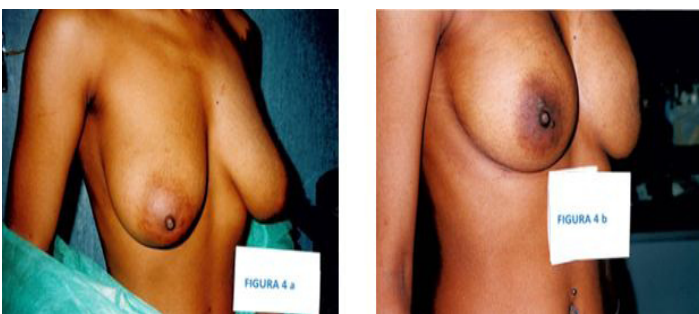


Figure 4: A case of before (a) and after (b) pexy requiring a reduction of volume; it refers to the third group. Note the change in areola position respected to the flexure of the elbow in preop and postop.

In the first group I perform an infiltration of a Klein-type diluted local anaesthetic [6], at the discretion of the anaesthesiologist. From the inframammary crease, and with the help of a pump, I infiltrate the cold solution into the retro mammary space where I will place the implant. Once the prosthesis has been inserted

through the bottom of the breast and preferably in a sub-glandular position, I close the incision in planes. Sometimes, either due to very thin skin, or other circumstances which so advice, the implant may be optionally placed under the fascia of the pectoralis major or under the muscle.

I then infiltrate the upper breast pole, making radial paths from the areola across the cavities of Duret, and impregnating the mesh of Cooper's ligaments and subcutaneous tissue around the upper pole. It is important that the anaesthetic solution should be cold. I wait a few minutes and then perform radial sweeps with the ultrasound cannula (Mentor Contour Genesis), parallel to the fibro-glandular crests and Cooper's ligaments (Figure 5) applying medium energies for a few minutes, with slow forward and backward movements. Then, I extract the destroyed fat by an aspiration cold cannula. No criss-crossing is performed. This step lasts just five minutes. I drain manually, close the areolar incision and apply a tape bandage positioning the nipple-areola complex in place.

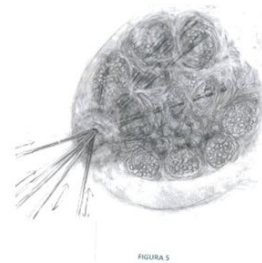


Figure 5: Drawing by the author in which treatment with ultrasound is expressed in the upper pole, from the edge of the areola radially, without criss-crossing.

For the second group, the cold infiltration is performed in the same manner, applying the ultrasound cannula in the retro mammary space, so as to retract and tighten the suspensory ligament and to dissect a plane to allow the ascent of the gland. I proceed with the upper pole as in group one. The bandage is similar to that of the preceding group (Figure 6).




Figure 6: Drawing by the author to describe pexy treatment when more volume is not needed and also when breast volume is to be reduced. The difference lies in the time of ultrasound action and the adipose drainage of the retro mammary space.

In the third group, preliminary diagnosis is very important; exploration gives us an idea, but it is essential to establish through mammography or ultrasound scanning if hypertrophy is of an adipose or glandular nature. Otherwise the technique is similar, differing in that I perform more fat removal by conventional liposuction, specially addressing the retro mammary space from the sub-mammary incision, and in that treatment extends to all breast poles radially from various entry points in the areola without criss-crossing (Figure 6). Bandaging is similar to the preceding groups.

In all cases, I perform the first dressing on the fourth or fifth day, when the result is perfectly visible (Figure 7 a and b) (Figure 8 a,b and c) and (Figure 9 a and b)

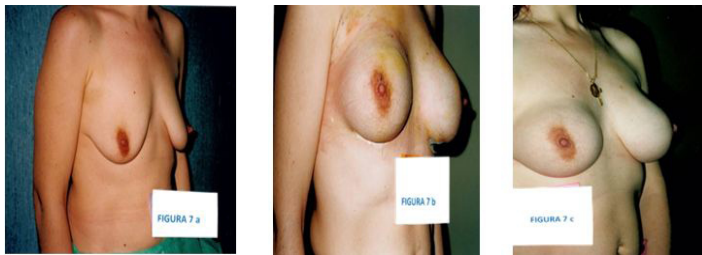


Figure 7: Photos of before (a) and four days after (b) and a few months after (c) in a case of Ultrasound assisted Mastopexy and augmentation with sub-glandular implants showing an obvious result from the first dressing at 4days.

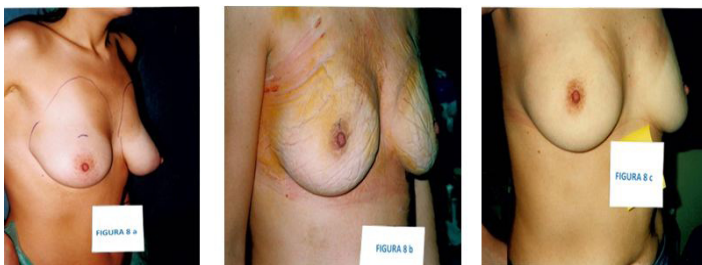

Figure 8: Photos of before (a), after a few days (b) and after a few months (c) in a case of ultrasound assisted pexy with little reduction in volume. The good result is noted from the first dressing at 4 days. Note the change in NAC position in relation to the freckle.

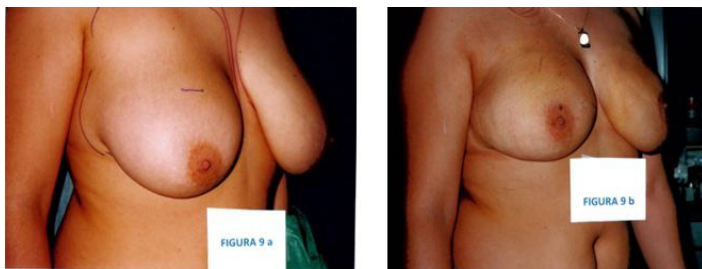

Figure 9: Before (a) and after (b) in a case of breast reduction. Note the change in NAC position in relation to the flexure of the elbow.

Discussion

“How can a surgeon hope to gain control over such an unruly, soft, semi-fluid structure with an elastic covering?” Paul K.

Mc Kisson said in his commentary to Jan. M. Ramselaar’s article [8]. This quote gives us insight into why for over 70 years reduction and / or Mastopexy techniques have hardly evolved based almost exclusively on the resection of skin and other breast tissues.

Furthermore, the type of correction has changed little in recent years. An important step was the introduction of liposuction in mammoplasty by M. Lejour [7], who wrote about these difficulties saying: “The ideal breast reduction should create beautiful breasts with no scars. Unfortunately, no surgeon has ever been able to produce such a result”. Zocchi [3] Goes [4], Di Guiseppe [5] and others have developed the use of ultrasound in mammoplasty, taking advantage of the dermal collagen shrinkage that this technique achieves, which was demonstrated in the work of Scheffan M. and Tazi H [9]. While always used by Dr. Goes, he declares that satisfactory mastopexies are not achieved with this technique, so he resorts to conventional surgery in a second stage [4].

The key reason why this technique has not become more popular despite the good results published by the said authors, is the potential dangers posed by new technologies on a cancer-prone organ and the difficulties which might arise for further diagnosis and treatment; on the other hand, it is also due to the high cost of this technology. Besides the aforementioned authors who have shown that this technique produces less density than conventional techniques, other works have also demonstrated this [10,11]. All show that this type of liposuction produces minimal changes which do not mask subsequent diagnostic tests or do so to a lesser extent than conventional techniques. Another interesting work that evidences the safety of this energy in the mammary gland is that of Walgenbach KJ [12] which studies the histological changes following the use of ultrasound in breast reductions and demonstrates that no glandular damage occurs. I have to emphasize here that the Contour Genesis system I use has an auto-stopping system in the presence of any tissue denser than fat.

In addition, I must stress that the objective of treatment is not the mammary gland, yet the structures that surround it; I seek the retraction of the supporting connective tissue of the gland and of the structures that form it, skin dermis and Cooper’s ligaments (Figure 1 and 1’ and Figure 10).

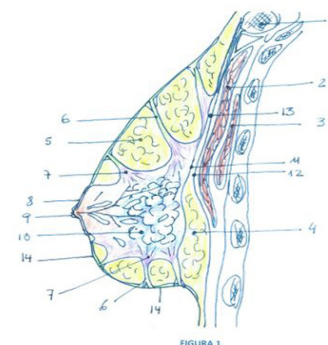


Figure 1: Diagram inspired in Figure 1383 of L Testut (1) which identifies:

1. Clavicula
2. Major Pectoral Muscle
3. Minor Pectoral Muscle
4. Space adipose retro-mammary
5. Adipose cavities of Duret
6. Fibrous septa or Cooper's ligaments
7. Fibro-glandular crests of Duret
8. Areola
9. Nipple
10. Mammary gland
11. Superficial Fascia
12. Fascia of Pectoralis Major muscle
13. Suspensory ligament of the breast
14. Dermis of skin covering

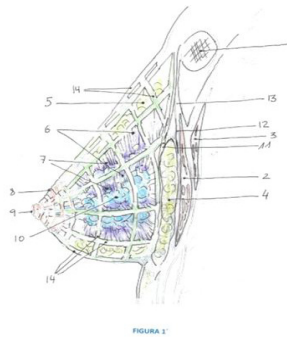

Figure 1: Author's artistic interpretation of Figure 1

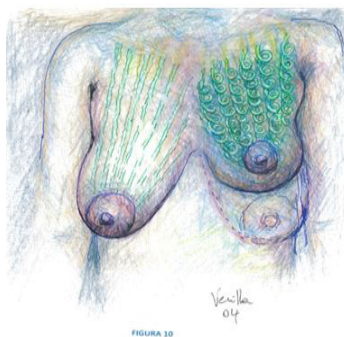


Figure 10: Author's drawing expressing the concept of ultrasound assisted Mastopexy on which his technique is based, which is to achieve the retraction of the glandular support structure.

Where I also want to reduce the volume, I perform liposuction on the Duret cavities and the retro glandular bursa using both ultrasound and drainage with cold cannulas (Figure 6). Unlike other authors, I do not perform criss-crossing, because I believe it to be counterproductive in guiding the direction of collagen retraction pursued. Also, the fact that access is made through the areolar

edge and parallel to the crests of Duret when applying ultrasound distinguishes me from my predecessors. For those cases where reductions are too large for the use of liposuction only, I perform a first stage with the said technique; I assess the result and a few months later may conduct a second stage of skin resection, if the patient so wishes.

In any case, the use of ultrasound in breast treatment is gradually becoming more popular, as is clear from Mary K. Gingrass's article on page 681 of Chapter 65 of the latest edition of Grabb and Smith's Plastic Surgery [13] wherein, referring to Ultrasound Assisted Liposuction (UAL) she states: "UAL is an extremely efficient tool for the removal of fat in fibrous areas such as the upper back, the hypogastrium and the breast" and "The intervening fibro-connective tissues remain relatively unharmed and available for postoperative skin retraction".

Conclusion

The techniques described are, in my opinion, valid alternatives for certain cases of Mastopexy, useful in Regnault's grades I and II Ptosis, with a maximum decline of 4-5 cm. of the NAC respected to its ideal position, both for cases in which you have to increase the volume and in those in which you have to reduce it. Its main advantages are the minimal scarring and the low morbidity. Equally important is the possibility of local anaesthesia with sedation and the semi-out patient regime (Table 1). On the other hand, the high cost of the device (70000 euro) and the potential danger pose don a cancer-prone organ by these new technologies are disadvantages.

Results

Age (years)	29 ± 10
Peso (kg)	57 ± 4
ASA I - II	5 (100%)
Surgery time (min)	51 ± 6
Calculated reduction volume (ml)	455 ± 317
Total aspirated volume (ml)	436 ± 338
Ramsay Squash Stop (1-6)	2,6 ± 0,5
Maxima VASn (0-10)	1.6 ± 0.5
Postoperative Complications	0 (0%)
Discharge time (min)	158 ± 14

Table 1: Table designed by the anaesthesiologist, showing the surgical time and degree of sedation, among other parameters, of a series of 20 cases of Ultrasound assisted Mastopexy with varying degrees of hypertrophy. This series does not include cases in which implants were additionally placed, which in any case would not be very different. I want to stress on the incidence of zero complications and the discharge time, besides the short surgery.

References

1. Testut L and Latarjet A (1975) *Anatomía Humana*. Chap.4 In: (9th edn) Salvat Editores 1321-1353.
2. Thomas Gibson (1990) Physical properties of skin. Chap.7 In: Mc Cathy (edn): Philadelphia, WB Saunders Company, *Plastic Surgery* 207-211.
3. Zocchi ML (1996) Ultrasonic assisted lipoplasty. *Clinics in Plastic Surg* 23: 575-558.
4. Goes JC, Landecker A (2002) Ultrasound Assisted Lipoplasty (UAL) in breast surgery. *Aesthetic Plast Surg* 26; 1-9.
5. Di Giuseppe A (2003) Breast reduction with ultrasound-assisted lipoplasty. *Plastic Reconstr Surg* 112: 71-82.
6. Klein JA (1987) The tumescent technique for liposuction surgery. *Am J Cosmetic Surgery* 4: 263-267.
7. Lejour M (1994) *Vertical mamaplasty and liposuction*. (1st edn) St. Louis. Missouri, Quality Medical Publishing.
8. Jan M, Ramselaar (1988) Precision in breast surgery. *Plastic R. Surg* 82: 643.
9. Schefflan M, Tazi H (1996) Ultrasound assisted body contouring. *Aesthetic Surg Q* 16: 117.
10. Habbema L (2009) Breast reduction using liposuction with tumescent local anesthesia and powered cannulas. *Dermatol Surg* 35: 41-50.
11. Mellul SD, Dryden RM, Remigio DJ, Wulc AE (2006) Breast reduction performed by liposuction. *Dermatol Surg* 32: 1124-1133.
12. Walgenbach KJ, Riabikhin AW, Galla TJ, Bannasch H, Voigt M, et al. (2001) Effect of ultrasonic assisted lipectomy (UAL) on breast tissue: Histological findings. *Aesthetic Plast Surg* 25: 85-88.
13. Mary K, Gingrass (2014) Liposuction. Chap 65 In: (7th edn) Grabb and Smith's, Lippincott William and Wilkins, *Plastic Surgery* 2014: p679-687.