

## Case Report

# Treatment of Pain Associated with Lyme Disease Neuralgia Using Perineural Injection Therapy: A Case Report

Jeffrey Langland<sup>1,2\*</sup>, Samar Riaz<sup>1</sup>, Amoz Van Dyke<sup>1</sup>, Forrest Beck<sup>1</sup>

<sup>1</sup>Southwest College of Naturopathic Medicine, Tempe, USA

<sup>2</sup>Arizona State University, Biodesign Institute, Tempe, USA

\*Corresponding author: Jeffrey Langland, Southwest College of Naturopathic Medicine Tempe, Arizona, USA. Tel: +14807270449; Email: j.langland@scnm.edu

**Citation:** Legland J, Riaz S, Dyke AV, Beck F (2017) Treatment of Pain Associated with Lyme disease Neuralgia Using Perineural Injection Therapy: A Case Report. Curr Res Complement Altern Med:CRCAM-119. DOI: 10.29011/CRCAM-119/100019

**Received Date:** 09 October, 2017; **Accepted Date:** 21 October, 2017; **Published Date:** 31 October, 2017

### Abstract

This case report demonstrates a novel and successful treatment for induced pain associated with Lyme disease. Perineural Injection Therapy was used as the sole treatment for neurological pain in the hand, knee, leg, and foot of the patient. Conventional treatment for Lyme neuralgia often focuses on the use of pharmaceutical agents such as tricyclic antidepressants and gabapentin which do not focus on decreasing the inflammation of the nerves associated with Lyme disease. The patient received five injection treatments for the left-hand pain and nine injection treatments for the right knee, leg and foot pain that successfully decreased the pain by 80% and increased joint mobility that led to an increased quality of life as reported by the patient. The treatment was not only successful in providing immediate decrease in pain but also had a long-lasting effect with minimal side effects. As the pain did not return once the treatment was completed, therefore, the study supports the use of Perineural Injection Therapy as a novel and successful treatment for addressing Lyme neuralgia.

**Keywords:** *Borrelia burgdorferi*; Chronic lyme disease; Chronic pain; Lyme disease; Lyme neuralgia; Neural prolotherapy; Naturopathic medicine; Neuroborreliosis; Perineural injection therapy

### Introduction

Lyme borreliosis is a common vector borne bacterial infection caused by *Borrelia burgdorferi* and transmitted to humans by the bite of an infected black legged tick, specifically the species of *Ixodes scapularis* and *Ixodes pacificus* [1]. Over 30,000 cases of Lyme disease are reported to CDC each year in the United States, and yet that only represents the cases that were diagnosed or confirmed by a physician [1]. However, there are many cases that remain undiagnosed for years prior to being identified as Lyme's disease. In the United States, most cases reported to the CDC are concentrated in the mid-west and upper northeast [1]. Some of the first signs of the infection includes fatigue, headache, fever and erythema migrans (Skin rash) [2].

Lyme borreliosis is a multisystem disorder with chronic neuropathic pain occurring in 10-15% of the patients most commonly seen in the late stage of Lyme disease or due to delayed diagnosis or treatment of the condition [3]. The pain can occur weeks to months after the infection and 29% of patients continued to complain of Lyme-associated neuralgia 3-5 years post-antibiotic treatment [4]. The pain commonly manifests as arthralgia, myalgia, paresthesia and persistent peripheral or central neuropathic pain that is conventionally treated with tricyclic antidepressants and opioids [3,5]. However, the conventional treatment has been shown to be less than 50% effective in addressing the pain.<sup>3</sup> Therefore, in this study we evaluated the efficacy of a novel treatment of neuro borreliosis by using Perineural Injection Therapy (also known as Neural Prolotherapy).

Perineural Injection Therapy or Neural Prolotherapy (NPT) was first introduced by John Lyftogt (MD) who demonstrated that neuropathic pain is caused by sensitization of the nerves due to post-traumatic neurogenic inflammation. The targets of his

therapy were nociceptive nerves and specifically the peptidergic sensory nerves that are cutaneous nerves containing capsaicin receptors and are responsible for the maintenance and health of joint structures including ligaments and tendons along with the pain modulation [6]. The treatment involves injecting 5% dextrose subcutaneously along the tender points of the affected nerve area. The dextrose solution when injected into the peptidergic nerves stimulates the TRP-V1 receptor function that initiates the body's pro-inflammatory response that stimulates self-healing and in return causing a decreased in sensation of pain and decreased neuralgic inflammation [7]. Although the technique is now widely being used for the treatment of traumatic injuries to the tendons and ligaments along with neuralgia's such as post-herpetic neuralgia at the trigeminal nerve, published data on successful use of Perineural Injection Therapy specific to the treatment of neurogenic pain due to Lyme disease is lacking. Therefore, the following case demonstrates the effective and successful use of Perineural Injection Therapy in addressing neuropathic pain associated with neuroborreliosis leading to an increased peripheral joint mobility and improved quality of life of the patients infected with *Borrelia burgdorferi*.

## Presenting Concerns

A 45-year-old Caucasian female presented with a previous diagnosis of Lyme's disease confirmed by IGENEX ELISA test and Western Blot three years prior. The patient had a 3-year history of unresolved fatigue, myalgia, arthralgia, and neuralgia and bone pain due to Lyme disease that was unsuccessfully treated with several different antibiotics including doxycycline, tinidazole, clarithromycin and recently rifampin. As for her pain, some of the past naturopathic and pharmaceutical interventions included the use of high-dose vitamin intravenous therapy, sauna therapy, acupuncture, homeopathy, cannabinoid oil, and low-dose naltrexone among others that were also unsuccessful in addressing her pain. At the time of the presentation, the patient reported 8 out of 10 joint pain (10 being worst) as her biggest concern for which she was taking 800mg-1200mg of ibuprofen per day that did not provide her any relief for her inter-phalangeal joints, the metacarpal phalangeal joints, the carpal-metacarpal joint pain as well as right knee pain. Her reported persistent bone pain and muscle pain led to decreased mobility and decreased quality of life. At presentation, her Lyme disease infection was still considered active and was being treated by an alternative naturopathic physician with doxycycline (200mg per day) for 2 months. The same physician was also treating her simultaneously for Hashimoto's thyroiditis and hypo androgenism. However, even with the successful management of these co-existing conditions, the patient reported no change in her pain associated with Lyme disease.

## Intervention

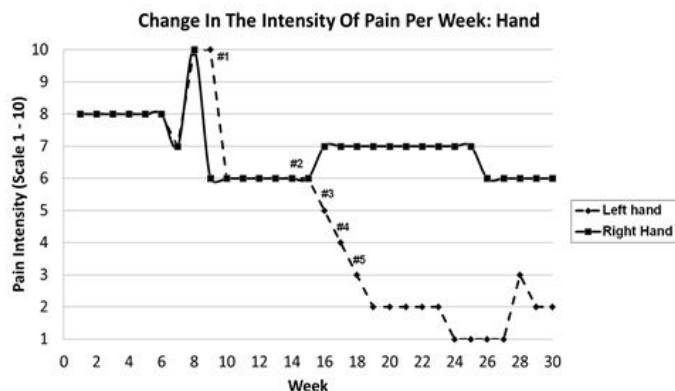
Perineural Injection Therapy was utilized as a treatment for addressing the patient's Lyme neuralgia. Due to the widespread

nature of the pain, it was decided to start in one region to determine the effectiveness of pain reduction before employing to other regions. Each isolated region was treated weekly and continued until a resolution of approximately 80% of the pain was observed. The patient reported the most painful area as her left hand therefore, injection treatment was initiated in the left forearm spanning from the olecranon process to the digits of the left hand involving both the anterior but mostly the posterior aspects. The intensity of pain was rated on a scale of 1 to 10 with 1 being minimal pain and 10 being the maximum pain. Tender spots were palpated at the metacarpal phalangeal joints, proximal interphalangeal joints, distal interphalangeal joints and carpal-metacarpal joints on the dorsal and palmar surfaces of the left hand along with the interosseous membrane between the radial and ulnar bone. The numbers of tender spots were determined each week for the qualitative measurement of the effectiveness of the treatment along with the subjective change in the intensity of pain as described by the patient. Treatment involved preparing the area with a 70% isopropyl alcohol wash followed up by the injection of 5% dextrose solution buffered with 8.4% of sodium bicarbonate (1.25mL of sodium bicarbonate in 250mL of 5% dextrose solution) drawn into 6mL syringes with 27 gauge ½ inch needle. Approximately 0.5mL-1.5mL of the solution was injected into each tender point palpated along the distribution of the following nerves on the left hand: radial nerve, palmar and dorsal branch of the radial nerve, palmar branch of the median nerve, dorsal branch of the ulnar nerve and lateral ante brachial cutaneous nerve. Each visit with the physician lasted approximately one hour per week where the first fifteen minutes were spent discussing the outcome and success of the previous treatment including any reported adverse effects post-treatment and evaluating the number of tender spots observed on palpation. The left hand was treated for five treatments and on the fifth treatment appointment, treatment was initiated on the right lower extremity, from the patella to the distal phalanges as that was the next most painful area reported by the patient. The lower extremity injections were administered for nine treatments until the subjective pain and the numbers of tender spots were decreased by 80%. The injections for the right lower knee, leg and foot were administered in office each week along the distribution of the superficial fibular nerve, deep fibular nerve, common fibular nerve, saphenous nerve, tibia nerve, sural nerve, lateral sural cutaneous nerve, intermediate and medial cutaneous nerve, dorsal digital nerves, and medial and lateral plantar nerves. The success of the treatment was determined by the decrease subjective pain, a decrease in number of tender points, a decrease in number of nerves involved with neuro-inflammation, and by an increase in joint mobility of the area that was treated. No specific post-treatment procedures were required.

## Outcomes

The effects of the treatment were determined by the subjective decrease in pain on a scale of 1 to 10 with 10 being the maximum

pain and the percentage decrease in pain as reported by the patient (0% -100%). The change in the pain was also determined by the quantitative decrease in number of tender spots as determined by physical palpation of the treatment area. The results are summarized in (Table 1) showing the criteria used to monitor the effectiveness of the treatment. (Figure 1 and Figure 2) demonstrate the change in the intensity of pain over the course of 29 weeks from the patient's first visit to the clinic to the last treatment visit.



**Figure 1:** A comparison of the change in the intensity of pain measured on a scale of 1 to 10 (10 being maximum) for the left hand (Treated) and right hand (Untreated) per week. Injection times are shown (#).

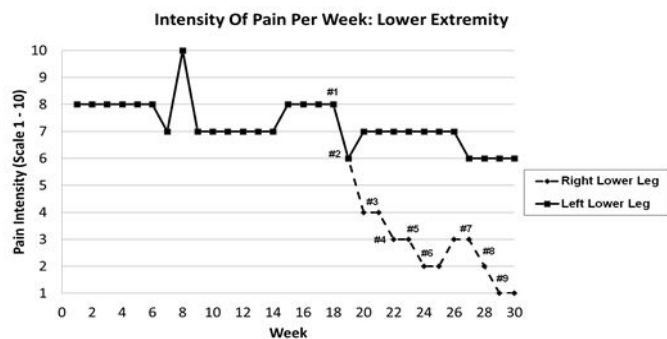


Figure 2.

**Figure 2:** A comparison of the change in the intensity of pain measured on a scale of 1 to 10 with 10 being the maximum pain for the right lower extremity (Treated) and left lower extremity (Untreated) per week. Injection times are shown (#).

Treatment area	Treatment number	injection points	Pain intensity*	Percent improvement
Left Hand	1	10	6	10-20%
	2	34	5	50%
	3	35	4	55-60
	4	50	3	65%
	5	79	2	80%

Right Leg, Knee, Foot	1	207	6	5-10%
	2	169	4	10-20%
	3	119	3	20-30%
	4	136	3	30-40%
	5	76	2	45-50%
	6	61	3	55-60%
	7	94	2	70%
	8	82	1	80%
	9	48	1	80%

**Table 1:** Change in the number of injection point's required qualitative change in the intensity and qualitative improvement in the pain and mobility after each injection treatment of the left hand and of the right knee, leg and foot. \*Pain intensity on scale of 1-10 (10 being the maximum pain).

(Figure 1) demonstrates the intensity of pain as reported by the patient after every treatment for the left hand that was being treated in comparison to the untreated right hand. After the first injection treatment, the subjective pain in the left hand decreased from 10/10 to 6/10 pains. With each treatment the pain was successfully decreased by 1-2 points and after five treatments, the pain was successfully decreased to an intensity of 2/10. In comparison, the untreated right-hand pain was 6/10 at the start of the left-hand treatment and increased to a 7/10 pain and remained unchanged throughout the five treatments of the left hand. After the second treatment of the left hand, there was a reported 50% improvement in the mobility of the phalangeal and wrist joints whereas by the end of the fifth treatment of the left hand the patient had an 80% reported improvement in her symptoms of pain and improved joint mobility. The number of tender spots on the left hand varied depending on the surface area covered for the treatment where in the first treatment only 10 tender spots were treated whereas, on the fifth treatment 79 tender spots were treated that led to 80% total improvement in the symptoms. This factor was dependent on the patient's ability to tolerate the treatment, and with increased tolerance, more surface area was treated. Furthermore, with each treatment the pressure required to elicit the pain in these spots was significantly higher as determined by physical palpation. (Figure 2) further confirms the success of the Peri Neural Injection Therapy for reducing the pain associated with Lyme disease where the patient's right knee, leg and foot were treated for a total of 9 treatments to observe a total reduction of pain by 80% in the right lower extremity. Figure 2 shows the decrease in intensity of pain in the right lower extremity over the course of five treatments compared to the untreated left lower extremity. The effectiveness of the treatment was determined using the same criteria as for the left hand where the subjective decrease in pain on a scale of 1 to 10 with 10 being the maximum pain. The percentage decrease in pain or increased joint mobility as reported by the patient (0% - 100%) and the change in the pain was determined by the quantitative decrease in number of tender spots on physical palpation of the area. After

the first treatment, the pain in both legs decreased by two points from an intensity of 8/10 pain to 6/10 pain. However, the patient attributed the improvement in the left leg pain as to the warmer and drier weather conditions. After the second treatment, the pain in the treated right lower extremity further decreased to 5/10 pain whereas the left lower extremity (Untreated) had an increase in the intensity of pain. As the treatments continued, the intensity of pain decreased by 1-2 points after each treatment for the right side whereas the intensity of pain remained unchanged for the left extremity (Untreated) as shown in (Figure 2).

With each treatment, the patient reported a 5-10% improvement in her subjective pain and increased joint mobility for the right knee, leg and foot. The success of the treatment was also evaluated by the significant decrease in the number of tender spots palpated during the physical evaluation and by the increased pressure required after each treatment to elicit pain in these areas. Prior to beginning the treatment, 207 tender spots were palpated along the right lower extremity whereas after the second treatment the tender spots decreased to 167 and after the eighth treatment the overall number of tender spots had decreased to 48 with most of the spots concentrated along the saphenous nerve distribution. The patient also reported an overall 80% improvement in the joint mobility and pain for her right knee, leg and foot pain during her ninth lower extremity treatment appointment. Both (Figure 1 and 2) show that the injection therapy was successful in providing a constant resolution in pain of the treated areas and the pain did not increase or return to the original intensity in the period in between treatments where the patient did not receive any injection therapy. The only adverse effects reported by the patient during the treatment included symptoms of mild swelling, bruising and tenderness of the injected areas that were self-limiting and resolved within 48-72 hours.

## Discussion

This case demonstrates the effectiveness of Perineural Injection Therapy in treating neuralgic pain associated with Lyme disease. The therapy successfully decreased the intensity of pain likely by decreasing the neuro-inflammation of the peptidergic cutaneous nerves responsible for the observed pain response. The inhibitory effect of the injections was long-term as no return in pain was observed during the treatment period as seen in (Figure 1 and 2). In (Figure 1), the first treatment that the patient received for her left-hand pain was during week 9 of her visit to the clinic which led to a decrease in her pain from 10/10 (10 being the maximum pain) to 6/10 pain. The patient did not receive any treatments between week 10 and week 15 however, her intensity of pain and joint mobility continued to stay at the level of 6/10 pain as reported by the patient. After the last treatment for the left hand (Fifth treatment) the intensity of pain decreased to a 2/10 pain with 80% reported improvement in her symptoms. The intensity of pain continued to remain stable at the level of 2/10 pain for four weeks

post-treatment and had some changes due to weather (Temperature) changes with a reduction to 1/10 pain for four weeks during warmer weather and increased to a 3/10 pain temporarily due to a return of colder weather. The patient's pain intensity for the left hand subsequently remained at the level of 2 /10 pain. This demonstrates that even though the patient did not receive any further treatments for her left-hand pain, the pain continued to remain at an intensity of 2/10 pain for the next twelve weeks and did not return to the original intensity. Similarly, for the right knee, leg, and foot treatment, Figure 2 shows that the patient did not receive any treatments between weeks 19 and 21 yet no increase in pain was observed during this time. A slight increase in pain by one point was observed between week 25 and 27 where no treatment was provided to the patient however, it should be noted that during this time the patient had sprained her right ankle that led to increased inflammation of the cutaneous nerves of the foot and increasing the intensity of pain. Nevertheless, once the injection therapy was reinitiated at week 27, the pain successfully decreased to a 2/10 pain within one week and to 1/10 pain in 2 weeks. This further solidifies that Neural Prolotherapy may be a successful treatment for treating neuroborreliosis and the effects of the treatment are long-term.

During the time that the patient received injection therapy for her left-hand pain and her right knee, leg and foot pain, the patient was simultaneously suffering from coexisting medical conditions. Among which she experienced the reactivation of Epstein - Barr virus (EBV) infection as confirmed by EBV titers for which she was treated with antivirals. Furthermore, based on her clinical presentation, she was diagnosed with Babesia infection as well. While all the above-mentioned conditions should have led to an increase in her intensity of pain or worsening of her symptoms, the progressive decrease in her pain after each treatment is indicative that the reduction in pain can be attributed to the success of the Perineural Injection Therapy and not due to the medical and supplemental treatments provided to the patient for her coexisting conditions. In (Figure 2), a decrease in pain was observed for the left leg pain between week 18 and 19 and weeks 25 and 27. However, during this time the patient received physical manipulation (Adjustment) for her sciatic nerve pain that led to the decrease in her pain levels in the untreated leg and does not signify an overall decrease in her pain due to supplemental treatments provided for her EBV, Lyme or Babesia infection.

The conventional treatment for Lyme disease is the use of antibiotics which has a high success rate in eliminating the disease pathogen [8]. However, a small number of patients are refractory to the treatment and continue to develop the symptoms of a late stage chronic Lyme disease that includes peripheral nerve involvement leading to symptoms of neuralgia and arthralgia [9]. There is another group of patients who show persistent symptoms of Lyme disease without serologic evidence of the infection [9]. These patients may develop characteristics that mimic late stage or chronic



Lyme disease lasting greater than six months [10]. While the argument can be made that this patient may have been suffering from Post-Lyme Disease Syndrome, it should be noted that the patient had persistent symptoms for over two years that had progressively worsened and active disease was confirmed with ELISA testing followed by a Western blot. During the course of the treatment, the patient did start a second round of treatment with doxycycline as well as a follow-up treatment with rifampin for her *Borrelia* infection. Both treatments had no impact on the intensity of pain and the mobility of the joints for her hand and leg pain as indicated by the lack of change in the pain for untreated areas (Left knee, leg and foot). She also did not observe any changes in her fatigue or quality of life with the antibiotic treatment but was able to perform more daily activities as the injection treatment continued for her hand and leg pain since she had increased mobility and dexterity in the treated areas [11]. The patient continues to receive treatment for her symptoms and at the 6-month follow-up appointment; the patient reported a slight increase in her left-hand pain where the intensity of pain went from being 2/10 to a 4/10 along with her right knee pain, which was 5/10. However, the increase in the pain is likely due to the fact that during this time she sprained her right ankle, developed plantar fasciitis in the right foot and was started on a new treatment regimen for Hashimoto's thyroiditis and hypoadrogenism that she did not tolerate well. Nevertheless, the intensity of pain remained lower than that reported at the initial visit (10/10 pain for the left hand and 8/10 pain for the right knee). Therefore, it can be concluded that Perineural Injection Therapy may be a successful treatment protocol to address Lyme neuralgia by treating localized areas in patients with active and chronic Lyme disease. The therapeutic effect was determined to be long lasting and not temporary with minimal side effects such as bruising. In the future, treating the nerves at the site of branching should be considered to address the nerve irritation and decreasing the inflammation at the distribution site of the nerve [12].

## References

1. CDC How many people get Lyme disease? Centers for Disease Control and Prevention. Published September 30, 2015. Accessed February 2, 2017.
2. CDC. Lyme Disease-United States, 2003-2005. *Morbidity and Mortality Weekly Report*. 2007; 56(23): 573-576.
3. Wissenbacher S, Ring J, Hofmann H (2005) Gabapentin for the Symptomatic Treatment of Chronic Neuropathic Pain in Patients with Late-Stage Lyme Borreliosis: A Pilot Study. *Dermatology* 211: 123-127.
4. Zimering JH, Williams MR, Eiras ME, Fallon BA, Logigian EL, et al. (2014) Acute and chronic pain associated with Lyme borreliosis: Clinical characteristics and pathophysiologic mechanisms. *Pain* 155: 1435-1438.
5. Logigian EL, Kaplan RF, Steere AC (1990) Chronic Neurologic Manifestations of Lyme disease. *New England Journal of Medicine* 323: 1438-1444.
6. Hauser RA, maddela HS, Alderman D, Baechnisc G, Banner R, et al. (2011) Journal of Prolotherapy International Medical Editorial Board Consensus Statement on the Use of Prolotherapy for Musculoskeletal Pain. *Journal of Prolotherapy*; 3: 744-764.
7. Conaway E, Browning B (2014) Neural Prolotherapy for Neuralgia. *Journal of Prolotherapy* 6: 928-931.
8. Klempner MS, Hu LT, Evans J, Schmid CH, Johnson GM, et al. (2001) Two Controlled Trials of Antibiotic Treatment in Patients with Persistent Symptoms and a History of Lyme Disease. *New England Journal of Medicine* 345: 85-92.
9. Feder HM, Johnson BJ, O'Connell S, Shapiro ED, Steere AC, et al. (2007) A Critical Appraisal of "Chronic Lyme Disease". *The New England Journal of Medicine* 357: 1422-1430.
10. Mitty J, Margolius D (2008) Updates and Controversies in the Treatment of Lyme disease. *Medicine & Health/ Rhode Island* 91: 219.
11. Stricker RB (2007) Counterpoint: Long-Term Antibiotic Therapy Improves Persistent Symptoms Associated with Lyme disease. *Clinical Infectious Diseases* 45: 149-157
12. Ścieszka J, Dąbek J, Cieślík P (2015) Post-Lyme disease syndrome. *Reumatologia / Rheumatology* 1: 46-48