



Case Report

Take a Look in the Eye: Long-Term Multimodal Ophthalmological Assessment of Leukemic Retinopathy, A Case Report

Matteo Di Marino*, Clarissa Giannini*, Raffaele Mancino, Carlo Nucci, Massimo Cesareo

Ophthalmology Unit, Department of Experimental Medicine, University of Rome Tor Vergata, Rome, Italy

*Corresponding author: Matteo Di Marino, Clarissa Giannini, Ophthalmology Unit, Department of Experimental Medicine, University of Rome Tor Vergata, Via Montpellier 1, 00133, Rome, Italy

Citation: Di Marino M, Giannini C, Mancino R, Nucci C, Cesareo M (2022) Take a Look in the Eye: Long-Term Multimodal Ophthalmological Assessment of Leukemic Retinopathy, A Case Report. Ann Case Report 7: 777. DOI: 10.29011/2574-7754.100777

Received Date: 11 February, 2022; Accepted Date: 15 February, 2022; Published Date: 18 February 2022

Abstract

Background: This case report aims to describe for the first time a long-term multimodal assessment of chronic myeloid leukemia retinopathy and to describe structural and functional retinal changes associated with the disease by the fundus perimetry examination using the original colocalization method that superimposes retinal differential light sensitivity values onto spectral-domain optical coherence tomography macular volumetric maps.

Case presentation: 44-year-old Caucasian woman with a sudden bilateral impairment of visual acuity underwent an ophthalmological evaluation, Spectral-Domain Optical Coherence Tomography (SD-OCT), fluorescein angiography, and Fundus Perimetry (FP). Fundus examination showed bilateral leukemic retinopathy. The SD-OCT showed focal accumulations of hyperreflective material, with the remodeling of adjacent retinal structure. The fluorescein angiography revealed blocking hypofluorescence, perivascular miliary microaneurysms, venous tortuosity, and moderate peripheral retinal ischemia. The FP mean differential light sensitivity (DLS) was reduced. The patient was promptly sent to onco-hematological wide counseling, the routine blood test showed a hyperleukocytosis ($436 \times 10^3/\text{mm}^3$), high neutrophil counts, low hemoglobin (10.3 g/dL), and low platelet count ($130 \times 10^3/\text{mm}^3$). The CT showed splenomegaly and marked leukocytosis at the peripheral blood smear with a range of immature cells compatible with chronic myeloid leukemia. The diagnosis was confirmed by the detection of the BCR-ABL gene (p210 b3a2 type) by quantitative Real Time-PCR which showed positivity of 99% of the analyzed cells. The patient firstly underwent cytoreductive therapy with Hydroxyurea and then started Imatinib mesylate therapy. A progressive SD-OCT amelioration was reported monthly, showing the resolution of retinopathy. The mean DLS also showed an improvement along with the restoration of retinal morphology. The mean DLS returned to normal for age (19,4 dB in RE and 19,8 dB in LE). The Optical Coherence Tomography Angiography (OCTA), available only in the last follow-up, revealed a reduction in the vascular density of both the superficial and deep macular plexuses. **Conclusion:** Multimodal retinal assessment using SD-OCT, FP, and OCTA could be useful in evaluating the long-term effects of CML retinopathy and in demonstrating the long-term subclinical effects of the disease. Although the pathology shows a multiorgan picture, the eye can be the only site that allows direct visualization of visceral signs.

Keywords: Chronic myeloid leukemia; Case report; Fundus perimetry; Leukemic retinopathy; OCTA: Optical Coherence Tomography Angiography; SD-OCT: Spectral-Domain Optical Coherence Tomography

Abbreviations: CML: Chronic Myeloid Leukemia; SD-OCT: Spectral-Domain Optical Coherence Tomography; FP: Fundus Perimetry; DLS: Differential Light Sensitivity; OCTA: Optical Coherence Tomography Angiography; RE: Right Eye;

LE: Left Eye; BCES: Bivariate Contour Ellipse Area; VA: Visual Acuity; BCR-ABL Gene: The Breakpoint Cluster Region and the Abelson Gene

Introduction

Chronic Myeloid Leukaemia (CML) is a malignant clonal disorder of hematopoietic stem cells characterized by an increase of myeloid, erythroid cells, and platelets in peripheral blood and by marked myeloid hyperplasia in the bone marrow. The disease results from a chromosomal rearrangement leading to the formation of a novel fusion gene, BCR-ABL, which encodes the BCR-ABL protein that has constitutive protein tyrosine kinase activity. The oncogene is the result of a translocation t(9;22)(q34;q11) between the long arms of chromosomes 9 and 22, forming the Philadelphia chromosome (Ph), with the juxtaposition of the breakpoint cluster region (BCR) and the Abelson gene (ABL), which can be detected by Real Time-PCR cytogenetic analysis. The introduction of Imatinib, an inhibitor of the BCR-ABL tyrosine kinase, changed completely the treatment of chronic-phase CML, with deeper and faster excellent therapeutic responses. The median age at presentation is 53 years, but all age groups, including children, could be affected. The incidence is 1-2 cases per 100000 [1,2]. About 40% of patients are asymptomatic and, in the absence of treatment, CML progresses within several years from a chronic phase to an accelerated phase and culminates in blastic phase and death. The typical symptoms at presentation are fatigue, anorexia, and weight loss. The most common sign is splenomegaly. Ocular findings may be the only or initial manifestation of the disease and they have been reported in up to 50% of patients with newly diagnosed CML. The ophthalmic manifestations of leukaemia can be divided into primary (caused by direct infiltration of neoplastic cells) and secondary (determined by the indirect involvement of dysplastic cells or resulting from chemotherapy and immunosuppression). Although the retina is the most common site of ocular manifestations of leukemia, other parts of the eye can be involved, presenting with conjunctiva venous abnormalities, iris, trabecular meshwork, choroidal and orbital infiltration [3]. Retinal involvement in CML is characterized by intraretinal, subretinal, or subhyaloid hemorrhages, Roth's spots, cotton-wool spots, retinal vascular tortuosity, retinal infiltrates, pseudo-sheathing of retinal vessels, serous retinal detachment, and papilledema. The increase in blood viscosity and retinal capillary closure can lead to retinal vascular occlusion, macular ischemia, and peripheral retinal nonperfusion, with consequent retinal neovascularization, neovascular glaucoma, and vitreous haemorrhage [4,5]. Ocular involvement is often associated with a visual impairment, which prompts the patient to perform an eye examination, allowing a timely diagnosis. Although the pathology shows a multiorgan picture, the eye can be the only site that allows direct visualization of visceral signs. Many authors have described leukemic

retinopathy but currently [6-8] to the authors' knowledge; there are no reports in the literature with such a long-time follow-up period and FP evaluation.

Case Presentation

A 44-years-old Caucasian woman presented to our outpatient eye clinic in Rome "Tor Vergata" in August 2012 for a bilateral, painless, and acute decrease in Visual Acuity (VA). Her medical history revealed a mild grade systemic hypertension. She did not report any other systemic disease. At the ophthalmological examination, the VA was 20/50 (Snellen Fraction) in both the right and left eyes. At the slit lamp examination, the anterior chamber was deep and optically empty. Anterior segment examination yielded unremarkable findings. Limbal anterior chamber depth, graded at slit lamp biomicroscope by Van Herick test, showed an open angle in both eyes. Applanation tonometry was 16 mmHg and 15 mmHg in the right and the left eye, respectively. Ultrasonic pachymetry showed a central corneal thickness of μm 565 in the Right Eye (RE) and 555 in the Left Eye (LE). Dilated fundus examination showed multiple, white-centered, preretinal and intraretinal hemorrhages, cotton-wool spots, retinal venous tortuosity, and whitish retinal infiltrates with prevalent perivascular localization. The clinical picture was compatible with a diagnosis of bilateral leukemic retinopathy with Roth's spots (Figure 1a). An OCT examination was then performed using the "Posterior Pole" scanning protocol of the SD-OCT Spectralis (Heidelberg Engineering, Heidelberg, Germany) comprising 61 single axial scans (scanning area: $30^\circ \times 25^\circ$) centered on the fovea, with a fovea-to-disc inclination of 7° . At baseline, SD-OCT showed the presence of spheroidal multiple focal accumulations of hyperreflective material in the inner retinal layers overhanging the external layers on which they projected a shadow, with partial disruption of adjacent retinal structure associated with multiple small hyperreflective focal dots in the inner nuclear layer (Figure 1c). A thickening of the retina, more pronounced in correspondence of Roth's spots, was documented in the entire Posterior Pole SD-OCT scan (Figure 1b). Functional data were obtained by Nidek MP-1 fundus-perimetry (software 1.7.3, Nidek Technologies Srl., Vigonza, PD, Italy) using a microperimetry program pattern that allows a point-to-point topographical overlapping of the differential light sensitivity values to the previously obtained SD-OCT volumetric data [9]. Such morpho-functional assessment (SD-OCT + fundus perimetry) of the retinal posterior pole was performed in both eyes by the same experienced operator (Figure 1b).

Noteworthy, the mean differential light sensitivity (DLS) at the baseline in RE was 16,8 dB and the bivariate contour ellipse area (BCEA) (68,2) was $4.99^\circ 2$; in the LE the mean DLS was 18 dB and the BCEA (68,2) was $2.81^\circ 2$, suggesting a central involvement of both eyes. The patient also underwent retinal fluorescein angiography and indocyanine green angiography.

The fluorescein angiography revealed normal vascular filling, blocking hypofluorescence determined by the hemorrhages, no leakage, perivascular miliary microaneurysms, venous tortuosity, and moderate peripheral retinal ischemia. Peripheral white hyperfluorescent spots were also found at indocyanine green angiography. The patient was promptly sent to onco-hematological wide counseling. The routine blood test showed a hyperleukocytosis ($436 \times 10^3/\text{mm}^3$), with high absolute neutrophil counts, low hemoglobin (10.3 g/dL), and low platelet count ($130 \times 10^3/\text{mm}^3$).

The CT showed splenomegaly and the peripheral blood smear showed marked leukocytosis with a range of immature cells compatible with CML. The diagnosis of CML was confirmed by the detection of the BCR-ABL gene (p210 b3a2 type) by quantitative Real Time-PCR, which showed positivity of 99% of the analyzed cells. The patient underwent cytoreductive therapy with Hydroxyurea that produced a clear improvement of the hematologic parameters paralleled by a slight improvement of SD-OCT features at one-week ophthalmological follow-up (Figure 2a). A 400mg Imatinib mesylate (Gleevec) therapy was then instituted by the onco-hematologist; this led to a progressive improvement of retinal lesions observed at 2 weeks and one-month ophthalmologic follow-up (Figure 2b-c), concurrently with normalization of blood cells counts, with a cytogenetic response of 2,71% BCR-ABL P210 at three months. At four months follow-up evaluation the patient reported an improvement of the ophthalmic symptoms and a VA of 20/20 in both eyes. An almost complete resolution of Roth's spots and the other signs of leukemic retinopathy was observed (Figure 2d-e).

The ophthalmic assessments were documented by the same morpho-functional evaluation performed at baseline. Sustained

therapeutic response was reported yearly, with a BCR-ABL P210 transcription level lower than 1%. A complete ophthalmologic follow-up was also scheduled annually. A progressive SD-OCT amelioration in the volumetric analysis was reported yearly, showing the resolution of the hemorrhages and the leukemic retinopathy improvement after the medical therapy, as shown by the overlapping of the fundus perimetry results to the OCT map (Figure 3a-3c). The mean DLS at the last FP examination was improved (19,4 dB in RE and 19,8 dB in LE). The BCEA (68,2) was $3.97^{\circ 2}$ in RE and $4.77^{\circ 2}$ in LE. An Optical Coherence Tomography Angiography (OCTA) exam was also obtained in the last follow-up (Figure 3d).

The OCTA examination was performed using an Angio Retina mode 6x6 mm scanning protocol (Optovue, Inc., software version 2018.1.0.22, Fremont, CA) in the macular area. Unfortunately, this interesting tool was not available in 2012, and we were not able to produce a follow-up comparison from the baseline. However, unlike the structural SD-OCT data, which showed normal values in the last follow-up, the OCTA examination revealed a widespread reduction in the vessel density (VD) of the macular plexuses. This alteration was present in both superficial and deep retinal plexuses and especially in the LE (Figure 3d). The whole image VD in LE resulted in 46,0% and 43,7 % in superficial and deep capillary plexus, respectively. They were worse than in the RE in which the superficial whole image VD was 52,5% and deep whole image VD was 61,4 %. Such results reflect the more impressive involvement of the LE at the onset of the retinopathy (Figure 1a) and they suggest the possibility to detect by OCTA long-term effects of leukemic retinopathy even after many years from the resolution of the clinical picture.

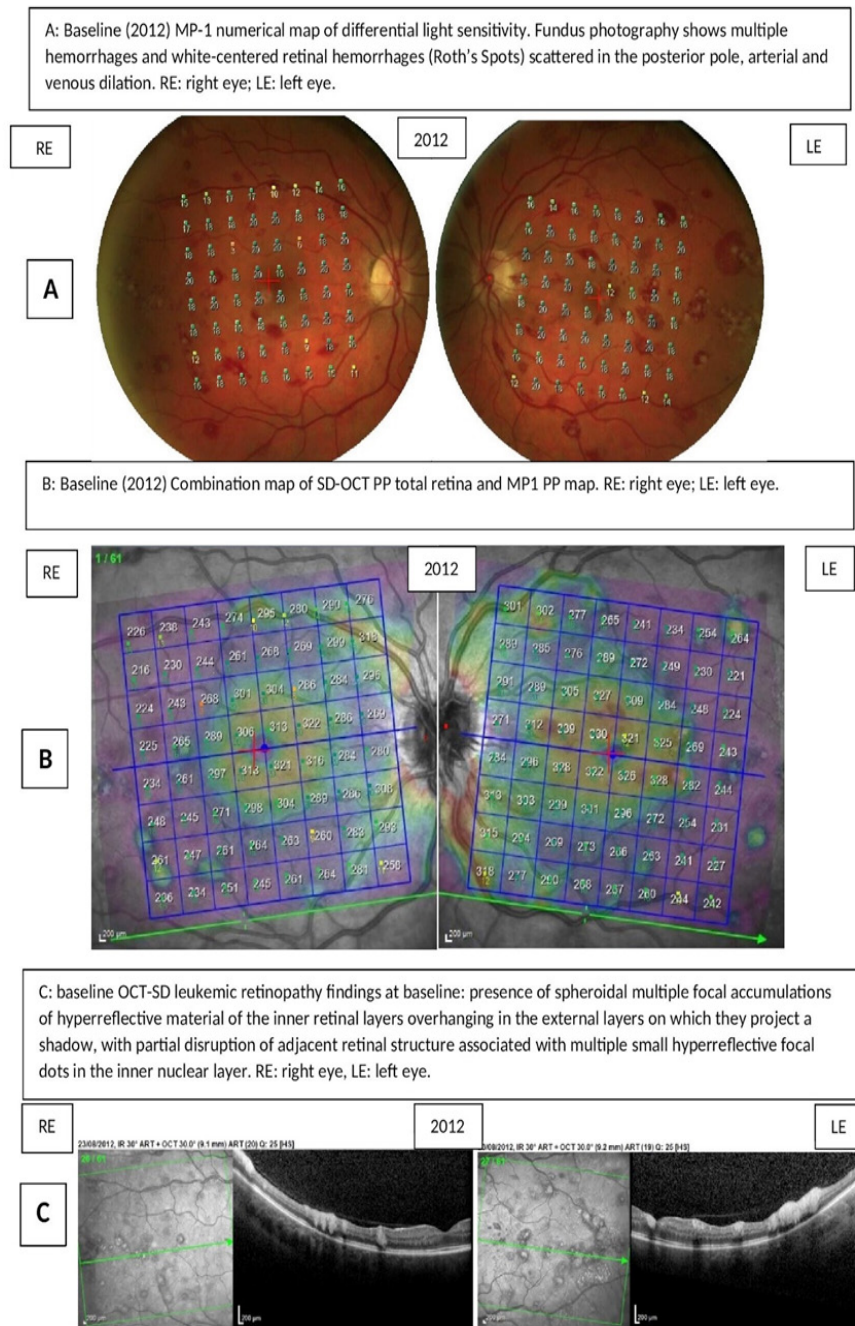


Figure 1: A: Baseline (2012) MP-1 numerical map of differential light sensitivity. Fundus photography shows multiple hemorrhages and white-centered retinal hemorrhages (Roth's Spots) scattered in the posterior pole, arterial and venous dilation. RE: right eye; LE: left eye. B: Baseline (2012) Colocalization map of SD-OCT Posterior Pole total retina and MP1 Posterior Pole map. RE: right eye; LE: left eye. C: OCT-SD leukemic retinopathy findings at baseline: the presence of spheroidal multiple focal accumulations of hyperreflective material of the inner retinal layers overhanging in the external layers on which they project a shadow, with partial disruption of adjacent retinal structure associated with multiple small hyperreflective focal dots in the inner nuclear layer and foveal involvement in the LE. RE: right eye, LE: left eye.

OCT-SD leukemic retinopathy findings improvement at one week after the institution of Hydroxyurea therapy (A) and two (B) weeks, one (C), two (D), four (E) months after starting therapy with Imatinib mesylate. RE: right eye, LE: left eye.

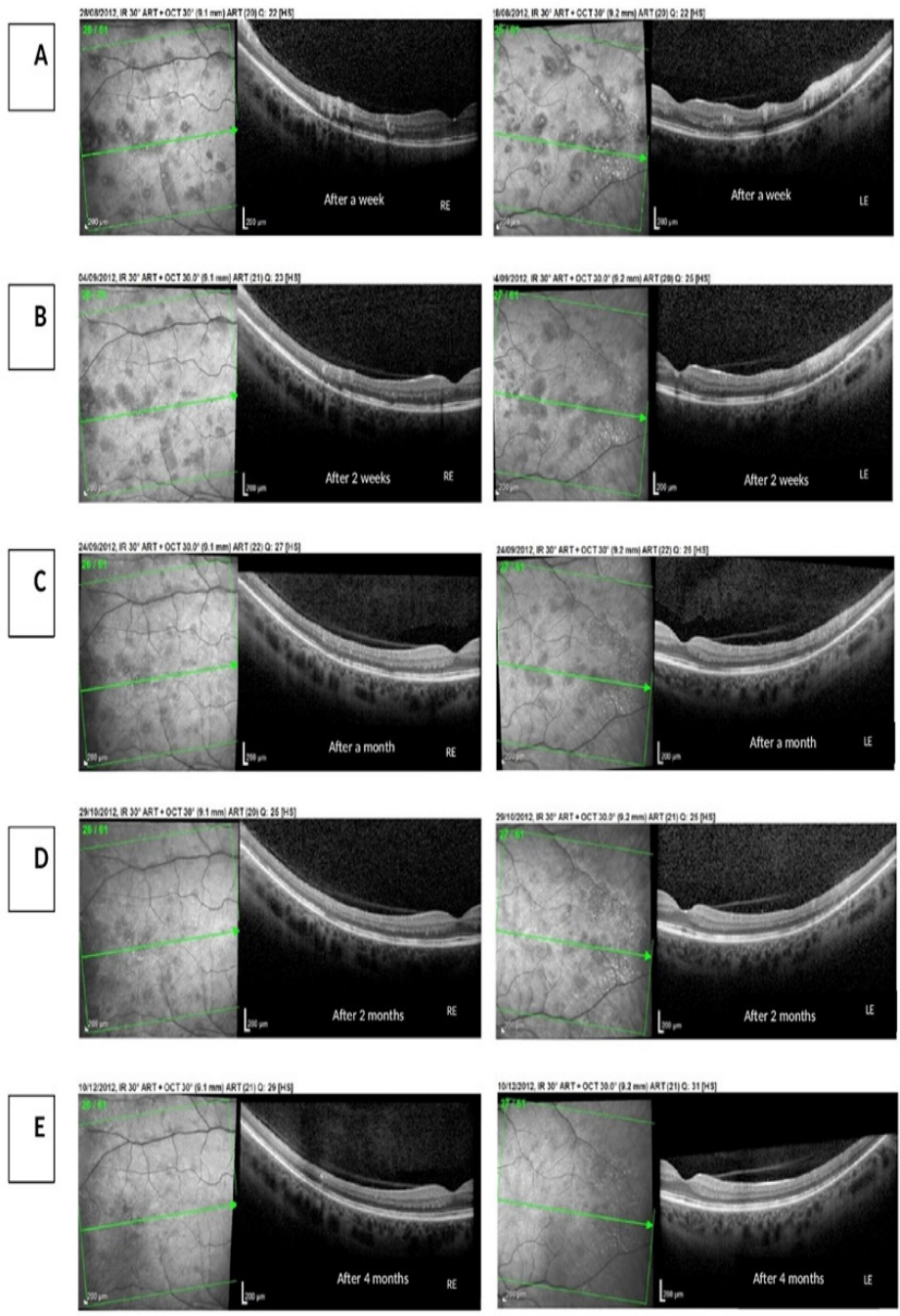


Figure 2: OCT-SD leukemic retinopathy findings improvement at one week after the institution of Hydroxyurea therapy (A) and two (B) weeks, one (C), two (D), four (E) months after starting therapy with Imatinib mesylate. RE: right eye, LE: left eye.

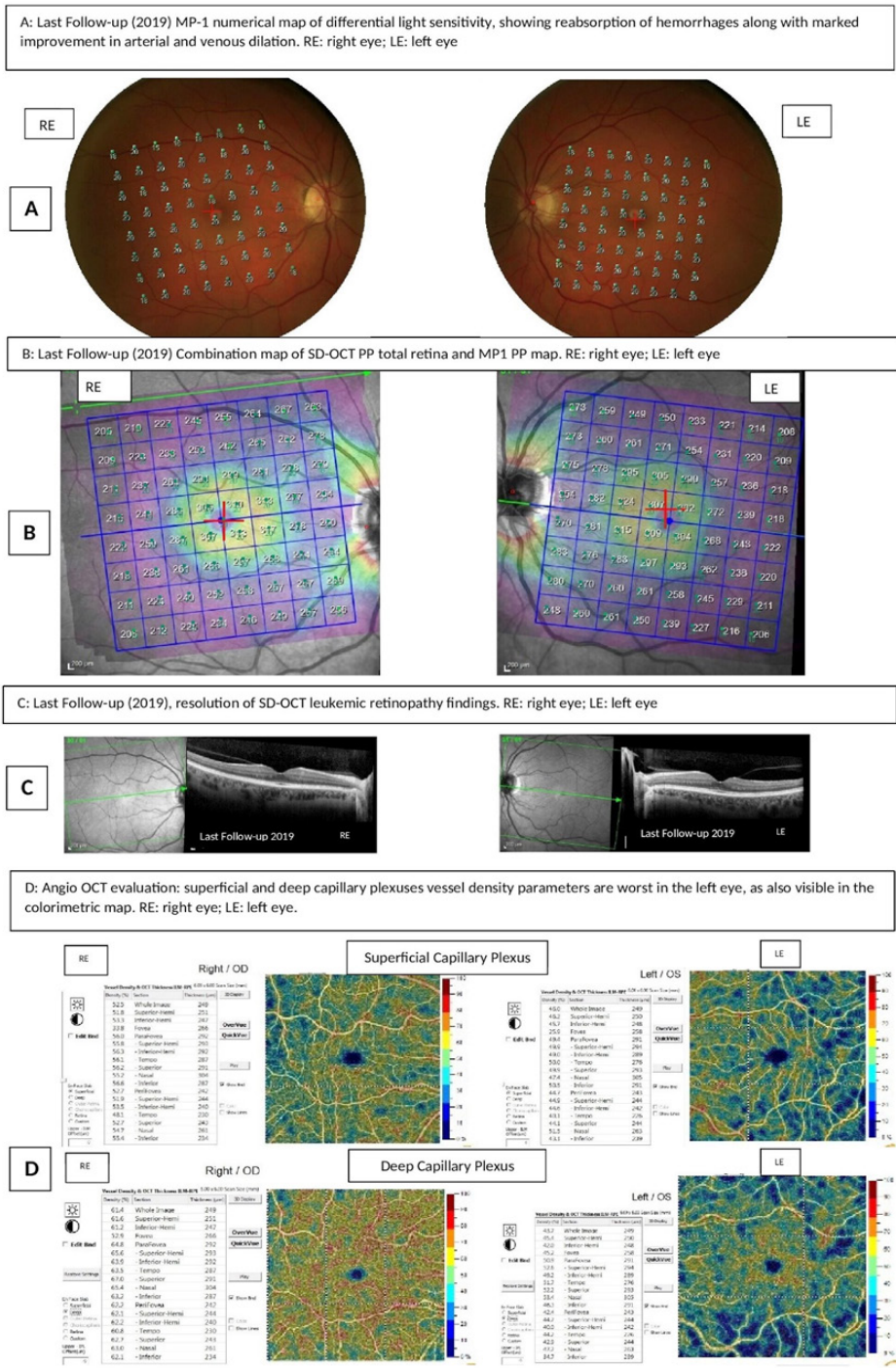


Figure 3: A: Last Follow-up (2019) MP-1 numerical map of differential light sensitivity, showing reabsorption of hemorrhages along with marked improvement in arterial and venous dilation. RE: right eye; LE: left eye. B: Last Follow-up (2019) Colocalization map of SD-OCT PP total retina and MP1 PP map. RE: right eye; LE: left eye. C: Last Follow-up (2019), resolution of SD-OCT leukemic retinopathy findings. RE: right eye; LE: left eye. D: Angio OCT evaluation: superficial and deep capillary plexuses vessel density parameters are worst in the left eye, as also visible in the colorimetric map. RE: right eye; LE: left eye.

Discussion and Conclusion

The role of ophthalmic assessment in the diagnosis of CML was already documented in the literature [5,10,11]. Currently, there are no studies that used fundus perimetry to evaluate DLS in CML. As far as we know, this is the first long-term follow-up report of CML retinopathy using the original method that allows colocalization of DLS values onto SD-OCT maps [9]. In this way, we noted that the mean DLS values at the onset of the retinopathy were reduced and then they showed long-term improvement parallel with the structural parameters; although we performed FP examination, as suggested by other authors [12], we did not find significant impairments of DLS as well as alterations in the retinal structure at the level of the retinal areas that were affected by the retinopathy (Roth's spots and hemorrhages). In this case, the structure-function colocalization allowed us to observe that important but short-lasting alterations of the inner retinal layers did not determine relevant morpho-functional changes. Unfortunately, the OCTA was only available since the last follow-up and it was not possible to perform it from the beginning, however, the vessel density obtained by OCTA 7 years after the onset of the retinopathy was more markedly reduced in the left eye than in the right eye, reflecting the more pronounced retinopathy with parafoveal involvement at the onset (Figure 1C). The reduction in vessel density found years after the resolution of the morphological (as measured by SD-OCT) and functional (as measured by FP) picture could represent the effect of the ischemic insult from leukocytosis and leukostasis as reported by Liu et al [12] and could be one of the subclinical documentable alterations caused by the previous leukemic retinopathy, even years later. To date, there is only a prospective observational study on the OCTA assessment in patients with CML with a follow-up of 5,5 months after starting therapy [12], that confirms the evidence of vessel density impairment. In this clinical case, the results detected by FP, SD-OCT, and OCTA examinations proofed the usefulness of monitoring over time the effects of specific therapy on leukemic retinopathy. These measurements are non-invasive, repeatable, simple to obtain, and were used successfully in different systemic diseases [9,13]. The potential of this multimodal approach in the diagnosis and monitoring of such retinopathies appears to be interesting. Further investigations, hopefully, sources of stronger scientific evidence, are needed.

Author's Contribution

CG and MDM made significant contributions in designing and drafting the manuscript, as well as reviewing the literature, and were involved in the assessment and diagnosis of the case.

They equally contributed as first authors. RM and CN participated in case report design and coordination and helped to draft the manuscript. MC supervised case report ideation, realization, and conclusions. All the authors contributed to the manuscript revision and gave final approval for publication.

Consent for Publication

Written informed consent was obtained from the patient for publication of this case report and any accompanying images. A copy of the written consent is available for review by the Editor-in-Chief of this journal.

References

1. Zhou T, Medeiro L J, Hu S. (2018) Chronic Myeloid Leukemia: Beyond BCR-ABL1. *Current hematologic malignancy reports*, 13: 435-445.
2. Sawyers C L. (1999) Chronic myeloid leukemia. *The New England journal of medicine*, 340: 1330-1340.
3. Talcott KE, Garg RJ, & Garg SJ. (2016) Ophthalmic manifestations of leukemia. *Current opinion in ophthalmology*, 27: 545-551.
4. Vicini G, Nicolosi C, Malandrino D, Tozzetti C, Rizzo S, et al. (2020) Leukostasis retinopathy with leukemic infiltrates as onset manifestation of chronic myeloid leukemia: a case report. *Eur J Ophthalmol*. 31: NP116-NP121.
5. Christiansen JS, Gaddh M, Wells J. (2020) An uncommon presentation of chronic myeloid leukemia. *Ann Hematol*. 99: 357-358.
6. Khalsa A, Agarwal T, Padhi TR. (2021) Chronic myeloid leukaemia-associated retinopathy. *BMJ Case Rep*. 14: e237662.
7. Seraly MP, Gupta SK, Mehmi I, Veltri L, Ghorayeb GR. (2019) A unique case of chronic myeloid leukemia presenting as monocular vision loss with unilateral retinopathy. *Am J Ophthalmol Case Rep*. 14: 67-69.
8. Goel S, Saroya A, Agrawal BK, Gogia K. (2021) Leukaemic retinopathy in a patient with chronic myeloid leukaemia. *Clin Exp Optom*. 9: 1-2.
9. Cesareo M, Ciuffoletti E, Martucci A, Sebastiani J, Sorge RP, et al. (2017) Assessment of the retinal posterior pole in dominant optic atrophy by spectral-domain optical coherence tomography and microperimetry. *PLoS One*. 12: e0174560.
10. Kumar V, Kumawat D, Dhakal S. (2018) Leukemic retinopathy and foveal infiltrates. *Int Ophthalmol*. 38: 1301-1303.
11. Reddy SC, Jackson N, and Menon BS. (2003) Ocular involvement in leukemia—a study of 288 cases. *Ophthalmologica* 217: 441-445.
12. Liu TYA, Smith BD, Mackey K, Linz MO, Scott AW. (2019) Retinal Vascular Changes on Optical Coherence Tomography Angiography and Ultra-widefield Fluorescein Angiography in Patients with Chronic Leukemia. *Journal of VitreoRetinal Diseases*. 3: 420-427.
13. Di Marino M, Cesareo M, Aloe G, Nucci C, Giannini C, et al. (2020) Retinal and Choroidal Vasculature in Patients with Marfan Syndrome. *Transl Vis Sci Technol*. 9: 5.