

Case Report

Seaweed Bezoar with Severe Gastric Pouch Dilation Post Roux-en-Y Gastric Bypass

Mark E. Mahan¹, Benjamin Rutta², Ryan D. Horsley^{1*}¹Geisinger Community Medical Center, Scranton, PA, USA²Geisinger Commonwealth School of Medicine, Scranton, PA, USA

***Corresponding author:** Ryan D. Horsley, Department of MIS & Metabolic Surgery, Geisinger Community Medical Center, 1800 Mulberry St, Scranton, PA 18510, USA. Tel: +15707032070; Fax: +15707037631; Email: rdhorsley@geisinger.edu

Citation: Mahan ME, Rutta B, Horsley RD (2018) Seaweed Bezoar with Severe Gastric Pouch Dilation Post Roux-en-Y Gastric Bypass. Arch Surg Clin Case Rep: ASCR-104. DOI: 10.29011/ASCR-104/100004

Received Date: 29 May, 2018; **Accepted Date:** 06 June, 2018; **Published Date:** 14 June, 2018

Case Report

A 61-year-old female with past medical history significant for peptic ulcer disease, open Roux-en-Y gastric bypass, performed over 20 years prior, and recurrent incisional hernia repair presented to her local Emergency Department (ED) with chief complaint of epigastric pain associated with nausea, vomiting, anorexia and constipation. Before presenting to the ED, she was evaluated by her primary care physician and prescribed Sucralfate, with presumed ulcer exacerbation. Despite medical therapy, her pain continued to progress throughout the week. On questioning it was found her discomfort began after consumption of a large seaweed salad 10 days prior.

Keywords: Bezoar; Gastric Bypass; Roux-en-Y Gastric Bypass; Seaweed Bezoar

Case

Abdomen and pelvis Computed Tomography (CT) with Intravenous (IV) contrast, revealed a severely dilated, 9.54 x 6.85 cm gastric pouch, containing retained debris extending into the gastrojejunostomy (Figures 1 & 2). Findings were deemed

suspicious for obstruction due to retained food debris/bezoar with associated inflammatory changes. An anastomotic ulcer could not be evaluated due to retained debris. There were no definitive findings to suggest perforation.

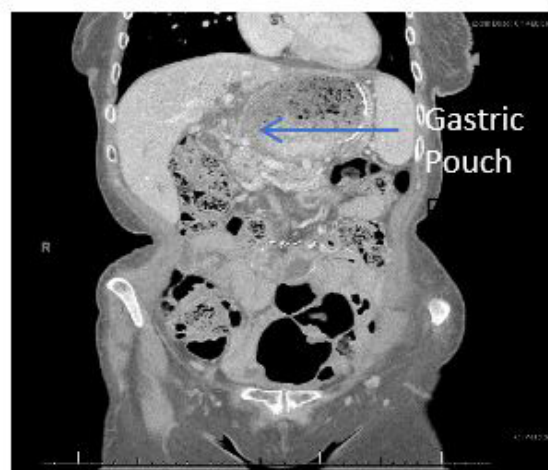

Figure 1: Abdominal CT with IV contrast showing gastric-pouch dilation (coronal plane).

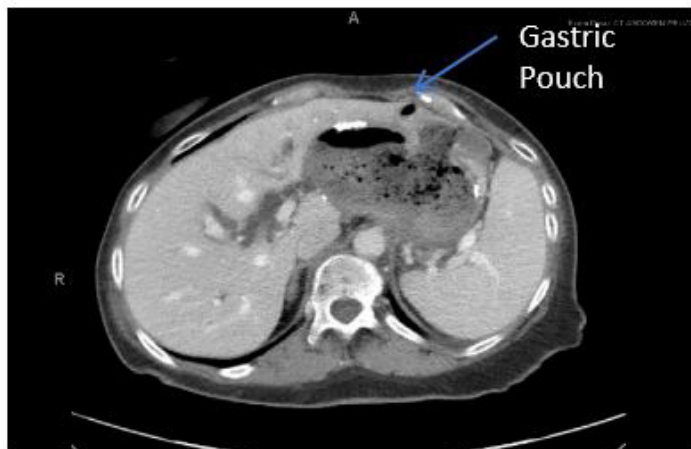


Figure 2: Abdominal CT with IV contrast showing gastric-pouch dilation (axial plane).

The patient was admitted to the hospital and underwent an upper endoscopy. The lower third of the esophagus was found to be moderately tortuous, with a dilated gastric pouch containing a bezoar with large amount of food debris (Figure 3). The pouch-to-jejunum limb measured approximately 7cm from the anastomosis to Z-line. Food debris was cleared using biopsy forceps, roth nets, and an Edlich gastric lavage kit; using greater than 3500cc of sterile water. The patient tolerated the procedure well. She was started on a full liquid diet and discharged the following day.

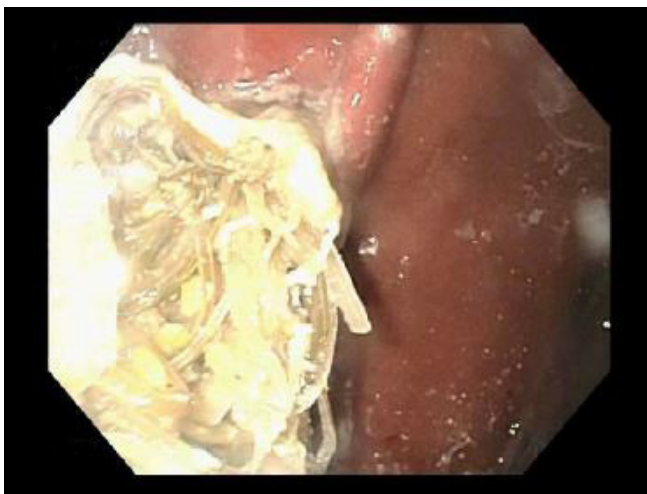

Figure 3: Gastric Bezoar above Gastrojejunostomy as visualized during endoscopy.

Although gastric bezoars are uncommon, incidence is increased in those who have undergone a gastric reducing procedure [1]. Bezoars of the alimentary tract are most commonly composed of cellulose products (phytobezoar) [2]. However, after bariatric procedures bezoars have been documented to include unusual compositions including but not limited to: sutures, staples, and cardboard [3]. Bezoar formation is hypothesized to occur secondarily to altered anatomy, subsequent reduction in gastric motility, loss of pyloric function and hypoacidity [2]. Threshold for CT imaging should be low in those with history of bariatric surgery, regardless of date, whom present with dysphagia and epigastric discomfort [4]. For those in whom gastric bezoar is suspected, upper endoscopy is a highly effective and safe therapeutic intervention. We recommend upper endoscopy as the initial therapeutic modality of choice for those with gastric bezoar following Roux-en-Y gastric bypass.

Disclosures

All authors included have no associations that may be a conflict of interest in relation to this article.

Acknowledgements

All authors included have received no financial or other substantive assistance for the funding of this work.

References

1. Pinto D, Carrodeguas L, Soto F, Lascano C, Cho M, et al. (2006) Gastric Bezoar after Laparoscopic Roux-en-Y Gastric Bypass. *Obesity Surgery* 16: 365-368.
2. Ben-Porar T, Dagan SS, Goldenschluger A, Yuval JB, Elazary R, et al. (2016) Gastrointestinal phytobezoar following bariatric surgery: Systemic review. *Surgery for Obesity and Related Diseases* 12: 1747-1754.
3. Wendell P, Gibbs K (2010) Cardboard bezoar complicating laparoscopic gastric bypass. *Surgery for Obesity and Related Diseases* 6: 313-315.
4. Gero D, Chosidow D, Marmuse JP (2015) An unusual cause of solid food intolerance and gastric pouch dilation 5 years after Roux-en Y gastric bypass: agar-agar bezoar. *Surgery for Obesity and Related Diseases* 11: 1184-1185.