

## Case Report

Zhang Y, et al. J Pharma Pharma Sci 02: JPPS-145.  
DOI: 10.29011/2574-7711.100045

# Pseudo Angiomatous Stromal Hyperplasia of the Breast: A Case of A 19-Year-Old Asian Girl

Yuzhu Zhang<sup>1</sup>, Weihong Zhang<sup>1</sup>, Yijia Bao<sup>1</sup>, Yongxi Yuan<sup>2\*</sup>

<sup>1</sup>Department of Mammary gland, Huashan Hospital, Shanghai Medical College, Fudan University, Shanghai, China

<sup>2</sup>Department of Mammary gland, Longhua Hospital Affiliated to Shanghai University of TCM, Shanghai, China

**\*Corresponding author:** Yongxi Yuan, Department of Mammary gland, Longhua Hospital Affiliated to Shanghai University of TCM, No.725, Wanping South Road, Xuhui District, Shanghai, 200032, China. Tel: +8602164383725; Email: zyzideal@aliyun.com

**Citation:** Zhang Y, Zhang W, Bao Y, Yuan Y (2017) Pseudo angiomatous stromal hyperplasia of the breast: A case of a 19-year-old Asian Girl Running title: Breast PASH in a 19-year-old Asian girl. J Pharma Pharma Sci 02: 145. DOI: 10.29011/2574-7711.100045

**Received Date:** 6 October, 2017; **Accepted Date:** 16 October, 2017; **Published Date:** 24 October, 2017

### Abstract

Pseudo Angiomatous Stromal Hyperplasia (PASH), a benign disease with extremely low incidence, is manifested as giant breasts, frequent relapse after surgery, or endocrine disorder. Cases with unilateral breast and undetailed endocrine condition have been reported in African and American. In this case, a 19-year-old Asian girl suffered from bilateral breast PASH after the human placenta and progesterone treatment for 3-month delayed menstruation. Her breasts enlarged remarkably 1 month after the treatment, with extensive inflammatory swell in bilateral mammary glands and subcutaneous edema in retro mammary space. The patient received the bilateral quadrantectomy plus breast reduction and suspension surgery to terminate the progressive hyperplasia of breast. During the whole treatment period, the patient was given tamoxifen treatment for 4 months, and endocrine levels were intensively recorded. The follow-up after 4 months showed recovered breast with normal shape and size, and there was no distending pain, a tendency toward breast hyperplasia, or menstrual disorder. Level of Evidence: Level IV, case study.

**Keywords:** Pseudo angiomatous stromal hyperplasia; 19-year-old Asian girl; Tamoxifen

### Introduction

Pseudo Angiomatous Stromal Hyperplasia (PASH) was first reported by Vuitch et al. in and it is a benign disease [1,2]. PASH is normally seen in women aged 10 to 52, and it attacks the mammary gland, axilla, and perineal regions. Although PASH has typical symptoms like giant hypertrophy, it is difficult to distinguish PASH from mastitis, fibro-adenoma, or malignant cancer when it occurs in the breast. Cases with unilateral breast and undetailed endocrine condition have been reported in African and American.

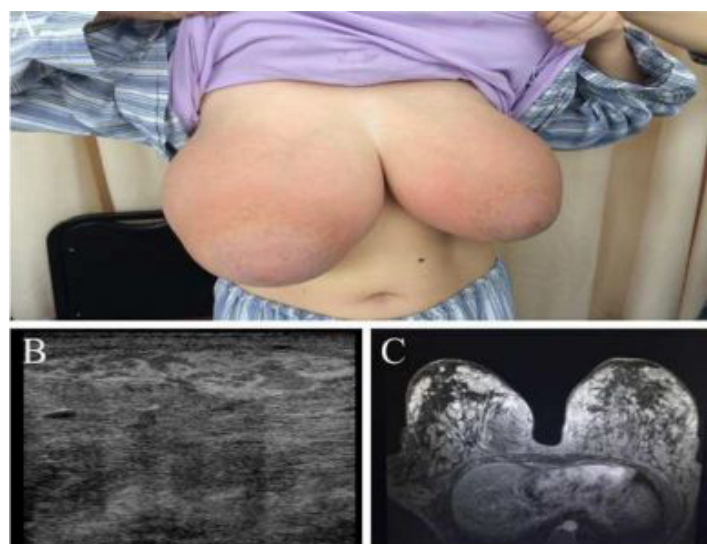
American. In addition, the etiology for PASH is now still unclear, and the characterized pathogenic symptoms are diffused hyperplasia of the breast tissue, ductal hyperplasia, CD34++, CD31+ (Blood Vessel) [3]. Most commonly used treatments include mastectomy and excision of subcutaneous gland. However, it relapses easily after surgery [4-6], and tamoxifen is a recommended drug for PASH treatment [7]. Here we reported a rare case

with bilateral PASH in a 19-years-old Asian girl.

### Case Report

The patient was a 19-year-old girl, who firstly came to hospital for the treatment of 3-month delayed menstruation. She was given a combination therapy of human placenta and progesterone. However, menstruation was not recovered, and she suffered from obvious swelling and discomfort of both breasts during the period of medication. Her breasts were significantly enlarged, and she had a heavy and tense feeling in the neck and shoulder. After four months' treatment, skin flush was identified in both breasts without obvious incentive, as well as comparatively higher temperature in the skin. Therefore, the patient went to hospital again, and B-ultrasonography showed abnormal local echo of right breast. Moreover, the axillary lymph node on the right side can be detected. The patient was advised to stop all medication treatment. Soon, the patient asked to be admitted to our hospital to take a surgery as her life was seriously affected by the huge breasts and intensive tense feeling in the shoulders. After admission, the patient received thorough examination. It was found that the breasts were

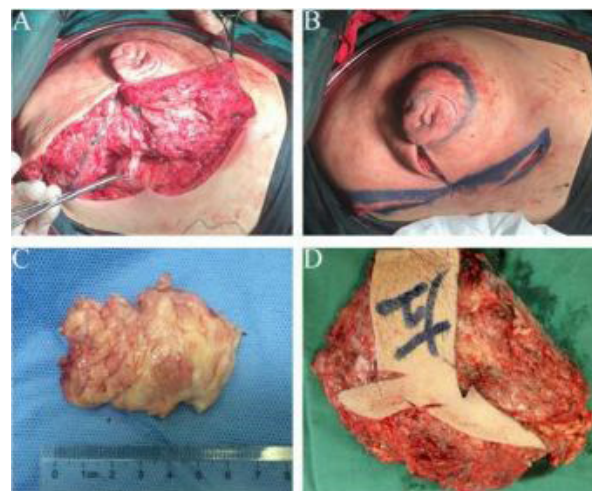
giant, asymmetric, and pendulous, while there was no blood or fluid 65 dripping out of the breast papilla (Figure 1A). Toughened hyperplasia-like nodules could be detected in all quadrants of the breast, with blurred boundaries and pressing pain. Blood routine examination test showed that leukocyte ( $6.97 \times 10^9/L$ ), hemoglobin (133g/L), estradiol (38 pg/mL), progesterone ( $<0.3$  nmol/L), prolactin (466.06 mIU/L), follicle stimulating hormone (3.83 IU/L), luteinizing hormone (6.57 IU/L), and testosterone (0.84 nmol/L) were all within the normal range. B-ultrasonography showed the bilateral breasts became thicker than normal ones, and breast ducts were wider, suggesting cyclomastopathy (Figure 1B). Magnetic Resonance Imaging (MRI) further confirmed the extensive inflammation in both breasts, accompanied by small subcutaneous abscesses in the retro mammary space (Figure 1C).



**Figure 1(A-C):** Breasts Before Surgery.

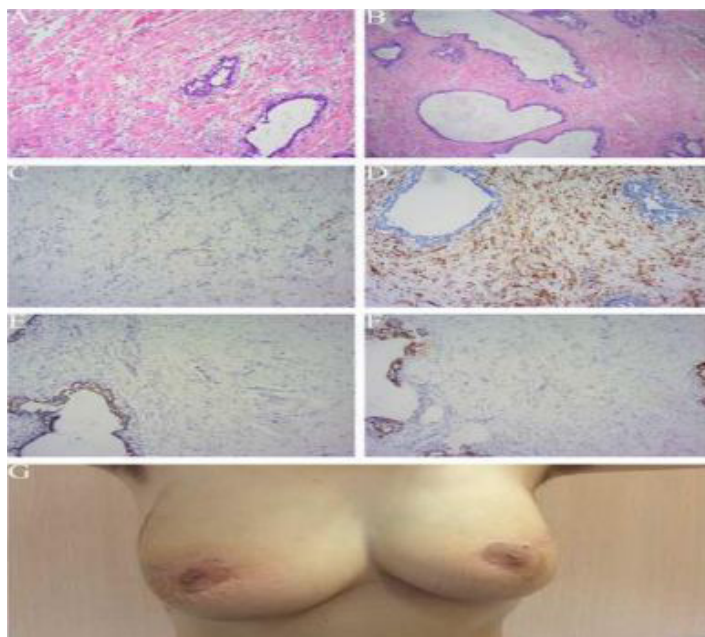
The patient underwent the bilateral quadrantectomy plus breast reduction and suspension surgery. A maple leaf-shaped incision was performed around the mammary areola and the outer side of both the lower and upper areas (Figure 2A), and this incision was interruptedly sutured, resulting in an inverted T-shaped scar (Figure 2B). With the size of  $6.5 \text{ cm} \times 5.0 \text{ cm} \times 4.0 \text{ cm}$ , the lump in the right breast was about 1500 g, of which about 500 g was

exuded from breast tissues and subcutaneous (Figure 2C). With the size of  $6 \text{ cm} \times 5 \text{ cm} \times 3.5 \text{ cm}$ , the lump in the right breast was about 1200 g, of which approximately 350 g was exuded seen from lump surface (Figure 2D).



**Figure 2(A-D):** The Bilateral Quadrantectomy Plus Breast Reduction and Suspension Surgery.

Paraffin section analysis confirmed the breast hyperplasia. There was florid hyperplasia in partial ductal luminal epithelium, hyperplasia in interstitial fibrous tissues, PASH in partial zone of the breast, as well as local mucoid degeneration (Figure 3A and B). There were crack-like anastomosed cavities surrounding internal spindle cells, and these phenomena indicated a breast hypertrophy in puberty. In the skin of mammary areola, hyperplasia was seen in squamous epithelium, and inflammatory cells infiltrated in local dermal perivascular area. Immunohistochemistry results showed CD31 + in blood vessel (Figure 3C), CD34++ in breast tissue (Figure 3D), ER++ in epithelium (Figure 3E), ER- in mesothelium, PR++ in epithelium (Figure 3F), and PR- in mesothelium. After surgery, the patient was given tamoxifen (oral, 1 tablet, b.i.d) as an endocrine therapy. During the 4 months' follow-up, no progressive hyperplasia of breast was identified, and bilateral breasts returned to normal shape with no necrosis in nipple or (Figure 3G). Skin of the breast recovered to be soft and elastic, and no swelling, pain, or tenderness was found. Moreover, the patient had no abnormal feelings.



**Figure 3(A-G):** Paraffin Section Analysis of Breast Tissues and The Breasts 4 Months After Surgery.

## Discussion

With unclear etiology, this is a very rare breast PASH case in clinic. Adolescent menstrual disorders have been extensively reported clinically, and it is usually associated with the undeveloped ovarian function. In Western medicine theory, regulating hormone levels, such as progesterone injection or oral administration, was usually utilized to treat this disorder. In traditional Chinese medicine theory, human placental is normally used to treat menstrual disorder, as it can warm kidney, boost essence, and benefit Qi and blood. It is found that there are rich estrogen and progesterone in human placental [8]. Therefore, the progesterone and placental taken in a short time might be a possible reason for the development of giant breasts in this case. However, estrogen, progesterone, and prolactin were all in normal range at the time of admission, and menstruation returned to normal after the surgery. Thus, endocrine dyscrasia is just a potential reason rather than a confirmed reason for breast PASH in this case, and we will devote more effort to investigate the possible etiological factor and pathogenesis. Tamoxifen has been successfully used to treat a PASH case [7,9], and thus tamoxifen was also used after the surgery in this case considering the positive receptors for estrogen and progesterone. After tamoxifen treatment, breast distending pain was significantly alleviated, and less exudate was secreted, accelerating wound healing. In addition, none of PASH symptoms relapsed during the 4 months of follow-up, indicating that tamoxifen might be an efficient therapy for breast PASH. To our knowledge, this is the second report on the successful use of tamoxifen in the management of breast

PASH. Thus, for the patients with extensive and dispersion nidus (not tumor proved by breast biopsy), positive ER, and positive PR, endocrine therapy like tamoxifen is recommended to be utilized directly after local resection.

What is more, for those with strong and positive response to endocrine therapy, resection might not be necessary. More cases should be observed to figure out whether this recommendation will work in the further. Many authors advocate the use of wide local excision in treating PASH due to its uncertain natural history, but we are more inclined to use individualized therapies. For instance, endocrine therapy was recommended for the patient with positive ER and PR in this case. Surgeries should also be chosen based on individual conditions. For example, local appearance post-surgery should be considered for young patient, and thus we recommend local wide excision of the lesions or subcutaneous gland excision plus prosthesis implantation. For old or postmenopausal patients with no special request regarding breast appearance, subcutaneous resection of breast can be performed to avoid recurrence. Subcutaneous resection of breast or interval procedure should be considered for PASH patients with diffused hyperplasia. For patients with comorbidity, biopsy should be conducted to exclude the existence of tumor. Furthermore, the support from patients and their families is also very important, and patients who acknowledge and understand the complexity of PASH will cooperate with doctors to achieve efficient therapy.

## Acknowledgement

Department of Breast Surgery at Longhua Hospital for their guidance on this study, and we also want to thank MengYu Zhou in the Department of Pathology at Longhua Hospital for the pathological materials.

## References

1. Vuitch MF, Rosen PP, Erlandson RA (1986) Pseudoangiomatous hyperplasia of mammary stroma. *Human pathology* 17: 185-191.
2. Jaunoo SS, Thrush S, Dunn P (2011) Pseudoangiomatous stromal hyperplasia (PASH): a brief review. *International journal of surgery (London, England)*. *Int J Surg* 9: 20-22.
3. Drinka EK, Bargaje A, Ersahin CH, Patel P, Salhadar A, et al. (2012) Pseudoangiomatous stromal hyperplasia (PASH) of the breast: a clinicopathological study of 79 cases. *International journal of surgical pathology* 20: 54-58.
4. Baker M, Chen H, Latchaw L, Memoli V, Ornvold K (2011) Pseudoangiomatous stromal hyperplasia of the breast in a 10-year-old girl. *Journal of pediatric surgery* 46: e27-31.
5. Su CC, Chen CJ, Kuo SJ, Chen DR (2015) Myoid hamartoma of the breast with focal chondromyxoid metaplasia and pseudoangiomatous stromal hyperplasia: A case report. *Oncology letters* 9: 1787-1789.
6. Vega RM, Pechman D, Ergonul B, Gomez C, Moller MG (2015) Bilateral pseudoangiomatous stromal hyperplasia tumors in axillary male gynecomastia: report of a case. *Surgery today* 45:105-109.

**Citation:** Zhang Y, Zhang W, Bao Y, Yuan Y (2017) Pseudo angiomatous stromal hyperplasia of the breast: A case of a 19-year-old Asian Girl Running title: Breast PASH in a 19-year-old Asian girl. J Pharma Pharma Sci 02: 145. DOI: 10.29011/2574-7711.100045

---

7. Pruthi S, Reynolds C, Johnson RE, Gisvold JJ (2001) Tamoxifen in the management of pseudoangiomatous stromal hyperplasia. The breast journal 7: 434-439.
8. Hershman JM, Starnes WR (1969) Extraction and characterization of a thyrotropic material from the human placenta. The Journal of clinical investigation 48: 923-929.
9. Seltzer MH, Kintiroglou M (2003) Pseudoangiomatous hyperplasia and response to tamoxifen therapy. The breast journal 9: 344.