

Clinical & Experimental Dermatology and Therapies

Sadrolashrafi K, et al. Clin Exp Dermatol Ther: CEDT-148.

DOI: 10.29011/2575-8268/100048

Case Report

Prurigo Pigmentosa: A Less-Recognized Clinicopathologic Entity with the Potential of Misdiagnosis

Kaviyon Sadrolashrafi¹, Nathan Morgan², Narciss Mobini^{3,4*}¹University of California, Los Angeles (UCLA), Department of Life Sciences, 638 Landfair Ave, PH1, Los Angeles, CA, USA²Surgical Dermatology and Laser Center, Vivida Dermatology, 6460 Medical Center Street, Suite 350, Las Vegas, NV, USA³University of Nevada, School of Medicine, Las Vegas and Reno, Nevada, USA⁴Associated Pathologists, Chartered, 4230 Burnham Ave, Las Vegas, NV, USA

***Corresponding author:** Narciss Mobini, Associated Pathologists, Chartered, 4230 Burnham Ave. Las Vegas, NV 89119, USA. Tel: +17022196005; Email: mscons@aol.com

Citation: Sadrolashrafi K, Morgan N, Mobini N (2018) Prurigo Pigmentosa: A Less-Recognized Clinicopathologic Entity with the Potential of Misdiagnosis. Clin Exp Dermatol Ther: CEDT-148. DOI: 10.29011/2575-8268/100048

Received Date: 02 June, 2018; **Accepted Date:** 11 June, 2018; **Published Date:** 18 June, 2018

Abstract

Prurigo pigmentosa is an under-recognized clinicopathologic entity with characteristic clinical manifestations of recurrent erythematous macules, papules, papulovesicles and coalescing plaques, mainly on the neck, upper back and chest, leaving behind a reticulated pattern of pigmentation upon resolution. Histologically, depending on the stage of the disease, there is an initially a perivascular infiltrate of neutrophils, neutrophilic spongiosis, necrotic keratinocytes which evolves into a lichenoid infiltrate of admixed lymphocytes and a few eosinophils and later, pigment incontinence becomes apparent. The disease is often missed both clinically and histologically, due to unfamiliarity of dermatologists and dermatopathologists. Accordingly, the patients are often misdiagnosed as having “recurrent itchy eczematous rash, unresponsive to steroids”. Although the lesions tend to subside by themselves in each recurrence, minocycline, doxycycline and dapsone are effective in expediting the remission. Here we report a new case of prurigo pigmentosa in the United States with the intention of increasing the awareness to this entity and emphasize the critical role of strong clinicopathologic correlation in reaching an accurate diagnosis. Interestingly, we did not utilize any antibiotics for the patient, unlike the overwhelming majority of reported cases. This may suggest no medical intervention may be considered, if the symptoms are not intolerable.

Keywords: Pigmentosa; Prurigo; Neutrophilic spongiosis

Introduction

Prurigo Pigmentosa (PP), is a rare or rarely diagnosed and/or reported dermatosis, first described by Masaji Nagashima in 1971 [1,2]. In addition to Nagashima's original study, most reported cases so far are from Japan, however, less number of cases have been reported from other parts of the world such as middle Eastern and European countries, Korea and a few from the U.S. [3-9]. It appears that the lack of familiarity with this disease, both clinically and histopathologically, is the main culprit in its under-reporting in non-Japanese population. Here we present a new case of PP in a Hispanic man, whom we diagnosed based on a strong

clinicopathologic correlation. By presenting and sharing this case, we intend to add to slowly increasing number of the reported patients outside Japan, to raise the awareness of clinical dermatologists and dermatopathologists, for proper recognition and management of these patients, whom are usually not recognized or missed.

Case Report

A 22-year-old man presented with a “recurring itchy rash” on his neck and upper back. The rash has been “coming and going” in the past few years with no apparent reason or particular seasonal exacerbation. With the impression of an eczematous process or atopic dermatitis, multiple courses of topical steroid treatments had been unsuccessfully tried in relieving the symptoms or controlling

the disease. The current episode had started approximately 2 weeks prior to his visit. He was otherwise healthy, with no history of diabetes, recent dieting or fasting, medication use or weight loss. On physical examination, there were several erythematous, focally crusted papules, papulovesicles and macules with intermingled areas of reticular pigmentation on the lateral sides and nape of the neck, upper back and upper chest (Figure 1). Two biopsies were obtained from the papular and papulovesicular lesions. Histopathologic examination revealed similar findings. There was a superficial perivascular and focally lichenoid infiltrate of lymphocytes and admixed neutrophils. Neutrophils were seen in the spongiotic epidermis, as singly and also as small collections in the upper epidermal layers and subcorneal region. Focal partial necrosis of the epidermis was also present. There were scattered apoptotic keratinocytes in the adjacent skin. The surface was crusted (Figures 2A-C). A PAS stain was negative for fungi. Although histopathologic differential diagnoses included a traumatized spongiotic and lichenoid drug reaction, an unusual lichenoid contact/photo-contact or irritant dermatitis and probably PP (in the clinical context), after reviewing the clinical pictures, the diagnosis of prurigo pigmentosa was established with certainty. This clinicopathologic correlation was most beneficial to the patient who had suffered for such a long time from this bothersome non-steroid responsive itchy rash. When the patient returned within a week to be initiated on antibiotic treatment, the overwhelming majority of the erythematous papular and papulovesicular lesions had already been subsided, with some residual mottled and reticulated hyperpigmentation (Figures 3A,B). There was no more itching and therefore, he agreed not to start any antibiotic treatment in this episode.

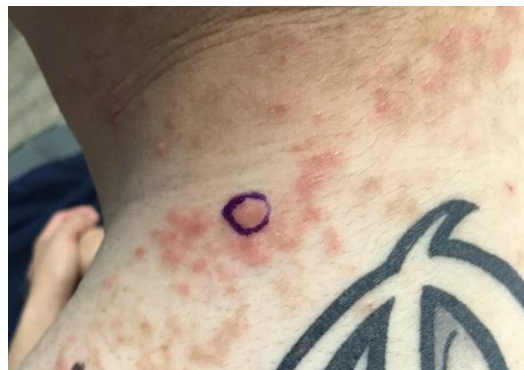

Figure 1: Erythematous individual papules, coalescing papules forming small plaques and rare papulovesicles, some excoriated, in association with mottled and reticulated pigmentation on the neck and upper back.

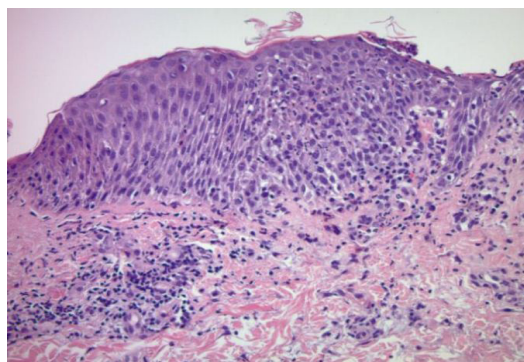
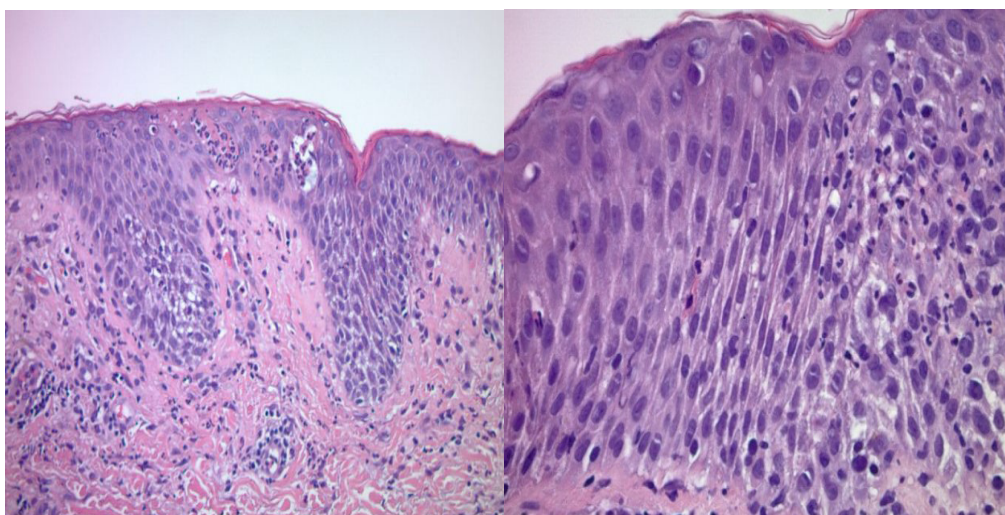
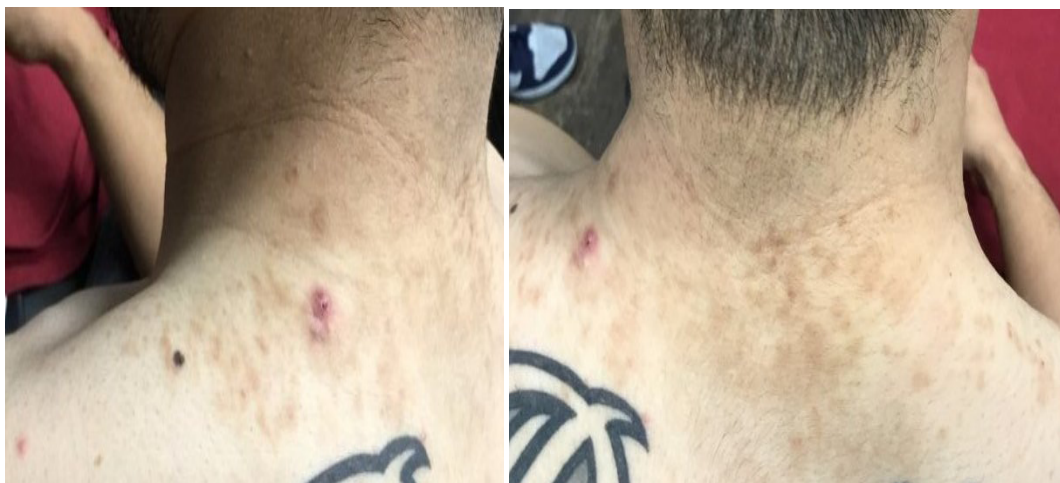

Figure 2A: Biopsy of a papular lesion, showing superficial perivascular infiltrate of lymphocytes with many neutrophils, associated with exocytosis of neutrophils into the overlying spongiotic epidermis. (hematoxylin-eosin, 10X).



Figures 2B,C: Collections of neutrophils in the epidermis, associated with both individual cell necrosis and larger foci of epidermal necrosis. (hematoxylin-eosin, 20X,40X).



Figures 3A,B: Resolving lesions, associated with resultant reticulated and mottled pigmentation.

Discussion

Prurigo Pigmentosa (PP), is a rare or rarely diagnosed and/or reported dermatosis, first described by Masaji Nagashima in 1971[1,2]. Although most reported cases in the literature belong to Japanese patients, some individual and small series with this disease have also been reported in non-Japanese population [3-10]. Cases documented from U.S. are still very small in number, less than 10 to date [11-13]. The reports indicate a higher female:male ratio, with most cases developing in the adolescent or young adults, however, the disease has also been reported in children or older patients [13]. The etiology of PP is still unclear with many candidates having been proposed as either the initiator of the disease or strongly associated with it. These include fasting, prolonged diet and ketone-induced conditions such as post-bariatric surgery [14-17]. Also, infectious etiologies such as *H. pylori* infection and bacterial folliculitis have been speculated as either associations or potential pathogenesis [18,19]. Contact allergy to chromium, nickel and an atopic diathesis are among reported associations [20-22]. Occurrence of PP in pregnancy has been reported [23]. Positivity of ANA may be a coincidence rather than a significant association [24]. Adult Still's disease has been reported in association with a PP-like eruption [25]. There appears to be increased frequency in spring and summer time [21].

- **Clinically**, the lesions of PP are centered on the trunk with particular localization to the neck, upper chest, upper and lower back in a more or less symmetrical fashion. Only rarely the forehead or arms have been affected. The lesions have a recurrent nature and once they appear, it may take about a week or two for them to subside. The reticular arrangement of the lesions is the most typical characteristic of the disease. The original early lesions are erythematous macules,

maculopapules or urticarial papules which evolve into more evident papules, papulovesicles, vesiculopustules and small plaques with signs of excoriation and crusting on the surface. The lesions eventually subside to leave behind a mottled and reticulated hyperpigmentation. The latter feature is seen mostly in non-caucasian population. Therefore, the disease has a dynamic nature and based on the stage in which the biopsy is performed, one sees different histopathologic manifestations.

- **Histopathologically**, PP has been shown to have distinctive features which correspond to the evolutionary phase of the disease [3,26]. Initially, where the lesions are in the early macular or urticarial papular stage, one sees papillary dermal edema associated with mild superficial perivascular infiltrate of lymphocytes and predominantly neutrophils with focal exocytosis. Neutrophils are usually seen in the upper parts of the epidermis, especially in the subcorneal area. There are rare necrotic keratinocytes in the epidermis. As the lesions become more established and clinically appear as papulovesicles, vesiculopustular or coalescing plaques, the histologic examination reveals a spongiotic or vesiculospongiotic and to some extent lichenoid dermatitis, with collections of neutrophils in the epidermis (neutrophilic spongiosis). Numerous necrotic keratinocytes and larger areas of epidermal necrosis (necrosis en masse) with accompanying ballooning can be seen. Inflammatory infiltrate becomes denser and eosinophils can also be present in addition to lymphocytes and neutrophils. Evidence of excoriation due to itching is sometimes present. In the later stages, the density of inflammatory infiltrate subsides with a lymphocyte dominant feature and mild spongiosis, vacuolar interface changes and scattered necrotic cells. There is overlying parakeratotic scale

crust. Especially in non-caucasians, there is an associated postinflammatory pigmentary alteration, as characterized by presence of melanophages in the papillary dermis.

The clinical differential diagnosis of PP includes allergic contact or photocontact dermatitis, lichen planus pigmentosus, confluent and reticulated papillomatosis of Gougerot-Carteaud, and less likely erythema dyschromicum perstans (late pigmented stages). However, these entities can be distinguished on a histopathologic level and based on the distinct clinical presentation of PP. Histological differential diagnosis may include a drug-induced neutrophilic and spongiotic dermatitis, photo-induced drug reaction, allergic contact or irritant dermatitis, less likely dermatitis herpetiformis, neutrophilic or connective tissue disorders. Therefore, a strong clinicopathologic correlation and reviewing the clinical pictures along with histopathologic evaluation is of utmost importance in arriving at an accurate diagnosis and proper management of the patients. Most of the time, in any given recurrence of the disease, the lesions resolve spontaneously. This was the case in our patient, where upon his second visit within a week for providing potential medical treatment, we witnessed that the majority of very itchy papules/papulovesicles had already subsided with residual pigmentation. Accordingly, we did not administer any medication and only advised him to visit us as soon as the lesions return so the treatment can be started earlier to perhaps shorten the resolution period. We plan to carry out a patch test on the patient to rule out any underlying allergic diathesis.

As this is a mostly neutrophil-mediated dermatosis, PP responds well to minocycline, doxycycline and dapsone. These drugs inhibit the chemotaxis of neutrophils in addition to being anti-inflammatory [3,26-28]. Macrolide antibiotics have been shown to be effective in patients not responding to minocycline [29]. Of interest, the disease does not respond to corticosteroids [3]. This was also the case in our patient who had been unsuccessfully treated with different strengths of topical steroids under the diagnosis of eczema for years.

Conclusion

Prurigo pigmentosa, although described as a “rare disease” in the western countries, may very well be an under-recognized clinicopathologic entity. We believe PP should be introduced and reported more often so that dermatologists and dermatopathologists become more aware and familiar with it and perform more accurate evaluation in these patients who have a rather distinctive, yet variable clinical and histopathological presentations. By this report we intend to share our findings and help raise this awareness. We emphasize on active communication between dermatology practitioner and the dermatopathologist, at least by providing information on clinical presentation and distribution pattern of the lesions. By doing so, an accurate diagnosis will be made in light of

strong clinicopathologic correlation and high index of suspicion. On the other hand, patients can be educated and managed properly, without empiric use of corticosteroids. The use of antibiotics can also be discussed with them due to the spontaneous nature of involution of the lesions. As presented in our patient, we did not prescribe any medication, due to the fact that the symptoms were improving and becoming much tolerable.

References

1. Nagashima M, Ohshiro A, Shimizu N (1971) A peculiar pruriginous dermatosis with gross reticular pigmentation. Jap J Dermatol 81: 38-39.
2. Nagashima M (1978) Prurigo pigmentosa-clinical observations of our 14 cases. J Dermatol 5: 61-67.
3. Boer A, Misago N, Wolter M, Kiryu H, Wang XD, et al. (2003) Prurigo pigmentosa: A distinctive inflammatory disease of the skin. Am J Dermatopathol 25: 117-129.
4. Boer A, Asgari M (2006) Prurigo pigmentosa: An underdiagnosed disease? Indian J Dermatol Venereol Leprol 72: 405-409.
5. Lin SH, HO JC, Cheng YW, Huang PH, Wang CY (2010) Prurigo pigmentosa: a clinical and histopathologic study of 11 cases. Chang Gung Med J 33: 157-163.
6. Kim JK, Chung WK, Chang SE, Ko JY, Lee JH, et al. (2012) Prurigo pigmentosa: clinicopathological study of 50 cases in Korea. J Dermatol 39: 891-897.
7. Asgari M, Daneshpazooch, Chams Davatchi C, Boer A (2006) Prurigo pigmentosa: An underdiagnosed disease in patients of Iranian descent? J Am Acad Dermatol 55: 131-136.
8. Baykal C, Uyukbabani N, Akinturk S, Saglik E (2006) Prurigo pigmentosa: Not an uncommon disease in the Turkish population. Int J Dermatol 45: 1164-1168.
9. Hijazi M, Kehdy J, Kibbi AG, Ghosn S (2014) Prurigo pigmentosa: A clinicopathologic study of 4 cases from the middle East. Am J Dermatopathol 36: 800-806.
10. Jeunon de Sousa Vargas T, Abreu Raposo CM, Barbora Lima R, Sampaio AL, Bordin AB, et al. (2017) Prurigo pigmentosa-Report of 3 cases from Brazil and literature review. Am J Dermatopathol 39: 267-274.
11. Slatter E, Rozelle C, Sperling L (2016) Prurigo pigmentosa: An under-recognized inflammatory dermatosis characterized by an evolution of distinctive clinicopathological features. J Cutan Pathol 43: 811-814.
12. Whang T, Kirkorian AY, Krishtul A, Phelps R, Shim-Chang H (2011) Prurigo pigmentosa: report of two cases in the United States and review of the literature. Dermatol Online J 17: 2.
13. Roehr P, Paller AS (1993) A pruritic eruption with reticular pigmentation. Prurigo pigmentosa. Arch Dermatol 129: 365-370.
14. Oh YJ, Lee MH (2012) Prurigo pigmentosa: a clinicopathologic study of 16 cases. J Eur Acad Dermatol Venereol 26: 1149-1153.
15. Michaels JD, Hoss E, DiCaudo DJ, Price H (2015) Prurigo pigmentosa after a strict ketogenic diet. Pediatr Dermatol 32: 248-251.
16. Kobayashi T, Kawada A, Hiruma M, Ishibashi, Aoki A (1996) Prurigo pigmentosa, ketonemia and diabetes mellitus. Dermatology 192: 78-80.

17. Abbas M, Abiad F, Abbas O (2015) Prurigo pigmentosa after bariatric surgery. *JAMA Dermatol* 151: 796-797.
18. Erbagci Z (2002) Prurigo pigmentosa in association with *Helicobacter pylori* infection in a Caucasian Turkish woman. *Acta Derm Venereol* 82: 302-303.
19. Kafle SU, Swe SM, Hsiao PF, Tsai YC, Wu YH (2017) Folliculitis in prurigo pigmentosa: a proposed pathogenesis based on clinical and pathological observation. *J Cutan Pathol* 44: 20-27.
20. Kim MH, Choi YW, Choi HY, Myung KB (2001) Prurigo pigmentosa from contact allergy to chrome in detergent. *Contact Dermatitis*. 44: 289-292.
21. Atasoy M, Timur H, Arslan R, Ozdemir S, Gursan N, et al. (2009) Prurigo pigmentosa in a patient with nickel sensitivity. *J Eur Acad Dermatol Venereol* 23: 228-230.
22. Kwon HJ, Kim MY, Kim HO, Park YM (2006) Two cases of prurigo pigmentosa in atopic patients. *J Dermatol* 33: 579-582.
23. Leone L, Colato C, Girolomoni G (2007) Prurigo pigmentosa in a pregnant woman. *Int J Gynaecol Obstet* 98: 261-262.
24. Park HY, Hong SP, Ahn SY, Ji JH, Choi EH, et al. (2009) Antinuclear antibodies in patients with prurigo pigmentosa: a linkage or coincidence? *Dermatology* 218: 90-91.
25. Tomaru K, Nagai Y, Ohyama N, Hasegawa M, Endo Y, et al. (2006) Adult-onset Still's disease associated with prurigo pigmentosa-like skin eruption. *J Dermatol* 33: 55-58.
26. Boer A, Ackerman AB (2003) Prurigo pigmentosa is distinctive histopathologically. *Int J Dermatol* 42: 417-418.
27. Ekmekci TR, Altunay IK, Koslu A (2006) Prurigo pigmentosa treated with doxycycline. *Dermatol Online J* 12: 9.
28. Chiam LY, Goh BK, Lim KS, Ng SK (2009) Prurigo pigmentosa: a report of two cases that responded to minocycline. *Clin Exp Dermatol* 34: e584-586.
29. Yazawa N, Ihn H, Yamane K, Etoh T, Tamaki K (2001) The successful treatment of prurigo pigmentosa with macrolide antibiotics. *Dermatology* 202: 67-69.