

Review Article

Ali AHA. J Trop Med Health: JTMH-138.

DOI: 10.29011/JTMH-138. 000038

Protection of Testis Through Antioxidant Action of Artemisia Annua (Kaysom) In Alloxan-Induced Diabetic Albino Rats

Ali Hassan A. Ali^{1,2*}¹Anatomy Department, Prince Sattam Bin Abdulaziz University, Saudi Arabia²Anatomy Department, Al-Azhar University, Egypt

***Corresponding author:** Ali Hassan A. Ali, Anatomy Department, Prince Sattam Bin Abdulaziz University, Saudi Arabia. Tel: +966115886171; Email: alihassan3750@yahoo.com; a.ali@sau.edu.sa

Citation: Ali AHA (2018) Protection of Testis Through Antioxidant Action of Artemisia Annua (Kaysom) In Alloxan-Induced Diabetic Albino Rats. J Trop Med Health: JTMH-138. DOI: 10.29011/JTMH-138. 000038

Received Date: 22 November, 2018; **Accepted Date:** 21 December, 2018; **Published Date:** 31 December, 2018

Abstract

Background: Diabetes mellitus is a common metabolic disease and widely distributed all over the world. Most diabetic patients were associated with reproductive impairments. Previous studies reported negative complications of diabetes on the male reproductive system with associated gonadal dysfunction. Medicinal plants are effective enhancer of oxidative stress associated with diabetes mellitus. The current study was aimed at assessing the importance of supplementation of Artemisia annua (Kaysom) extract in reducing the metabolic abnormalities accompanied with alloxan-induced diabetes in male albino rats.

Material and Methods: This study was conducted on thirty male albino rats with an average 100-110 g body weight. The rats were divided into three equal groups including control, diabetic and diabetic treated with Kaysom extract. One dose of alloxan (120 mg/kg body weight) was used to induce diabetes in rats. Diabetic rats were administered “28.5 mg/kg body wt. twice/day” Kaysom extract orally for 30 days.

Results: It has been detected that the morphological testicular changes noted in diabetic groups had been considerably improved after treatment with Kaysom extract compared with the control group.

Conclusion: These results explained that Kaysom extract improves diabetes induced oxidative damage in testis as well as provides protection to testis.

Keywords: Albino Rat; Alloxan; Antioxidant; Artemisia Annua (Kaysom); Testis

Introduction

Diabetes mellitus is a common metabolic disorder worldwide. It is linked to disturbances in carbohydrate, fat, and protein metabolism [1]. Experimentally, in male rats the induction of diabetes had been found to be associated with change in the function of the reproductive system. Induction of diabetes in rats was used as an in vivo model to study the effects of diabetes on the various organs [2,3]. It has been proved that induction of diabetes affects the testicular functions due to the lack of insulin and therefore the weakness of insulin regulatory action on Sertoli and Leydig cells [4]. There are several previous studies showed changes in the reproductive system structure in diabetic cases [5-7] Diabetes mellitus is a multivariate disease with imperfection in Reactive

Oxygen Species (ROS) scavenging enzymes [8]. The main reason of a number of long term complications of diabetes is chronic hyperglycemia. Protein glycation, the most important source of free radicals, is leaded by hyperglycemia. ROS produced by protein glycation and glucose oxidation mediates the pathogenic effects of high glucose. ROS can directly charged molecular and cellular damage by activating many cellular stress-sensitive pathways, which direct to late complication of diabetes [9]. Many plant secondary metabolites have shown antioxidant potential and ameliorative effect on oxidative stress induced damage in diabetes [10]. Traditional medicine practices, are considered responsible for an impartial role in primary health care despite modern medicine accessibility [11]. Artemisia Annua is one of the most important medicinal plant species with high content of essential oils and flavonoids [12]. The plant has the Arabic name Qaysom and which grows in the limestone wadis of the north eastern

desert and Red Sea regions [13]. Moreover, many effects such as anti-inflammatory, anti-oxidative effects, antihyperlipidemia and antihypertensive effects of Kaysom treatment have been reported [14-16]. The present study, was aimed to study the antidiabetic effects of the aqueous extract of Artemisia annua (Kaysom) on the testis histology in the alloxan-induced diabetic male albino rats.

Material and Methods

Plant Material

Preparation of Aqueous Extract of Artemisia Annua

Plants were collected from El-Arbacen valley, Saint Catherine, Wadi Gebal, South Sinai, Egypt. The leaves and stems were dried and separately ground into coarse powder. The aqueous extract of Artemisia annua has been prepared by boiling 2g of Artemisia annua with 200ml water for 5 min, kept cool to room temperature then filtered. The extract was daily prepared and stored in glass containers refrigerator. The Diabetic rats were treated orally with Artemisia annua twice daily at 8 am and 8 pm for 30 days (28.5mg/kg twice /day).

Animals

In this study, 30 healthy, adult male Wistar albino rats (150–200g, 3 months old) were used. They obtained from Animal house, Collage of pharmacy, Prince Sattam bin Abdulaziz University, KSA. They were preserved under controlled standard animal house conditions (temperature: 26–28°C; photoperiod: 12 h natural light and 12 h darkness; humidity: 80–90%) with easy access to food and water ad libitum at Animal Care Facility at, Prince Sattam bin Abdulaziz University. The pellet diet consisted of protein, lipids, crude fiber, ash, calcium and phosphorus. It also contain glucose. The rats remained under observation for about 2 weeks before the start of the experiment for adaptation. Diabetes was induced in animals by one dose of alloxan (120 mg/kg B. W. dissolved in saline). this dose was injected intraperitoneally to induce diabetes mellitus [17].

Ethical Considerations

All procedures conducted in studies involving animal models were according to the ethical standards of the institutional ethics committee of Prince Sattam bin Abdulaziz Univesity and animal house committee (IRB, PSAU-2017 ANT 1/34PI).

Experimental Design

Three group of animals, ten rats for each, used as follows:

Group I (Control group): Control non-diabetic rats.

Group II: The ats were injected in the peritoneum with a single dose of alloxan (120 mg/kg dissolved in saline solution).

Group III (Diabetic group + Kaysom): Diabetic rats treated by mouth Artemisia annua extract (28.5 mg/kg twice /day) for 30 days.

Histological Studies

The rats from the control, diabetic and treated groups were anesthetized by intraperitoneally administration of ketamine (90 mg/kg) and were sacrificed after one month by cervical dislocation. Small pieces of the testis were taken for the histological studies. The samples were prepared by installing in 10% neutral buffered formalin solution and Carnoy's fluid. For histological examination, paraffin sections were stained with Harris's Haematoxylin And Eosin (H&E) [18]. Paraffin sections were stained by using Mallory's trichrome stain for detection of collagen fibers, [18]. All previously stained sections were studied by using light microscope, photographed and all the detected variations between the three groups on the level of the microscopic findings had been scientifically discussed.

Immunohistochemical Study

The paraffin was removed from sections with xylene, followed by antigen restored by heating in citrate buffer (10 mM, 20 min). After that blocking of endogenous peroxidase in 3% H₂O₂ for 10 min and incubation with anti-caspase-3 (1:100; Abcam, Ab4051). After washing the slides with phosphate buffered saline, the sections were incubated with the related secondary antibodies at room temperature for 1 h, followed by exposure with 3- amino-9-ethylcarbazole, a chromogen. The morphometric data was obtained by image analyzer. The diameter of the seminiferous tubules for the different groups using H&E - stained sections at 400x magnification. In addition, the mean thickness of the seminiferous tubular diameters for the different groups using Mallory's trichrome-stained sections at 400x magnification. on the other hand, the collagen fibers in the seminiferous tubules for the different groups using Mallory's trichrome-stained sections at 400x magnification. Feulgen-stained sections at 400x magnification has been used to study the mean apoptotic changes of the seminiferous tubular germinal cells nuclei. The mean number of the caspase-3+ve expressed cells of the seminiferous tubular germinal cells using caspase-3 immnuostained sections at 400x magnification.

Statistical Analysis

All statistical analyses were carried out *via* Paleontological Statistics Version 3.0 (PAST 3.0) statistical software [19]. The data were expressed as mean \pm Standard Deviation (SD). It were also Analyzed Using Analysis of Variance (ANOVA)-Bonferroni with $p < 0.05$ considered statistically significant.

Results

Histological Results

Sections of the control adult albino rat testis showed many seminiferous tubules with interstitial tissue in between (Figure 1). The seminiferous tubules were lined with different spermatogenic

stages of spermatogenic cells in and mature sperms in the lumen. Seminiferous tubules (S.Ts) had two cell types: Sertoli and Spermatogenic cells (Figure 1). Spermatogenic cells were organized from the basal to the adluminal compartments in the following order; spermatogonia, spermatocytes (primary and secondary), spermatids and spermatozoa. While spermatogonia were basal in position and were small had small rounded nuclei, primary spermatocytes were next to it and were large and had large rounded central nuclei. Next to it, secondary spermatocytes and spermatids were also detected (Figure 1). Spermatids have smaller nuclei with pale chromatin. The late elongated spermatids were identified via their elongated deeply stained nuclei. Sertoli cells with ovoid nuclei were detected in between spermatogenic cells resting on the basement membrane of S.Ts (Figure 1).

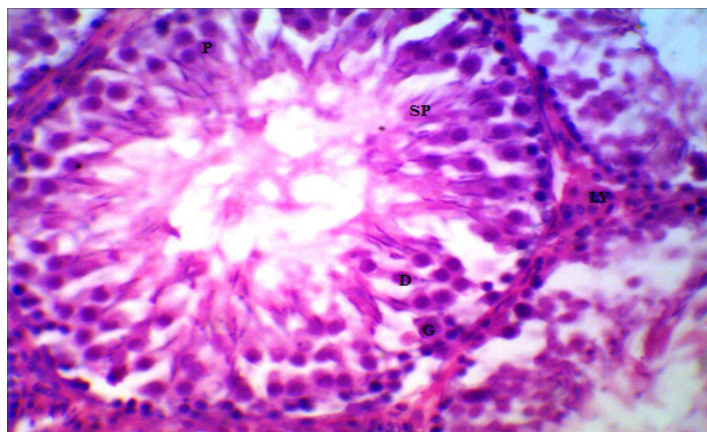


Figure 1: Light photomicrograph of a section from the control group shows the normal association of the germ cells and normal architecture of the interstitial tissue. G= Spermatogonium, P=Primary spermatocytes, D=Spermatid, SP=Sperm, Ly=Lydig cell, H&E (400×).

Within the interstitial connective tissue (I.T), polygonal or rounded Leydig cells were surrounding the blood vessels that had granular cytoplasm, single or doubled nuclei and appeared singly or in groups (Figure 1). The histological investigations of testicular tissue in the untreated diabetic rats observed irregularity of the S. Ts shapes with significant decrease their diameters in comparison to the control group. Also, the germinal epithelium showed obvious disarrangement of the germinal epithelium with abnormal cellular attachment. Moreover, the spermatogonia cells were the major cell type that was seen (Figure 2, Table 1). Also, multinucleated cells were detected in S. Ts (Figure 2). Moreover, the interstitial connective tissue had an amorphous material with marked destruction of the connective tissues and subsequent widening of the I.T spaces (Figure 3, Table 1). The treated group with Kaysom showed a considerable significant recovery of the S.Ts diameters in comparison to the diabetic group (Figure 2, Table 1). It showed also a considerable recovery of the I.T to normal levels with marked increase in the amount of the collagen fibers in

comparing to the diabetic group (Figure 3, Table 1).

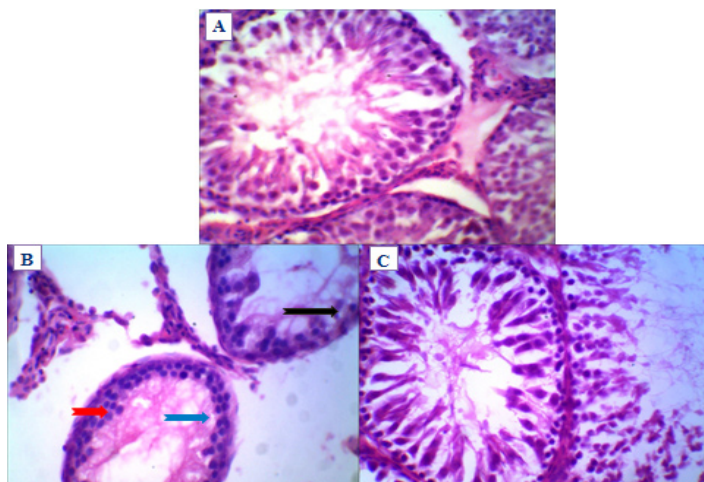


Figure 2: A) A section in a rat testicular tissue from the control group. The seminiferous tubules (S.Ts) have normal shape. S.Ts epithelium is structurally intact and shows normal association of germ cells. B) The S. Ts of untreated diabetic rat have irregular shape and the germinal epithelium is disorganized. Depletion of germ cells, pyknotic germ cells (black arrows) and karyolysis (green arrow) also seen. The giant cell formation with two or three nucleus (red arrow) is seen in the lumen of irregular shaped seminiferous tubule (ST). C) The S.Ts section in a rat testicular tissue treated with Kaysom extract have partial recovery to normal structure. H&E (400×).

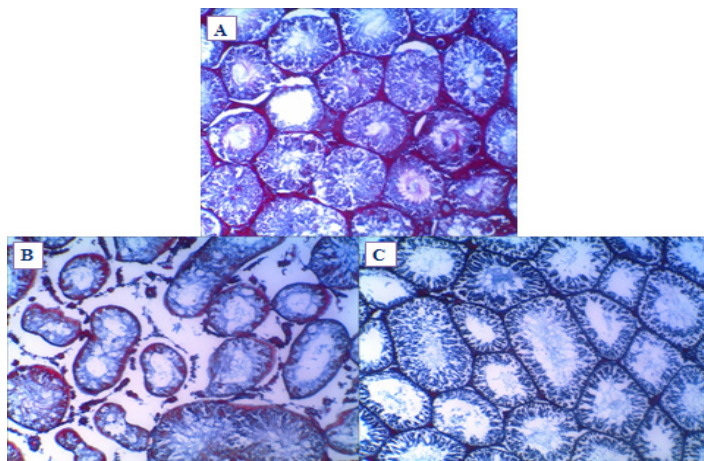


Figure 3: A) The control group shows normal distribution of collagen fibers in the interstitial tissue (I.T) around the seminiferous tubules. B) Testicular tissue from untreated diabetic rat shows marked reduction of collagen fibers in the I.T around the seminiferous tubules, and an increase diameter of the interstitial spaces. C) A section in a rat testicular tissue treated with Kaysom shows mild distribution of collagen fibers in the I.T around the seminiferous tubules in comparing to the control group. Mallory's trichrome (200×).

Paramaters	Mean diameters of the seminiferous tubules	Mean thickness of the seminiferous tubular interstitial diameters	Mean area percentage of the collagen fibres of the seminiferous tubular interstitial diameters	Mean apoptotic changes of the seminiferous tubular germinal cells nuclei	Mean number of the caspase-3+ve cells of the seminiferous tubular germinal cells
Study Groups					
Group I	187.11±	95.89±	142.03±	31.073±	13.00±
(Control)	13.92	7.57	23.25	1.48	1.94
Group II	125.61±	179.70±	63.97±	13.08±	35.81±
(Diabetic)	31.17 ^{**a}	22.50 ^{**b}	16.65 ^{**a}	4.03 ^{**a}	2.77 ^{**b}
GroupII	157.13±	68.64±	56.8911±	15.87±	32.92±
(Kaysom)	19.98 ^{**c}	11.05 ^{**d}	10.52 ^{**a}	3.49 ^{**a}	2.55 ^{**b}
<p>*Significantly different from the control group ($P < 0.05$).</p> <p>**Significantly different from the control group ($P < 0.001$).</p> <p>^aSignificant decrease in the parameters levels of the treated group in comparison to the control group.</p> <p>^bSignificant increase in the parameters levels in the treated group in comparison to the control group.</p> <p>^cSignificant increase in the parameters levels of the treated group in comparison to the diabetic group.</p> <p>^dSignificant decrease in the parameters levels in the treated group in comparison to the diabetic group.</p>					

Table 1: Diameters of the seminiferous tubules, thickness of the seminepherous tubular interstitial diameters, percentage of the collagen fibres of the seminiferous tubular interstitial diameters, apoptotic changes of the seminepherous tubular germinal cells nuclei and number of the caspase-3+ve cells of the seminiferous tubular germinal cells for the different groups of the study expressed as mean ± SD.

Immunohistochemical Results

The immunohistochemical investigations of the testicular tissue for the control group revealed mild expression of Caspase-3 immunostaining with few caspase-3 +ve cells in the S. Ts (Figure 4,& Table 1). In diabetic group, a marked increase in the number of caspase-3+ve cells was observed in the S. Ts in comparison to the control ones (Figure 4,& Table 1). The treated group with Kaysom showed a marked increase in the number of caspase-3+ve cells was observed in the S. Ts in comparing to the control ones (Figure 4,& Table 1).

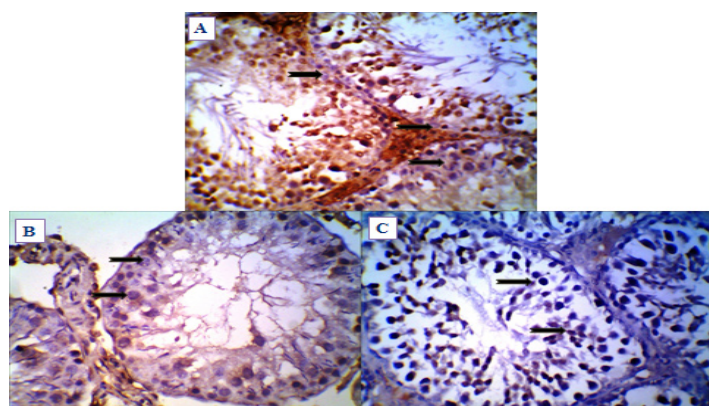


Figure 4: A) The testicular tissue of a rat from the control group. The seminiferous tubules (S.Ts) germinal cells show mild expression of Caspase-3 immunostaining (black arrows). B) The S.Ts of untreated diabetic rat show marked expression of Caspase-3 immunostaining (black arrows). C) A section treated with Kaysom shows marked expression of Caspase-3 immunostaining (black arrows) in the S.Ts germinal cells. Caspase-3 immunostaining (400×).

Discussion

Diabetes is a major health issue influencing major population worldwide. Several research findings in diabetic men and animal models proved that DM increases the oxidative stress in testis, alter the endocrine metabolism and spermatogenesis process, which in turn affect male reproductive functions causing male infertility [20,21]. The results of this study showed that the alloxan had a destructive effect on seminiferous tubule cells in the testis of rats. Moreover, in alloxan diabetic rats, these tubules were dilated and the spermatogenic cells irregularly arranged, spermatogenesis was arrested with highly reduction in the number of spermatids. Kaysom extract is abundant with many flavonoids such as afroside, cirsimartin, chrysopenol and cirsiol. Generation of reactive oxygen species resulted from hyperglycemia leads to oxidative stress in various tissues, including reproductive system. An important association between oxidative stress, inflammatory response and insulin activity is now well established. The ability of antioxidants to protect against the hazardous effects of hyperglycemia and also to improve glucose metabolism and intake must be considered as leads of choice in diabetes treatment. Diabetic associated-tissue injury and its subsequent complications are most probably caused by free radicals [22]. Previous studies on diabetic subjects showed decreased testosterone levels and vacuolization in the germinal epithelium (spermatogonia and spermatocytes) with subsequent decrease in the testicular weight, sperm number and motility [23,24]. Some studies referred to increasing S. Ts thickness and germ cell depletion in both the diabetic human and rats [25,26]. In addition, the present study revealed similar results as irregularity of the S.Ts shapes with significant decrease in S.Ts

diameters. Furthermore, similar to many previous studies results [27]. On the other hand the current study showed degeneration and necrosis of the S. Ts, giant cell formation and interstitial changes in the diabetic rats. Many herbal extracts or derivatives with high antioxidant activity are useful for diabetes treatment and other metabolic syndrome [28]. Thus, antioxidant therapy is one of the major strategies for diabetes treatment [28]. Our results showed that Kaysom has significant protective effects against the apoptotic changes. This protective effect may be due to their antioxidant properties that has been shown in previous studies [28]. Abnormal high levels of free radicals and the simultaneous decline of antioxidant defense mechanisms may damage the cellular organelles and enzymes, increases lipid peroxidation and leads to insulin resistance [29]. Antioxidant defense by antioxidant enzymes is a protective mechanism against oxidative stress that scavenge harmful ROS in male reproductive organs and playing an important role in maintaining spermatogenesis and reproductive functions [30].

Conclusion

In conclusion, considerable improvements in the testicular tissue morphological changes that were observed in diabetic groups had been detected after Kaysom treatment in comparison to the control group.

References

- Moore H, Summerbell C, Hooper L, Cruickshank K, Vyas A, et al. (2004) Dietary advice for treatment of type 2 diabetes mellitus in adults. The Cochrane database of systemic reviews 2004: CD004097.
- Kuhn-Velten N, Waldenburger D, Staib W (1982) Evaluation of Steroid Biosynthetic Lesions in Isolated Leydig Cells from the Testes of Streptozotocin-Diabetic Rats. *Diabetol* 23: 529-533.
- Morimoto S, Mendoza-Rodriguez A, Hiriart M, Larrieta ME, Vital P, et al. (2005) Protective effect of testosterone on early apoptotic damage induced by streptozotocin in rat pancreas. *J Endocrinol* 187: 217-224.
- Ballester J, Carmen M, Dominguez J, Rigau T, Guinovart JJ, et al. (2004) Insulin- Dependent Diabetes Affect Testicular Function by FSH- and LH-linked Mechanisms. *J Androl* 25: 706-719.
- Cai L, Chen S, Evans T, Deng DX, Mukherjee K, et al. (2000) Apoptotic germ-cell death and testicular damage in experimental diabetes: prevention by endothelin antagonism. *Urol Res* 28: 342-347.
- Sanguinetti E, Ogawa K, Kurohmaru M, Hayashi Y (1995) Ultrastructural changes in mouse Leydigcells after streptozotocin administration. *Exp Anim* 44: 71-73.
- Ozturk F, Gul M, Agkadir M (2002) Histological alterations of rat testes in experimental diabetes. *T Kin J Med Sci* 22: 173-178.
- Kesavulu MM, Gird R, KameswaraRao B, Apparao C (2000) Lipid peroxidation and antioxidant enzyme levels in type 2 diabetics with microvascular complications. *Diabetes and Metabolism* 26: 387-392.
- Evans JL, Goldfine ID, Maddux BA, Grodsky GM (2003) Are oxidative stress—activated signaling pathways mediators of insulin resistance and β -cell dysfunction?" *Diabetes* 52: 1-8.
- Ugochukwu NH, Babady NE, Cobourne E, Gasset SR (2003) The effect of Gongronema latifolium extracts on serum lipid profile and oxidative stress in hepatocytes of diabetic rats. *Journal of Biosciences* 28: 1-5.
- Wazaify M, Afifi FU, El-Khateeb M, Ajlouni K (2011) Complementary and alternative medicine use among Jordanian diabetes patients. *Complement TherClinPract* 17: 71-75.
- Woerdenbag HJ, Bos R, Salomons MC, Hendriks H, Pras N, et al. (1993) Volatile constituents of *Artemisia annua* L. (Asteraceae). *Flav. and Frag J* 8: 131-137.
- Bhakuni RS, Jain DC, Sharma RP, Kumar S (2001) Secondary metabolites of *Artemisia annua* and their biological activity. *Current Science* 80: 35-48.
- Bora KS, Sharma A (2011) The genus *Artemisia*: A comprehensive review. *Pharm. Biol* 49: 101-109.
- Al-Mustafa H, Al-Thunibat OY (2008) Antioxidant capacity of some Jordanian medicinal plants used traditionally for the treatment of diabetes. *Pak J Biol Sci* 1: 351-358.
- Bhakuni S, Jain C, Sharma P, Kumar S (2001) Secondary metabolites of *Artemisia annua* and their biological activity. *Current Science* 80: 35-48.
- Malaisse J (1982) Alloxan toxicity to the pancreatic B-cell. A new hypothesis. *Biochem. Pharmacol* 31: 3527-3537.
- Bancroft D, Gamble M (2008) Bancroft's Theory and Practice of Histological Techniques. 6th Ed. Elsevier Churchill Livingstone, Edinburgh, Scotland 178-186.
- Hammer Ø, Harper D, Ryan D (2001) PAST: Paleontological Statistics Software Package for Education and Data Analysis. *Palaeontologia Electronica* 4: 9-15.
- Agarwal A, Gupta S, Sikka S (2006) The role of free radicals and antioxidants in reproduction. *Curr.Opin.Obstet.Gynecol* 18: 325-332.
- La Vignera S, Condorelli R, Vicari E, D'Agata R, Calogero AE (2012) Diabetes mellitus and sperm parameters. *J.Androl* 33: 145-153.
- Annunziata L, Domenico F, Pietro T (2005) Glycooxidation in diabetes and related diseases. *Clin Chim Acta* 357: 236-250.
- Bhasin S, Enzlin P, Coviello A, Basson R (2007) Sexual dysfunction in men and women with endocrine disorders. *The Lancet* 369: 597-611.
- Seethalakshmi L, Menon M, Diamond D (1987) The effect of streptozotocin-induced diabetes on the neuroendocrine-male reproductive tract axis of the adult rat. *J Urol* 138: 190-194.
- Cameron F, Murray T, Drylie D (1985) Interstitial compartment pathology and spermatogenic disruption in testes from impotent diabetic men. *Anat Rec* 213: 53-62.
- Sadik H, El-Seweidy M, Shaker G (2011) The antiapoptotic effects of sulphurous mineral water and sodium hydrosulphide on diabetic rat testes. *Cell PhysiolBiochem* 28: 887-898.
- Anderson E, Thliveris A (1986) Testicular histology in streptozotocin-induced diabetes. *Anat Rec* 214: 378-382.

28. Samad A, Shams S, Ullah Z, Wais M, Nazish I, et al. (2009) Status of herbal medicines in the treatment of diabetes. *Curr. Diabetes Rev* 5: 102-111.
29. Yang H, Jin X, Kei Lam W, Yan K (2011) Oxidative stress and diabetes mellitus. *Clinical Chemistry & Laboratory Medicine* 49: 1773-1782.
30. Fujii J, Iuchi Y, Matsuki S, Ishii T (2003) Cooperative function of anti-oxidant and redox systems against oxidative stress in male reproductive tissues. *Asian J. Androl* 5: 231-242.