

## Case Report

# Post Infarct Cardiac Free Wall Rupture Detected by Multidetector Computed Tomography

**Johann Christopher\***

Consultant Cardiologist and Director of Cardiac Imaging, Care Hospitals, Hyderabad, India

**\*Corresponding author:** Dr. Johann Christopher, Consultant Cardiologist and Director of Cardiac Imaging, Care Hospitals, Hyderabad, India. Tel: + 919701445011; Email: johann1403@gmail.com

**Citation:** Christopher J (2017) Post Infarct Cardiac Free Wall Rupture Detected by Multidetector Computed Tomography. Cardiol Res Cardiovasc Med 2: 122. DOI: 10.29011/2575-7083.000022

**Received Date:** 29 August, 2017; **Accepted Date:** 26 September, 2017; **Published Date:** 05 October, 2017

## Abstract

48-year-old lady with chest pain is diagnosed to have an infer posterior MI. 2decho reveals a moderate pericardial effusion post thrombolysis with persistent chest pain. In view of a possibility of a sealed myocardial rupture she undergoes a coronary CTA to assess the coronary anatomy and to delineate the rupture. The CTA confirms the rupture and delineates the coronary anatomy. Patient undergoes pericardial patch repair with a good result.

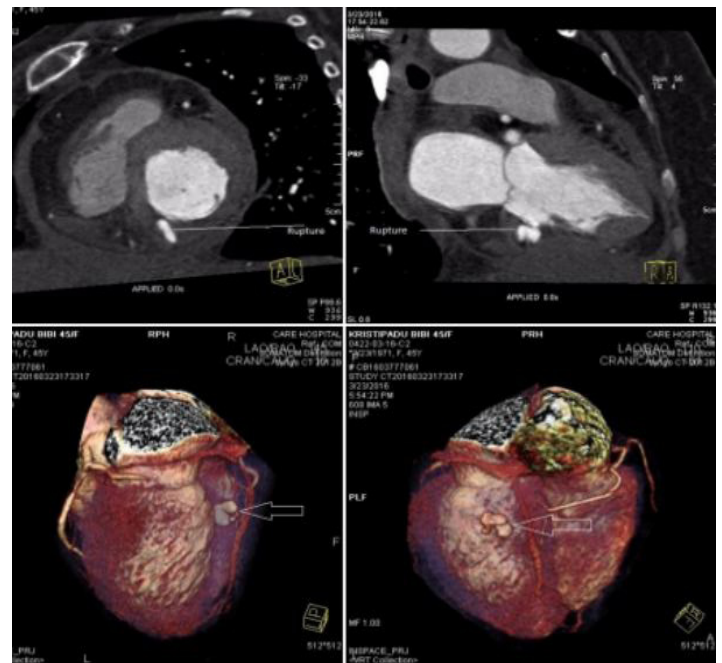
**Keywords:** Multidetector Computed Tomography; Myocardial Rupture

## Introduction

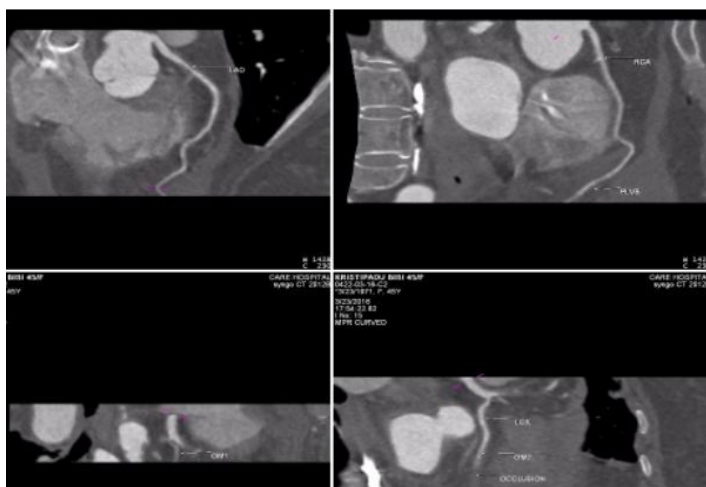
48-years old lady with history of chest pain of 4 days duration went to nearby hospital, where she was diagnosed as Infer-Posterior Wall ST elevation Myocardial Infarction and thrombolysed with streptokinase. Patient was referred to our hospital in view of moderate pericardial effusion for further evaluation. Examination revealed a pulse rate was 126 beats/min, blood pressure of 100/60 mmHg, her JVP was elevated. Cardiovascular examination revealed normal heart sounds with no murmur or rub. Respiratory examination revealed few basal crepitations. ECG showed sinus tachycardia, qS in II, III and aVF with concomitant ST elevation. There were T inversions and ST depression from V1 to V3.

2D Transthoracic Echo showed regional wall motion abnormality in basal and mid inferior wall and inferior septum and basal posterolateral wall, moderate LV dysfunction, preserved RV function, moderate MR, moderate circumcardiac pericardial effusion. Her blood analysis was unremarkable. She was suspected to have a cardiac rupture and was subjected to a cardiac CT Scan as is the protocol in our institute where we have diagnosed rupture in ten previous cases which was proven on surgery. CT scan with contrast revealed a sealed myocardial rupture in the basal posterolateral wall of left ventricle with a neck of 2mm and an area of 0.8 cm<sup>2</sup> (Figure 1). CT coronary angiogram showed total occlusion of

a large OM2 branch with grade V thrombus (Figure 2). Coronary anatomy was clearly depicted despite her heart rate being above 100 beats per minute which was corroborated by the coronary angiogram which was done just prior to subjecting her for surgery.



**Figure 1:** MIP and VRT Images Depicting the Myocardial Rupture.



**Figure 2:** MIP Images Depicting the Coronary Anatomy and the Occluded OM Vessel.

She was taken up for emergent surgical repair of cardiac rupture. The pericardial cavity was filled with 500ml of altered colored blood. There was infarcted and friable myocardium in posterobasal wall with a rent of 0.5cm near the AV groove. The tear was compatible with the contrast pooling in the MDCT. The repair was done with a bovine pericardial patch.

Surgery was successful with no periprocedural or post-operative complications. She was subsequently weaned off from ventilator support, inotropes and IABP. She made an uneventful recovery and was discharged in satisfactory condition.

## Discussion

Cardiac free wall rupture after myocardial infarction is one of the life-threatening complications, which often results in sudden onset of cardiogenic shock caused by cardiac tamponade. According to the SHOCK Trial Registry, in-hospital mortality rate was 60% [1]. Although the incidence of free wall rupture after myocardial infarction was 2.7%, the true rate is difficult to assess due to unconfirmed causes of death, especially pre-hospital death, and diminished autopsy rates [1]. This complication occurs more frequently in patients with female gender, advanced age, first-time myocardial infarction, elevated blood pressure, and transmural infarction [1,2,3]. Ischemic myocardial rupture after AMI may involve Left Ventricular (LV) and Right Ventricular (RV) free walls, ventricular septum, and LV papillary muscle, in decreasing order of frequency. It rarely involves the left or right atrial walls. LAD is the most common site of the culprit artery to this fatal event, whereas RCA as in the present case is relatively uncommon, with a reported incidence of 0-23% [1,4].

In some patients who survive LV free-wall rupture following AMI, the rupture can be sealed by the epicardium (visceral pericardium) or by a hematoma on the epicardial surface of the heart.

This entity has been referred to as LV diverticulum (or contained myocardial rupture [5]) and represents a subacute pathologic condition between free rupture into the pericardial cavity and formation of a pseudoaneurysm.

A pseudoaneurysm is formed if the area of rupture is contained locally by the adjacent parietal pericardium and represents the chronic stage of LV free-wall rupture. The most common etiology of LV pseudoaneurysm was myocardial infarction; inferior infarcts were approximately twice as common as anterior infarcts [6]. Myocardial free wall rupture is associated more frequently with thrombolysis especially done after 6 hours [7]. In the above-mentioned case, delayed thrombolysis was given which could be a causative factor in Myocardial Free Wall Rupture. As the rupture was contained by the epicardium, patient did not present with a cardiac tamponade.

In the diagnosis of cardiac rupture, it is generally difficult to show the defect of the ventricular wall. Pericardial effusion by CT or echocardiography is only an indirect indicator of an underlying rupture. In most cases of postinfarct cardiac free wall rupture, the hemodynamic status is unstable, therefore echocardiography is utilized for detecting pericardial effusion because of its rapidity and ease. Hence there is reluctance on the part of the clinician to utilize cardiac CT for the diagnosis.

MDCT provides valuable information in a patient suspected of postinfarct cardiac rupture. According to literature research, there have been few case reports on coincidentally detecting cardiac rupture after myocardial infarction by means of CT when the scan was undertaken to detect other pathology like aortic dissection. Redfern and Smart reported a case of postinfarct cardiac rupture with a tear at the LV apex detected by CT. They found contrast medium in the pericardial cavity, indicating the spilling of blood into the pericardial cavity [8]. Naoki Onoda et al. reported a case of cardiac rupture diagnosed on MDCT with small contrast pooling in the posterolateral LV wall within a hypo perfused area [9]. This finding is equivalent to free wall rupture within the infarcted LV wall.

## Conclusion

Cardiac CT is a noninvasive, accurate and cost-effective tool for the early diagnosis of cardiac rupture with subsequent appropriate surgical treatment which in turn will improve prognosis in this high-risk subset.

## References

- Slater J, Brown RJ, Antonelli TA, Menon V, Boland J, et al. (2000) Cardiogenic shock due to cardiac free-wall rupture or tamponade after acute myocardial infarction: a report from the SHOCK Trial Registry. *J Am Coll Cardiol* 36: 1117-1122.
- Reardon MJ, Carr CL, Diamond A, Letsou GV, Safi HJ, et al. (1997) Ischemic left ventricular free wall rupture: prediction, diagnosis, and treatment. *Ann Thorac Surg* 64: 1509-1513.

3. Batts KP, Ackermann DM, Edwards WD (1990). Post infarction rupture of the left ventricular free wall: clinicopathologic correlates in 100 consecutive autopsy cases. *Hum Pathol* 21: 530-535.
4. Ishikawa N, Kobayashi A, Ogihara A, Kotaka H, Shimosato K, et al. (1990) Cardiac free wall rupture after acute myocardial infarction. *ICU CCU* 14: 231-237.
5. Helmy TA, Nicholson WJ, Lick S, Uretsky BF (2005) Contained myocardial rupture: a variant linking complete and incomplete rupture. *Heart* 91: e13.
6. Frances C, Romero A, Grady D (1998) Left ventricular pseudoaneurysm. *J Am Coll Cardiol* 32: 557-561.
7. Becker RC, Charlesworth A, Wilcox RG, Hampton J, Skene A, et al. (1995) Cardiac Rupture Associated with Thrombolytic Therapy: Impact of Time to Treatment in the Late Assessment of Thrombolytic Efficacy (LATE) Study. *JACC* 25: 1063-1068.
8. Redfern A, Smart J (2003) Cardiac rupture. *N Engl J Med* 348: 609.
9. Naoki Onoda, Asa Nonami, Toshikazu Yabe, Yoshinori L Doi, Yasufumi Fujita, et al. (2012) Postinfarct cardiac free wall rupture detected by multidetector computed tomography. *Journal of Cardiology Cases* 5: e147-e149.