

Case Report

Modified Carnoy's Solution Use in Keratocystic Odontogenic Tumour - A Case Report

Anirudh Bhattacharya^{1*}, Vijay Sharma², Amar Thakare³

¹Department of Cranio Maxillofacial Surgery and Traumatology, Jaipur, India

²Department of Cranio Maxillofacial Surgery and Traumatology, Akola, India

³Department of Maxillo Facial Prosthodontics, Ahmednagar, India

***Corresponding author:** Anirudh Bhattacharya, Department of Cranio Maxillofacial Surgery and Traumatology, Ashirwad Hospital, Jaipur, India. Tel: +919610899902; E-Mail: dranirudhb@gmail.com

Citation: Bhattacharya A, Sharma V, Thakare A (2017) Modified Carnoy's Solution Use in Keratocystic Odontogenic Tumour - A Case Report. J Surg 2017; JSUR-142. DOI: 10.29011/JSUR-142.000042

Received Date: 24 May 2017; **Accepted Date:** 08 June, 2017; **Published Date:** 15 June, 2017

Introduction

Keratocystic Odontogenic Tumor (KCOT) is keratinized epithelium lined cyst of the jaws with well-defined histologic criteria. KCOT usually occurs as a multilocular or unilocular radiolucency often in dentigerous relationship [1]. While the most common site is the posterior portion of the mandible or the mandibular ramus, other locations have been reported such as anterior portion of maxilla and maxillary third molar area [2]. One clinical feature warranting their recognition and separation as a distinctive entity is their exceedingly high recurrence rate. These lesions may occur anywhere in the jaws but are most commonly seen in mandible rarely in maxilla with males affected more than females. The KCOT grow primarily in the marrow spaces and in an antero posterior direction. Only when they reach a considerable size do they expand bucco lingually and become evident clinically. When seen by the clinician most of them are large and may have perforated the bone especially lingually where the capsule is in close contact with the periosteum [3]. Malignant transformation of KCOT has been reported [4].

Recurrence rate reviewed are ranging from 6%- 62%. It has been proposed that reasons for recurrence include technical and/or surgical difficulties resulting in incomplete cyst removal, the thin and friable nature of capsule, bony perforation, and adherence to adjacent soft tissue structures [5]. Patients with multiple KCOTs exhibit higher rate of recurrence than patients with single KCOT. It has been recommended that annual radiographic follow up should be employed indefinitely in the management of these patients [6]. The use of carnoy's solution is well document for control of recur-

rence. But recently the use of chloroform was debated and found to be hazardous due to its carcinogenic potential. The modified carnoy's solution without chloroform has shown bit higher rates of recurrence in few studies although long term prospective studies are sparse.

Case Report

A female patient, aged 37 years presented to the Department of Oral and Maxillofacial surgery with chief complaint of intra oral painless swelling for past 6 months which was constant size and shape on clinical inspection, it extended into and obliterated the left posterior mandibular muco buccal fold starting from distal of lower left first molar till the ipsilateral anterior faucial pillar covering the whole left retromolar trigone. (Figure-1).

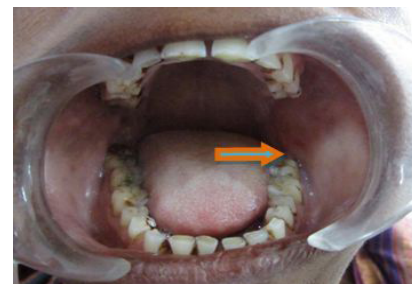

Figure 1: Pre-Op Intra oral view.

On palpation it was soft, smooth and non- tender. Intra oral wide bore needle aspiration was performed which showed milky white, odorless fluid with numerous white structures most probably representing the keratin flex (Figure-2).

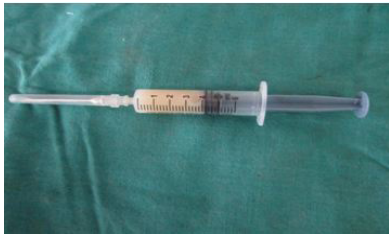

Figure 2: Aspiration fluid.

It was sent for Histopathological examination. A panoramic radiograph revealed a well-circumscribed unilocular radiolucent area extending from distal of mandibular left 2nd molar till the ipsilateral sigmoid notch. No evidence of destruction of posterior border of ramus was evident (Figure-3).

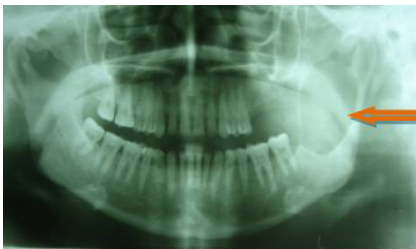

Figure 3: Panoramic radiograph showing the cystic lesion.

Head of the condyle was normal and unaffected. Computed Tomographic (CT) scans were not advised due to poor socio-economic condition of the patient. The remainder of physical examination was non-contributory. A provisional diagnosis of residual cyst, traumatic bone cyst, primordial cyst, kcot, and ameloblastoma was made on the basis of clinical and radiographic appearance. Under all aseptic conditions and precautions, under general anesthesia, intra oral extended ward incision was placed from left mandibular 2nd premolar region till coronoid process running over lateral part of mandible. Full thickness mucoperiosteal flap was raised, cyst exposed and careful enucleation was done (Figure-4).

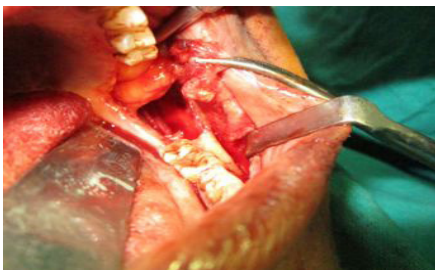

Figure 4: Enucleation followed by application of Carnoy's MC.

Chemical cauterization was done with Carnoy's MC solution. Lateral and medial cortical plates were intact but thin. Peripheral osteotomy was carefully carried out followed by removal of overlying soft tissue. A 2×3 cm encapsulated cystic lesion was delivered. During enucleation, white cheesy material from the cyst was collected. The wound was closed with resorbable sutures. The surgical site healed uneventfully with minimal neural deficits and

the patient was having an appreciable mouth opening with normal functions. The follow up of this particular patient was done for 2 continuous years, every alternate month and no signs of recurrence were seen (Figure-5).

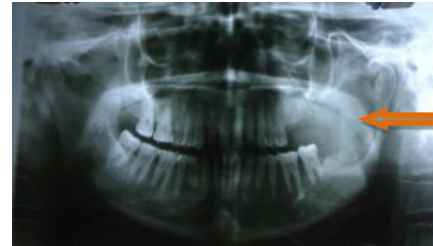

Figure 5: Post op OPG after 24 months.

The specimen was sent for histological examination and the report returned with following findings. Basal cell layer is well defined and is composed of palisaded cuboidal or columnar cells, hyperkeratotic nuclei with a reverse polarity and tomb stoning appearance. 'Microscopically the sections show cystic epithelium which is stratified squamous keratotic with corrugated appearance. The cystic lumen is filled with keratin. There is separation of the epithelium from the connective tissue. The connective tissue capsule is composed of parallel arranged collagen bundles. Mostly suggestive of KCOT. (Figure-6).

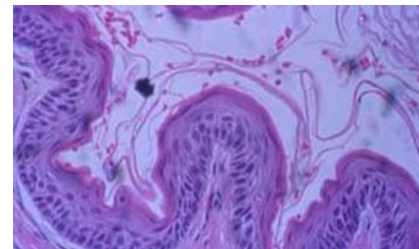


Figure 6: Histological section.

Carnoy's original solution consists of 3 ml of chloroform, 6 ml of absolute ethanol, 1 ml of glacial acetic acid and 1 g of ferric chloride but the modified was without chloroform to eliminate the risk of carcinogenicity.

Discussion

The KCOT is a unique clinical and histologic entity with aggressive behaviour. Its frequent recurrence and association with basal cell nevus syndrome the cyst originates in the dental lamina but some support a possible basal cell component origin [7]. The most common location for keratocyst is mandibular 3rd molar and ramus region. The maxillary 3rd molar is the next most common site followed by mandibular premolar region and maxillary canine region [1]. Differential diagnosis could be dentigerous cyst, residual cyst, primordial cyst, lateral periodontal cyst etc. It also presents itself as periapical disease. Wright [8] emphasizes the importance of including KCOT in differential diagnosis of radiolucencies occurring at apices of non-vital teeth. KCOTs can also

present as eruption cyst and the involved tooth is usually found to erupt through the cyst.

KCOT is often associated with an un-erupted tooth. Browne [9] has classified the KCOT into follicular and extra follicular types according to its relationship with associated tooth. Numerous surgical modalities have been suggested for treatment of keratocystic odontogenic tumor. These include curettage, enucleation alone, enucleation with cornoy's solution placed in the cyst cavity before enucleation+arsupialization, and resection with reconstruction. The type of treatment rendered is controversial, but depends on several factors such as patient's age, location and size of the lesion, and whether the KCOT is primary or recurrent. The role of modified carnoy's solution is still debatable as conflicted in few studies [10-12]. KCOT appears to be a benign disease with a 17-56% recurrence rate if simple enucleation is done in isolation. If any adjunctive treatment is added such as application of cornoy's solution, or decompression before enucleation, the recurrence rate is reported to be from 1% to 8.7%.

Conclusion

The necessity for microscopic examination of all material surgically removed from the jaws has been stressed. We have discussed the clinical implications of a diagnosis of KCOT, high recurrence rate-necessitating close clinical follow up and use of Modified carnoy's solution effectively controlling the recurrence for at least 24 months. A long term close follow up is required in order to monitor the possibility of recurrence of cyst and for the occurrence of basal cell nevus syndrome.

References

1. Woo SB, Eisenbud L, Kleiman M, Assael N (1987) Odontogenic keratocysts in the anterior maxilla: report of two cases one simulating nasopalatine cyst. *Oral Surg Oral Med Oral Pathol* 64: 463-465.
2. Brannon RB (1976) The odontogenic keratocyst a clinico pathologic study of 312 cases. *Oral Surg Oral Med Oral Pathol* 42: 54-72.
3. Nayak UA, Rajeshkumar BP (2002) A review of KCOT with a report of unusual occurrence in the maxilla. *Indian J dent res* 13: 183-186.
4. Makowski GJ, McGuff S, van Sickels JE (2001) Squamous cell carcinoma in a maxillary odontogenic keratocyst. *J Oral Maxillofac Surg* 59: 76-80.
5. Stoelinger PJ, Bronkhorst FB (1988) The incidence multiple presentation and recurrence of aggressive cysts of the jaws. *J Craniomaxillary Surg* 16: 184-195.
6. Clinical images in oral and maxillofacial radiology (2002) *Quintessence international* 5: 400-401.
7. Brannon RB (1977) The odontogenic keratocyst a clinico pathologic study of 312 cases part II *Oral Surg Oral Med Oral Pathol* 43: 233-255.
8. Wright BA, Wysocki GP (1983) Odontogenic presenting as peri apical disease. *Oral Surg Oral Med Oral Pathol* 56: 425-429.
9. Browne RM (1971) The odontogenic keratocyst Histologic features and their correlation with clinical behaviour. *British Dental journal* 131: 248-259.
10. Zhao YF, Wei JX, Wang SP (2002) Treatment of odontogenic keratocysts a follow-up of 255 Chinese patients. *Oral Surg Oral Med Oral Pathol Oral Radiol Endod* 94: 151-156.
11. Hellstein J, Hopkins T, Morgan T (2007) The history and mystery of Carnoy solution an assessment of the need for chloroform. *Oral Surg Oral Med Oral Pathol Oral Radiol Endod* 103: 524.
12. Dashow JE, McHugh JB, Braun TM, Edwards SP, Helman JI, et al. (2015) Significantly Decreased Recurrence Rates in Keratocystic Odontogenic Tumor with Simple Enucleation and Curettage Using Carnoy's Versus Modified Carnoy's Solution. *J Oral Maxillofac Surg* 73: 2132-2135.