

Case Report

Minimally Invasive Mitral Valve Replacement in a Case of Marfan's Syndrome-Post Bentall's Procedure and Pectus Excavatum Reconstruction

Anuj Sangal*, Ratnamalika Kumar, Rajneesh Malhotra

Department of CTVS, Max Superspecialty Hospital, India

*Corresponding author: Anuj Sangal, Department of CTVS, Max Superspecialty Hospital, 2,3, Press Enclave Road, Saket, New Delhi-110017, India. Email: dranujsangal23@gmail.com

Citation: Sangal A, Kumar R, Malhotra R (2019) Minimally Invasive Mitral Valve Replacement in a Case of Marfan's Syndrome-Post Bentall's Procedure and Pectus Excavatum Reconstruction. *Cardiol Res Cardiovasc Med* 4: 151. DOI: 10.29011/2575-7083.000051

Received Date: 20 October, 2019; **Accepted Date:** 01 November, 2019; **Published Date:** 06 November, 2019

Abstract

Marfan's syndrome is caused by mutation in fibrillar-1 gene which results in connective tissue disorder and multi-organ systems are involved. We describe a rare interventional procedure in which a 30-year-old gentleman, a diagnosed case of Marfan's syndrome-post Bentall's procedure for dilated aortic root and surgically corrected Pectus excavatum 15 years back; presented with severe mitral regurgitation; underwent a successful Minimally Invasive Mitral Valve Replacement.

Keywords: Marfan's Syndrome; Minimally Invasive Cardiac Surgery; Mitral Valve Prolapse

Background

The incidence of MFS is among the highest of any heritable disorder: about 1 in 3000/5000 births in most racial and ethnic groups. Mutations are generally inherited as autosomal dominant traits, but about one-fourth of patients have sporadic new mutations. More than 90% of patients clinically classified as having MFS by the "Ghent criteria" have a mutation in the gene for fibrillin-1 (*FBNI*). Mutations in the same gene are found in a few patients who do not meet the Ghent criteria. Also, a few MFS patients without mutations in the *FBNI* gene have mutations in the gene for TGF- β receptor 2 (*TGFBR2*) [1].

The diagnosis of Marfan syndrome relies on a set of defined clinical criteria (the Ghent nosology) developed to facilitate accurate recognition of the syndrome and improve patient management and counselling. Based on modified Ghent's criteria; If family/genetic history is not contributory, major criteria in at least two different organ systems and involvement of a third organ system. If a mutation known to cause Marfan syndrome is detected, one major criterion in an organ system and involvement of a second organ system [2].

Case Presentation

30 years, male, presented with complaints of exertional dyspnea, easy fatigability and palpitations since three months. On evaluation he was diagnosed to have Mitral valve prolapse with severe Mitral regurgitation. Patient was a known case of Marfan's syndrome, post Bentall's procedure for ascending aorta aneurysm with 23mm SJM metallic valve conduit and Pectus Excavatum which required surgical correction 15 years back (Figure 1). Patient also elicited other features of modified Ghent's criteria like Dural ectasia, positive wrist sign, Pes planus, retinal degeneration, recurrent pneumothorax, unexplained stria & history of inguinal hernia repair.

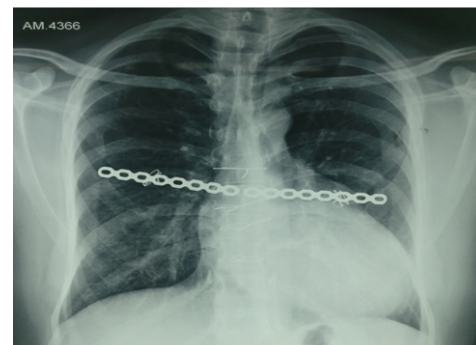

Figure 1: Pre-operative radiograph showing sternal wires and chest reconstruction plate from previous Bentall's procedure and chest wall reconstruction surgery.

2D Echo revealed normally functioning Aortic valve prosthesis, severe mitral valve regurgitation caused by prolapse of both the leaflets into LA. Dilated LA (5.7cms), LV (LVEDD=62mm), normal LVEF=55% and trace TR. CT thorax was suggestive of densely adhered pericardium with the sternum.

Minimally Invasive technique was opted in view of Redo procedure and Right anterior thoracotomy incision was done in fourth intercostal space to avoid previous plate of pectus excavatum repair in third intercostal space. Peripheral cannulation was done using right femoral vessels and right internal jugular vein. St. Thomas blood cardioplegia was administered through aortic root and patient was cooled to 28 degrees centigrade. Mitral valve was replaced trans-LA and a 31/33 On-X metallic mitral valve prosthesis was implanted using Cor-knot technique (Figure 2). Total CPB time was 205 minutes and ACT was 112 minutes. Patient was weaned off bypass and was shifted to ICU on moderate inotropic support and ventilatory support.

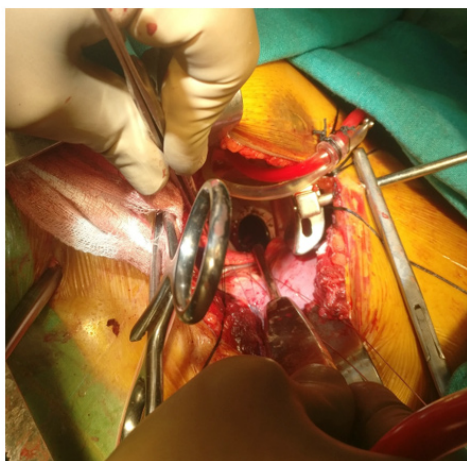


Figure 2: Metallic mitral valve prosthesis implanted using Cor-knot technique.

Discussion

Marfan syndrome is the most common heritable connective tissue disorder with multisystem manifestations [3]. Cardiovascular manifestations include aneurysmal dilatation of the ascending aorta, aortic valvar regurgitation, aortic dissection, floppy mitral valve with mitral valve prolapse, mitral valvar regurgitation, and mitral annular dilatation [3]. If untreated, cardiovascular manifestations account for as high as 50% mortality during the first 4 decades of life [4]. Aortic root dilatation and aortic complications account for most of these deaths [4].

Mitral valve abnormalities have received little attention

in the past, despite 80% of patients with Marfan syndrome having mitral valve dysfunction [3,5]. In the pediatric Marfan population, mitral valve dysfunction is the most common cause of mortality and morbidity [4]. On clinical examination and echocardiographic investigation, 60% to 80% of pediatric Marfan patients have mitral prolapse [3,5]. This is progressive: by the age of 30 years, 1 in 8 patients has moderate to severe mitral regurgitation [2]. Once the mitral valve is regurgitant, pathologic findings include fibromyxomatous changes of the leaflets and chordae, annular dilatation, calcium deposits, and elongation and rupture of the chordae [3].

Structural alterations of the mitral valve in patients with the Marfan syndrome include annular dilation, annular calcification, fibromyxomatous changes of leaflets and chordae, chordal rupture and elongation, and leaflet fenestration [6]. The latter finding may represent residua of endocarditis [6]. It has also been recently demonstrated that 15% of patients with the Marfan syndrome have abnormal chordal attachments whereby posterior leaflet chordae arise atypically from the posterior ventricular wall [7].

Patients with Marfan syndrome and mitral regurgitation have better survival with repair than with replacement. Survival and risk of reoperation for patients with Marfan syndrome were similar to those for patients with myxomatous mitral disease. These results support the use of mitral valve repair in patients with Marfan syndrome and moderate or more mitral regurgitation, including those having composite replacement of the aortic root [8].

Dietzman and colleagues [9] reported the first successful MVR in a patient with the Marfan syndrome in 1967. The following year, Sirak and Ressallat provided late follow-up data for two patients with the Marfan syndrome in whom they attempted mitral valve repair [10]. Using suture annuloplasty and posterior leaflet plication, they achieved temporary reduction of MR in both patients. Because MR recurred in both patients within 2 years, they concluded that the underlying tissue defect prohibited durable repair. Other authors subsequently concurred with this conclusion [11] and MVR became the accepted treatment of MR in the patient with the Marfan syndrome.

In patients without the Marfan syndrome, Carpentier and colleague reported 89% freedom from reoperation 9 years after repair and Cosgrove and associates noted a 2-year actuarial freedom from reoperation of 96.1% [12,13].

It has been demonstrated that mitral valve dysfunction is progressive in 56% of patients with the Marfan syndrome. Therefore, in the setting of aortic root replacement, mitral valve repair was attempted when MR is 2+ or greater. Mitral repair can be done quickly and safely in these patients, and it may obviate

the need for further cardiac operations to correct progressive mitral dysfunction. Mitral valve repair in patients with the Marfan syndrome offers a challenge to the surgeon. Pronounced annular dilation, anterior leaflet disease, and ventricular remodelling that occurs after aortic root replacement can complicate mitral valve repair [6].

In our case, Minimally Invasive approach provided the patient with early recovery and lesser morbidity. Right anterior thoracotomy not only avoided the complications and morbidity related to redo sternotomy but also saved the manoeuvring of the previously placed pectus excavatum reconstruction plate. Use of Cor-knots also provided greater ease in implanting the prosthetic valve at mitral position.

References

1. Harrison's-Principles of Internal medicine (18th Edition).
2. Loeys BL (2010) Revised Ghent criteria for the diagnosis of Marfan syndrome and related conditions. *J Med Genet* 47: 476-485.
3. Pyeritz RE (2000) The Marfan syndrome. *Annu Rev Med* 51: 481-510.
4. Van Karnebeek CD, Naeff MS, Mulder BJ, Hennekam RC, Offringa M (2001) Natural history of cardiovascular manifestations in Marfan syndrome. *Arch Dis Child* 84: 129-137.
5. Gillinov AM, Hulyalkar A, Cameron DE, Cho PW, Greene PS, et al. (1994) Mitral valve operation in patients with the Marfan syndrome. *J Thorac Cardiovasc Surg* 107: 724 -731.
6. Pyeritz RE, Wappel MA (1983) Mitral valve dysfunction in the Marfan syndrome. *Am J Med* 74: 797-807.
7. Pini R, Roman MJ, Kramer-Fox R, Devereux RB (1989) Mitral valve dimensions and motion in Marfan patients with and without mitral valve prolapse. *Circulation* 80: 915-924.
8. Helder MR, Schaff HV, Dearani JA, Li Z, Stulak JM, et al. (2014) Management of mitral regurgitation in Marfan syndrome: Outcomes of valve repair versus replacement and comparison with myxomatous mitral valve disease. *J Thorac Cardiovasc Surg* 148: 1020-1024.
9. Dietzman RH, Peter ET, Wang Y, Lillehei RC (1967) Mitral insufficiency in Marfan syndrome. *Dis Chest* 51: 650-658.
10. Sirak HD, Ressallat MM (1967) Surgical correction of mitral insufficiency in Marfan's syndrome. *J Thorac Cardiovasc Surg* 55: 493-500.
11. Nelson RM, Vaughn CC (1968) Double valve replacement in Marfan's syndrome. *J Thorac Cardiovasc Surg* 57: 732-737.
12. Carpentier A, Chauvaud S, Fabiani JN, Deloche A, Relland J, et al. (1980) Reconstructive surgery of mitral valve incompetence. *J Thorac Cardiovasc Surg* 79: 338-348.
13. Cosgrove DM, Chavez AM, Lytle BW, Gill CC, Stewart RW, et al. (1986) Results of mitral valve reconstruction. *Circulation* 74: 182-187.