

## Case Report

# Minimal Undermining Suspension Technique (MUST): An Innovative Technique for Mini-Invasive Approach for Periocular Rejuvenation

Alessandro Gualdi\*, Jonatann Gatti, Francesco Binaschi, Massimiliano Gioco

Surgical Medical Group, Piazzale Biancamano 2/2, 20121 Milano, Italy

**\*Corresponding author:** Alessandro Gualdi, Department of Plastic and Aesthetic Surgery, Clinical Professor at University of Milano Bicocca and Clinical Professor at CLOPD Vita-Salute University San Raffaele, 20121 Milano, Italy. Tel: +02 89367184; E-mail: alegualdi@yahoo.it

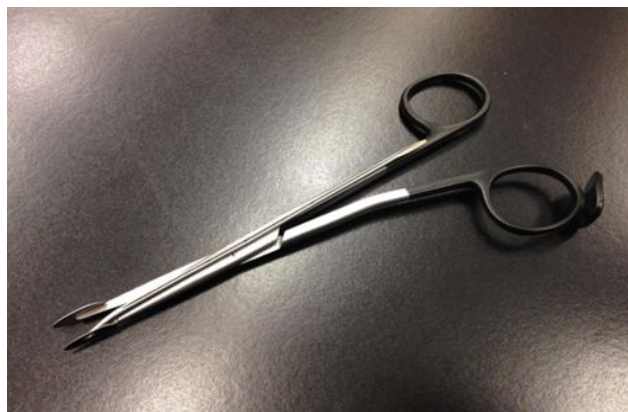**Citation:** Gualdi A, Gatti J, Binaschi F, Gioco M (2017) Minimal Undermining Suspension Technique (MUST): An Innovative Technique for Mini-Invasive Approach for Periocular Rejuvenation. Plast Surg Mod Tech 2: 110. DOI: 10.29011/2577-1701.100010

**Received date:** 17 February, 2017; **Accepted date:** 8 April 2017; **Published date:** 17 April, 2017

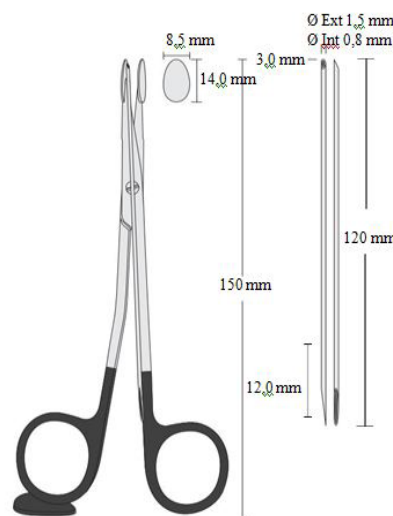
Nowadays, low surgical risk and complications are an extremely important topic, and are therefore results to achieve, in every surgical field, especially in aesthetic plastic surgery [1]. Surgical interventions for aesthetic purposes are usually associated with higher complication rates and longer recovery times when compared to less invasive treatments and this has led to the popularity of injectable solutions for facial rejuvenation treatments.

Recently, new knowledge of the facial aging process and its anatomy has been discovered, focusing especially on the malar region and its importance in the aging process of the mid face. According to those findings, it's noticeable an increased development of new techniques and tools to analyze facial aging [2,3].

Here we present a minimally invasive surgical technique for facial rejuvenation, the MUST technique, performed using an innovative tool, the MUST dissector (Figure 1) which allows a safe dissection of anatomical tissue planes to perform safely a mid-face and eyebrow lift.



**Figure 1a:** The minimal undermining suspension technique MUST dissector.

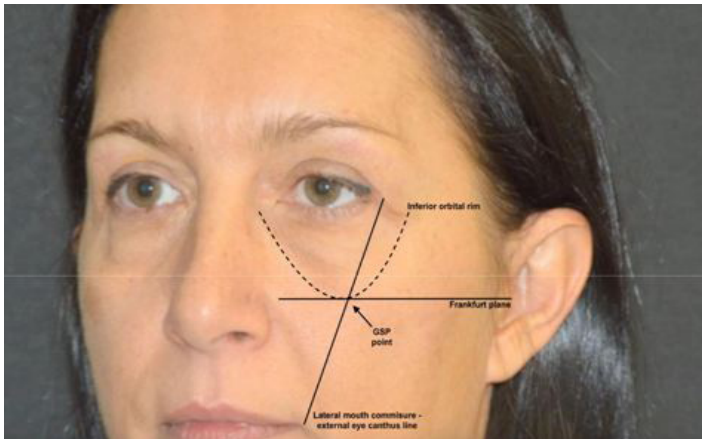


**Figure 1b:** The minimal undermining suspension technique MUST dissector - schematics.

The MUST is the first combined mid-face and brow lifting technique through a single temporal access that can be performed under local anesthesia. All patients received 0.5 mg/kg of Diazepam as premedication one hour prior to the surgical procedure. After disinfection of skin and draping of the surgical area, the temporal incisions are marked on both sides. Subsequently, tumescent anesthesia is infiltrated using a 30 Gauge needle (Solution composition: 0.3% lidocaine, 1:650,000 adrenaline, and 2mEq of sodium carbonate).

Ten minutes after the local anesthesia has been injected, the temporal incisions of approximately 1.5 cm is performed, 3 cm behind the hairline above the temporalis muscle, along a line between the lateral wing of the nose and the lateral canthus. The inci-

sion is performed down to the superficial temporalis fascia. The fascia is cut and directly under the superficial temporalis fascia, right above the deep temporalis muscle fascia the dissection of the tissue planes is performed using the MUST dissector. This is done from cranial to caudal through the medial temporal septum, going through the anterior third of the zygo-matic area directly lateral to the epicanthal fold without touching the orbitomalar ligament (ORL). When reaching the pre zygo-matic space, beneath the superficial muscular aponeurotic system (SMAS), the orbicularis muscle until the zygo-matic malar ligament can be dissected. By staying within this surgical plane, the frontal branches of the facial nerve are preserved from injury. A resorbable suture is then positioned at the point of intersection between the Frankfurt plane and the line between the lateral canthus and the lateral mouth commissure (Figure 2). This point is called the “G suspension point” (GSP) [4].



**Figure 2:** GSP point

The MUST dissector facilitates tunneling between the tissue planes via gentle dissection. By instrument design, it allows to safe and quick stitch placement with absorbable suture material at the distal portion of the undermined tissue at the GSP. For this stitch, Monocryl 2.0 (Ethicon Inc, Sommerville, NJ, USA), an absorbable suture with a straight triangular needle is used. After extracting the needle from the skin in the malar area, the needle is re-inserted through the same tunnel. Performing, then, a horizontal lop through the crest of the orbicular malar paddle and SMAS for approximately 1 cm, after an incision of 2 mm with the scalpel in

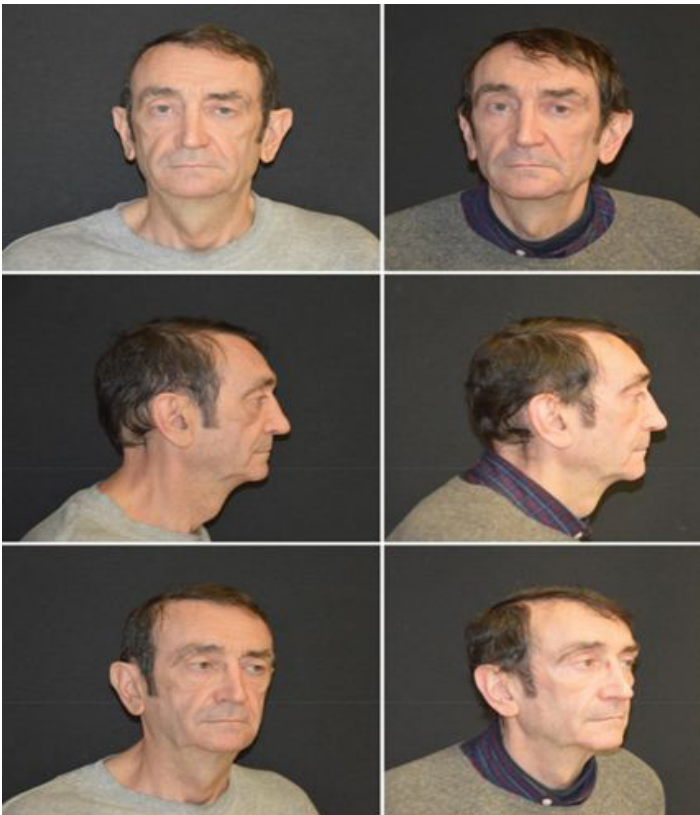the previous exit point of the needle is performed. The amount of suspension and the correct vertical vector are then calibrated according to each patient's needs while attempting to reposition the paddle cranially into his original position, slightly overcorrecting the suture. The suture is then re-extracted through the temporal incision and temporally secured with a mosquito forceps. Next, using a periosteal elevator from the temporal incision, the first dissection is performed in direction to the lateral eyebrow tail under the periosteum of the temporal bone. This is also performed medially through the temporal crest to detach the insertion on the orbital frame and completely release the above tissue flap from the bone. The Monocryl 2.0, previously secured to the mosquito, is brought into the desired position and stitched to the temporal fascia. Last-ly, using an absorbable suture, the temporal brow flap is repositioned by stitching it to the temporal fascia. Skin is adapted using single stitches.

#### **The Technique is followed by a Short Recovery Time with Low Incidence of Complication.**

The average time of the surgical procedure is 15 minutes per side, and the average downtime is of 7 days while the stitches are removed 10 days postoperatively. In our practice an amount of 55 patients underwent facial rejuvenation using MUST and the overall complication rate was 19%, whereas 18 patients (15%) developed an ecchymosis of the orbicular temporal region and two patients (4%) developed a dimple caused by the anchor of the suture. No displacements of the palpebral rim or injuries of the facial nerve were observed and no long-term complications were seen.

Just one patient required an additional surgical intervention and thus, the overall complication rate regarding major complications is fairly low especially when compared to other traditional face lift approaches and other minimally invasive face lifting procedure. Since the subjective aesthetic outcome results are the cornerstone of aesthetic procedures, the lifting effect and the rejuvenation effect are analyzed at a 12 month follow up appointment. Subjective results of patient's and surgeon's perceptions show outstanding results in all assessed measurements.

The MUST can be seen as a less invasive surgical procedure almost comparable to a dermal filler injection and thus we can recommend it as a surgical option for patients who are looking for a valid mid-face and brow lift procedure with a natural result, low incidence of complication and a short downtime (Figure 3).



**Figure 3:** Pre and 12 month postoperative pictures of a 58 old male patient.

## References

1. Jansma J, Schepers RH, Vissink A (2014) [Lifting procedures in cosmetic facial surgery]. *Nederlands tijdschrift voor tandheelkunde*, Lifting procedures in de cosmetische aangezichts chirurgie 121: 507-515.
2. Warren RJ, Aston SJ, Mendelson BC (2011) Face lift. *Plastic and reconstructive surgery* 128: 747e-764e.
3. Bertossi D, Mortellaro C, Nocini PF (2015) Facial Filler Grid (FAFI GRID): A New Method of Facial Analysis. *The Journal of craniofacial surgery* 26: 860-862.
4. Gualdi A, Cambiaso-Daniel J, Gatti J, Bertossi D, Pietramaggiori G, et al. (2017) Minimal Undermining Suspension Technique (MUST): Combined Eyebrow and Mid-face Lift via Temporal Access. *Aesthetic Plast Surg* 41: 40-46.