

Case Report

Luteinized Thecoma with Sclerosing Peritonitis: Clinical Case Report and Review of the Literature

Francesc Fargas Fabregas^{1*}, Claudia B. Blancafort¹, Francesc Tresserra Casas², Betlem Graupera Nicolau³, Rafael Fábregas Xauradó¹

¹Gynecologist, Oncologist, of Hospital Universitari Quiron Dexeus, Barcelona, Spain

²Pathologist of Hospital Universitari Quiron Dexeus, Barcelona, Spain

³Doctor from the Department of Diagnosis by image of the Hospital Universitari Quiron Dexeus, Barcelona, Spain

*Corresponding author: Francesc Fargas Fabregas, Institut Universitari Dexeus, Gran via Carles III, 71-75, 08028, Barcelona, Spain. Tel: +34932274700; Email: FRAFAR@dexeus.com

Citation: Fargas Fabregas F, Blancafort Gonzalez-Casabon C, Tresserra Casas F, Graupera Nicolau B., Fábregas Xauradó R (2018) Luteinized Thecoma with Sclerosing Peritonitis: Clinical Case Report and Review of the Literature. Arch Surg Clin Case Rep: ASCR-103. DOI: 10.29011/ASCR-103/100003

Received Date: 27 May, 2018; **Accepted Date:** 05 June, 2018; **Published Date:** 13 June, 2018

Abstract

Ovarian thecoma is a rare entity, and even more so when associated with sclerosing peritonitis. The low incidence, and the scant number of cases described in the literature, makes it very difficult to treat. It tends to present in young women, and while not malignant, the torpid evolution presented by these patients, despite multiple treatments and surgery, makes for a very poor prognosis, including total dependence on lifelong parenteral feeding or even death from related complications; the prognosis is on a par with most malignant tumours.

We are presenting the case of a 31-year-old patient who, following 12 months of multiple treatments and who was incapable of leading a normal life for one year, eventually died from the complications derived from this purportedly benign condition.

Introduction

Bilateral ovarian thecoma associated with sclerosing peritonitis is a rare condition that has been described in the literature in the form of isolated cases or in series of few cases. Its evolution is torpid and difficult to diagnose due to the way it presents, often simulating an ovarian neoplasm. Its aetiology is relatively unknown, there is no real consensus-based treatment and the prognosis is uncertain [1-6].

We are presenting a case of bilateral ovarian thecoma associated with sclerosing peritonitis in a young female patient with ascites and overlapping clinical symptoms.

Clinical Case

The patient was 31 years old, she had had a Caesarean section 2 years previously, and was a smoker of 1 pack of cigarettes a day.

She went to the emergency room with symptoms of abdominal discomfort and increased peristalsis accompanied by diarrhoea without pathological findings. A blood analysis was performed in

the emergency room, with mild hypercholesterolaemia being the only noteworthy finding. The abdominal ultrasound showed mild ascites and the chest x-ray right pleural effusion. The study was completed with a thoracoabdominal CT scan which confirmed the findings and also showed a slightly enlarged ovary (right ovary: 5 cm, left ovary: 6 cm) of non-neoplastic appearance without significant adenopathies.

In view of the inconclusive symptoms, the patient was seen by different specialties: digestive, pneumology and endocrinology. Further studies were performed, including the evaluation of acute-phase reactants, autoimmune profile (anti-endomise Ab, negative anti-transglutaminase Ab, with only some positive ANA CA being of note), negative tumour markers (CA 15.3, CA 19.9, CA 125, HE4) and even intolerance studies, all of them normal.

The patient came to our department for a second opinion on account of the increased adnexa described in the emergency room CT scan. The abdominal exploration showed a distended abdomen, whereas enlarged, mobile and adnexal masses were detected in the vaginal palpation, with the pouch of Douglas unaffected.

A transvaginal ultrasound performed only 2 months after the CT scan showed Score 4 bilateral tumours of 9 and 8 cm, both of them vascularised. It also confirmed the presence of abundant free fluid in the abdomen, with an overall appearance consistent with newly-formed growth (Figure 1).

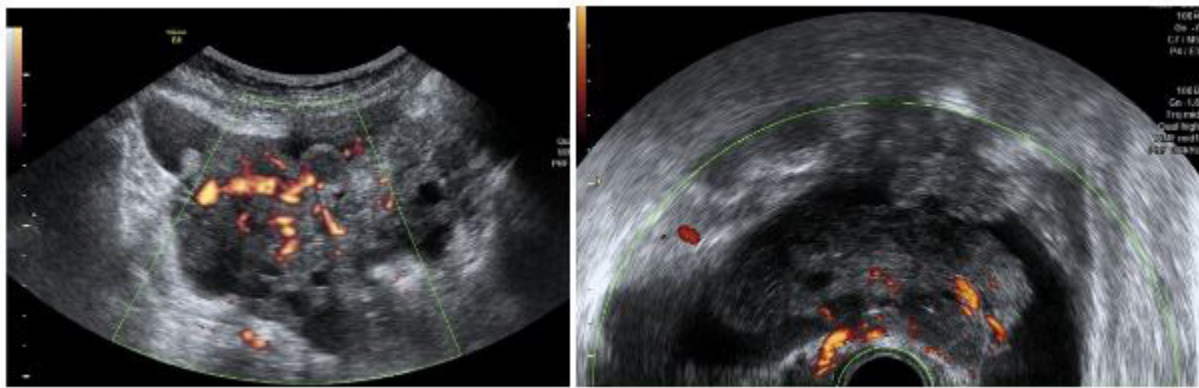


Figure 1: The right ovarian shows a solid and heterogeneous 93 x 32 mm tumour presenting vascularisation in the Doppler study (score 4). The left ovarian shows a solid and heterogeneous 83 x 54 mm tumour presenting vascularisation in the Doppler study (score 4).

These findings yielded differential diagnoses suggesting either Meigs syndrome or bilateral malignant ovarian tumour, whereby the decision was taken to perform a diagnostic-surgical laparoscopy.

Ascitic fluid was observed and aspirated during surgery. A histological study was performed showing inflammatory liquid. Two bilateral tumours were observed (Figure 2), and a right adnexectomy was performed. The left adnexum was biopsied, and peritoneal biopsies were performed and examined perioperatively, proving to be benign.

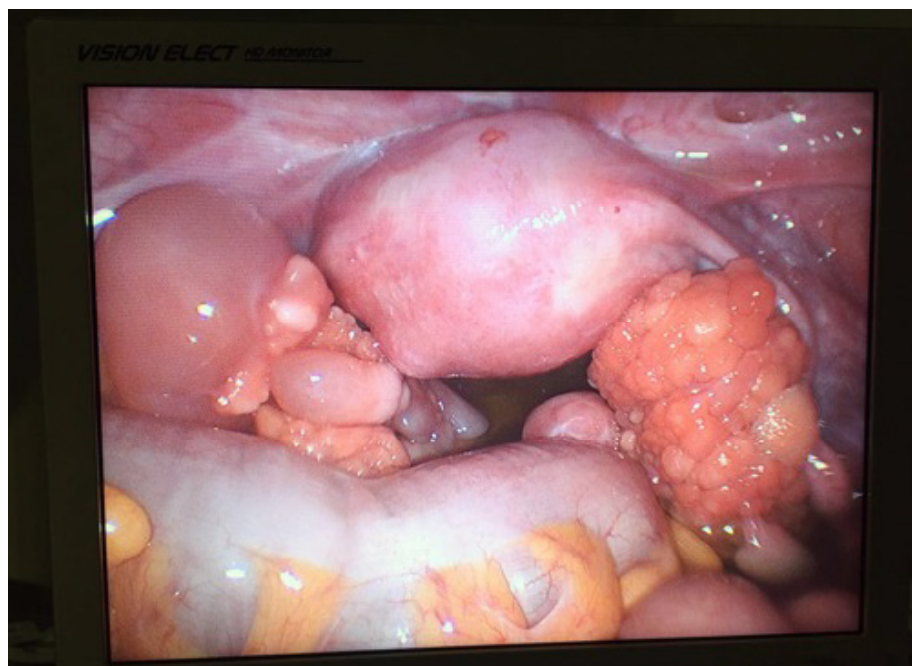


Figure 2: Anatomico-pathological description of the right ovarian: tissue fragments with a solid papillary configuration, elastic consistency and reddish-whitish colour weighing 57.8 g overall and measuring 10x6.5x3.5cm. Partial inclusion.

The patient's postoperative evolution was satisfactory, and she was discharged 24 hours later.

Five days after the laparoscopy, the patient began to exhibit symptoms of abdominal discomfort with distension, incoercible nausea and vomiting and food intolerance.

The most salient finding of the physical exploration was distended abdomen with ascitic semiology. The blood analysis only pointed to an elevated CRP of 36mg/L. The gynaecological ultrasound and the CT scan corroborated the presence of bilateral ascitic and pleural fluid with no further findings.

The case was regarded as a possible pseudo-Meigs syndrome, consisting of ascitic and pleural fluid associated with ovarian stromal tumour. In view of the patient's poor condition, the definitive surgical treatment – once again a laparoscopy - involving a left adnexectomy, peritoneal biopsies and ascitic fluid cytology, was brought forward.

More than 3 L of ascites were aspirated in the surgery. The definitive pathological finding reached the same conclusion as in the previous surgery on the left ovary, whereas the peritoneal biopsy showed signs of fibrosis, sclerosis and chronic inflammation.

However, the immediate post-operative process was torpid from the outset. The patient presented poor fluid tolerance from the early hours, with heavy vomiting and abdominal distension. A new CT scan was performed less than 48 hours after surgery, showing abundant ascitic and pleural fluid with major gastric distension and no other findings.

As there were no disease remnants in the cavity, rendering a pseudo-Meigs less likely, and suspecting ascites secondary to imbalance, we requested a consult from Internal Medicine, which decided to insert a central line, with nasogastric intubation and feeding in view of the suspicion of paralytic ileus and third-space caused by dyselectrolytemia and hypoalbuminaemia.

The differential diagnoses considered included a dynamic ileus, which did not remit spontaneously after a week, as well as ascites caused by imbalance, which could not be justified because it did not remit following the correction of the hypoalbuminaemia and because there were no associated oedemas.

Mechanical ileus caused by possible post-surgical adhesions was suspected and an abdominal evaluation with contrast medium -Gastografin - was performed.

On the abdominal x-ray, the contrast medium was not seen to enter the colon. Although the CT scan provided no information in this regard, we suspected an occlusion caused by adhesion that had not resolved after three days of conservative treatment. We spoke to the patient, who remained clinically unchanged, and decided to perform an exploratory laparoscopy.

This third operation showed that the abdomen was full of slightly haemorrhagic ascites fluid, although it proved impossible to view the abdominal cavity despite aspiration. Palpation showed a hardened intestinal mass. The decision was taken to convert to a midline laparotomy.

A further 3 L of fluid were aspirated, a complicated attempt was made to free the entire small intestine, and no adhesions or strictures were observed. The intestinal wall was highly engorged and swollen, with serosa that detached easily and was highly prone to tearing. Peritoneal biopsies were performed. Following surgery, the patient was admitted to the ICU and was discharged 48 hours later.

The pathological anatomy showed a very rare entity: the intestine presented sclerosing peritonitis. These symptoms of ascites with bilateral ovarian tumour and sclerosing peritonitis in a young patient prompted us to reconsider the anatomopathological diagnosis of the ovarian lesions.

The definitive anatomopathological report described a stromal tumour with mild atypia and abundant mitotic figures. The immunohistochemical techniques were negative for Cytokeratin AE1/AE3 (Diagnostic Biosystems, AE1/AE3), Cytokeratin 20 (Ventana, SP33), Cytokeratin 7 (Ventana, SP52), Cytokeratin CAM 5.2 (Ventana, CAM5.2), Actin (Cell Marque, 1A4), Epithelial Membrane Antigen (EMA) (Ventana, E29), CD31 (Cell Marque, JC70), Inhibin (Cell Marque, R1), Calretinin (Ventana, SP65) and WT-1 (Cell Marque, 6F-H2). And positive for: Vimentin (Ventana, V9), CD99 (Ventana, O13). The proliferative index measured with KI-67 (Ventana, anti-Ki-67 (30-9)) was 15% of cells. Although the immunohistochemical findings were somewhat inconclusive, we reached the conclusion that it was a stromal tumour with an uncertain malignant potential (Figure 3).

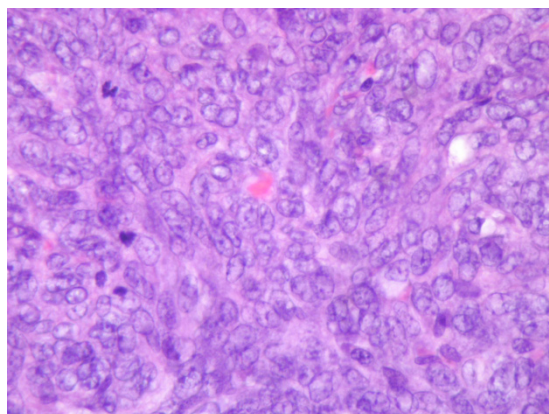


Figure 3: (Left ovary) Ovary with thick surface papillar (HE x 40).

Post-operatively, the patient presented stiff abdomen without peristalsis. With the diagnosis of luteinised thecoma with

sclerosing peritonitis, the case was discussed in a multidisciplinary committee and the decision was taken to initiate treatment with corticosteroids (methylprednisolone 1mg/kg) and with luteinising hormone-releasing hormone, after which the patient evolved slowly but favourably and her ascites improved, reaching a negative balance. The abdominal exploration gradually improved, the induration diminished and eventually only the paraumbilical and left side remained hard; despite this, the peristalsis continued to be negative. During hospitalisation, a PET-CT scan was also performed, which was negative.

Four (4) months after the last surgery, and in view of the patient's clinical stagnation, a gastrostomy was performed and home parenteral nutrition was arranged. Twelve months after the first surgery, the patient presented a fistula of the intestine and underwent emergency surgery in another hospital. Following a complicated 12-hour operation, a major intestinal resection was performed. The patient presented a torpid postoperative process and died from sepsis 15 days after surgery.

Discussion

Luteinised thecoma associated with sclerosing peritonitis is a very rare entity, with only some 50 cases described in the literature, very heterogeneously. A work by Staats PN from 2008 includes the greatest number of cases and is the most structured one. It contains a total of 27 clinical cases, although an immunohistochemical study is only available for 13 of them [1].

It is important to stress that luteinised thecoma exists as a separate entity and is not necessarily associated with sclerosing peritonitis, for which reason the authors decided to name the symptoms presented by our patient "Thecomatosis". Besides the clinical differences, i.e. the presence of ascites and peritonitis, there also appears to be a certain histological difference. The thecomatoses present smaller and more poorly-formed clusters of luteinised cells and greater mitotic activity, rendering them more likely to be mistaken for a malignant condition [2].

This condition may appear in woman of any age range, although it is more frequent in the second and third decades of life. Presentation is usually similar to our case: abdominal distension, palpable abdominal mass, nausea..., although multiple and highly-varied associated symptoms have also been described [4].

With regard to background, attempts have been made to relate it to the taking of medication, and anticonvulsants and beta-adrenergics have been described, albeit in isolated cases [3]. The study by Staats PN is striking in that 4 of the patients had suffered autoimmune events, and more specifically there were 2 cases of lupus: one prior to the thecomatosis and another that developed subsequently. Our patient presented ANA+ antibodies, although this association is evidently unclear.

The luteinised thecomas associated with sclerosing peritonitis are mainly bilateral. Microscopically, the tumours described in the literature range from a size of 2 cm to 31 cm and normally have a reddish surface and a lobulated appearance.

Microscopically, particularly noteworthy is the cortical involvement preserving the medulla in smaller tumours, with a proliferation of burr and luteinised cells trapping normal tissue structures, such as follicles, on the inside. Moreover, most of the lesions present high mitotic activity [2].

From the first few cases in which these tumours were described, there were anatomopathological doubts as to whether they were neoplastic lesions, since microscopically they are usually large, present a substantial effacement of ovarian tissue and may also include a high number of mitoses.

However, there are two important facts that suggest that they are benign. The first is that there is normal tissue with follicles encased in the middle of the tumour. Curiously enough, in the ovary, this usually constitutes evidence of a non-neoplastic process, and very rarely occurs in primary ovarian tumours. In other locations, the infiltration of malignant tissue adjacent to healthy tissue is frequent and as such is regarded as malignant. The second is the fact that the cortex is initially diffusely involved and the medulla of ovary is maintained. Neoplasms tend to grow expansively and concentrically, and from the neoplastic standpoint it is difficult to imagine a mechanism that could account for this form of growth. The same applies to bilaterality, virtually constant in these tumours [7].

Moreover, immunohistochemistry does not help to ascertain the nature of these lesions. For this reason, it is very difficult for the pathologist to identify this entity from the outset in view of the extremely low frequency of this condition and the lax criteria.

Sclerosing peritonitis is an acquired condition resulting from a peritoneal inflammation triggered by different factors, in which the small intestine or other intraabdominal organs, oedematous and hardened, are encapsulated in a thin fibrocollagen membrane.

It tends to present clinically as an intestinal obstruction and exhibits very unspecific signs in the imaging tests, whereby it is usually diagnosed intraoperatively [7,8].

Depending on its aetiology, it is categorised as idiopathic/primary or secondary. Idiopathic sclerosing peritonitis is also known as "cocoon syndrome" and there is no evidence of an underlying cause. It tends to occur in adolescents in tropical and subtropical countries [9].

In secondary sclerosing peritonitis, there is some type of factor, local or systemic, that triggers the peritoneal inflammation. It is much more common than the primary form, although their aetiologies are very different [10]. Peritoneal dialysis is the most frequent cause, followed by peritoneal tuberculosis. Much less

frequently, it has been described in association with unspecific abdominal surgery, autoimmune disorders, certain drugs or gynaecological pathologies such as endometriosis, dermoid cysts or, as in our case, luteinised thecomas [9-14]. The onset of peritonitis associated with luteinised thecoma usually takes place, as in our case, after a bilateral adnexectomy.

Histologically they are fibrous and hardened lesions with a proliferation of burr cells amidst abundant oedema and inflammatory infiltrate. Neither is the aetiopathogenesis of extraovarian sclerosing involvement known. A metastatic mechanism has been mooted in which the primary lesion of the ovary would secrete fibroblast substances, triggering extraovarian lesions such as the peritoneum [15]. However, this theory is somewhat unrealistic, since peritoneal lesions are mitotically inactive, they do not present a malignant clinical course and, moreover, sclerosing peritonitis usually develops even after a bilateral adnexectomy [2].

The second theory holds that the ovaries and the peritoneum react to an unknown external humoral stimulus [9,16].

There is no suitable consensus-based treatment for patients with thecomatoses, and nor is there any evidence of the value of treatment. As the aetiopathogenesis is not properly known, it is not even clear that the bilateral adnexectomy is indispensable, since there have been cases in which patients with tumour remnants did not present a clinically better evolution than those that underwent extensive dissection.

There is only one case in the literature that appeared to respond significantly to antiestrogens and LHRH analogues, and some reports suggest that tamoxifen improves sclerosing peritonitis associated with peritoneal dialysis [4-6]. This is all based on the fact that some tumours have presented positive receptors for Oestrogens and for Progesterone, although this is variable and is also typical of many mesenchymal tumours.

A couple of cases of treatment with prednisone have also been described, although its efficacy was doubtful, and the decision to treat was taken on the basis of possible autoimmune causes [4-6].

In terms of prognosis, there seems to have been no distant metastases, thus supporting the non-malignancy theory. However, patients have very difficult clinical courses, with highly prolonged ileuses or intermittent episodes of obstruction. Fistulisations and pulmonary embolisms have also been described. Deaths caused by the condition's complications (fistulae, infections and very aggressive surgery) have been reported. In the study by Staats PN, 15 of the 27 patients eventually became symptom-free following periods of 7 months and 12 years with different kinds of episodes associated with their disease [1].

Conclusions

It is a very rare entity with few cases described in the literature. This makes diagnosis and treatment difficult, with the latter depending on the different theories described and tested in some patients.

The main problem lies in the sclerosing peritonitis, which has different aetiologies, some of which respond to the treatment of the base disease, either with corticosteroids, hormone or autoimmune treatments, and others that do not respond to any of these therapies. The torpid evolution, with very prolonged paralytic ileus, leads to poor patient quality of life, with risks of malnutrition, infections and fistulae that may render it necessary to perform major surgery that only increases the risks to the patient, including infections, major intestinal resections and even death, as in our case.

Acknowledgements

Under the auspices of the Càtedra d' Investigació en Obstetrícia i Ginecologia from Universitat Autònoma de Barcelona.

References

1. Staats PN, McCluggage WG, Clement PB, Young RH (2008) Luteinized thecomas (thecomatosis) of the type typically associated with sclerosing peritonitis: A clinical, histopathologic, and immunohistochemical analysis of 27 cases. *Am J Surg Pathol* 32: 1273-1290.
2. Mellembakken JR, Engh V, Tanbo T, Czernobilsky B, Edelstein E, et al. (2010) Mitotically active cellular luteinized thecoma of the ovary and luteinized thecomatosis associated with sclerosing peritonitis: Case studies, comparison, and review of the literature. *Pathol Res Pract* 206: 744-748.
3. Clement PB, Young RH, Hanna W, Scully RE (1994) Sclerosing peritonitis associated with luteinized thecomas of the ovary. A clinicopathological analysis of six cases. *Am J Surg Pathol* 18: 1-13.
4. Bianco R, de Rosa G, Staibano S, Somma P, Bianco AR (2005) Ovarian luteinized thecoma with sclerosing peritonitis in an adult woman treated with leuprolide and toremifene in complete remission at 5 years. *Gynecol Oncol* 96: 846-849.
5. Levavi H, Sabah G, Heifetz M, Feinmesser M (2009) Sclerosing peritonitis associated with bilateral luteinized thecoma, linked to anticonvulsant therapy. *Eur J Gynaecol Oncol* 30: 695-700.
6. Spiegel GW, Swiger FK (1996) Luteinized thecoma with sclerosing peritonitis presenting as an acute abdomen. *Gynecol Oncol* 61: 275-281.
7. Russell P, Robboy SJ, Anderson MC (2002) Ovary: normal and benign conditions. In: Robboy SJ, Anderson MC, Russell P, eds. *Pathology of the Female Reproductive Tract*. Edinburgh: Churchill Livingstone. Pg no: 475-526.
8. Young RH, Scully RE (1984) Fibromatosis and massive edema of the ovary, possibly related entities: a report of 14 cases of fibromatosis and 11 cases of massive edema. *Int J Gynecol Pathol* 3: 153-178.

9. Tannoury JN, Abboud BN (2012) Idiopathic sclerosing encapsulating peritonitis: abdominal cocoon. *World J Gastroenterol* 18: 1999-2004.
10. Kumar A, Ramakrishnan TS, Sahu S, Mishra KB (2009) Idiopathic sclerosing encapsulating peritonitis--is a preoperative diagnosis possible? Report of three cases. *Surg Today* 39: 610-614.
11. Browne LP, Patel J, Guillerman RP, Hanson IC, Cass DL (2012) Abdominal cocoon: a unique presentation in an immunodeficient infant. *Pediatr Radiol* 42: 263-266.
12. Sreevathsa MR, Harsha AH (2013) Chronic encapsulating peritonitis or cocoon abdomen. *Trop Gastroenterol* 34: 204-206.
13. Serter A, Kocakoç E, Çipe G (2013) Supposed to be rare cause of intestinal obstruction; abdominal cocoon: report of two cases. *Clin Imaging* 37: 586-589.
14. Gadhire M, Singh MB, Jshi M (2013) Abdominal cocoon syndrome. *JEMDS* 2: 1857-1861.
15. Lo WK, Chan KT, Leung AC, Pang SW, Tse CY (1991) Sclerosing peritonitis complicating prolonged use of chlorhexidine in alcohol in the connection procedure for continuous ambulatory peritoneal dialysis. *Perit Dial Int* 11: 166-172.
16. Li N, Zhu W, Li Y, Gong J, Gu L, et al. (2014) Surgical treatment and perioperative management of idiopathic abdominal cocoon: single-center review of 65 cases. *World J Surg* 38: 1860-1867.