

## Case Report

Marmolejo JCM, et al. Arch Surg Clin Case Rep 3: 140.

DOI: 10.29011/2689-0526.100140

## Intraluminal Clots in the Postoperative Period of a Hepaticojejunostomy: Rare Complication for Rapid Action

Juan Carlos Marín Marmolejo<sup>1</sup>, Luis Antonio Sarmiento<sup>2\*</sup>, Juan David Martínez<sup>3</sup><sup>1</sup>Physician, Specialist in General Surgery, Coloproctologist surgeon SES Hospital de Caldas, Colombia<sup>2</sup>Internal Physician, Surgery and Research Seed Coordinator (SECIN), University of Caldas, Colombia<sup>3</sup>Internal Physician, University of Caldas, Colombia

**\*Corresponding author:** Luis Antonio Sarmiento, Internal Physician, Surgery and Research Seed Coordinator (SECIN), University of Caldas, Colombia

**Citation:** Marmolejo JCM, Sarmiento LA, Martínez JD (2020) Intraluminal Clots in the Postoperative Period of a Hepaticojejunostomy: Rare Complication for Rapid Action. Arch Surg Clin Case Rep 3: 140. DOI: 10.29011/2689-0526.100140

**Received Date:** 14 July, 2020; **Accepted Date:** 10 August, 2020; **Published Date:** 14 August, 2020

### Abstract

Intestinal obstruction due to intraluminal clot is a rare postoperative complication reported in the literature. We report the case of a patient with intestinal obstruction due to postoperative intraluminal clots of a Roux-Y hepaticojejunostomy.

**Clinical Case:** A 53-year-old male patient presented with recurrent cholangitis, secondary to benign stenosis of the bile duct after laparoscopic cholecystectomy, performed 2 years ago. In its management with endoprosthesis by retrograde cholangiopancreatography Endoscopic surgery (ERCP) did not improve his episodes of cholangitis, so a move to a hepaticojejunostomy type reconstruction was considered. In the early postoperative period, she presented signs of intestinal obstruction. Contrast abdominal Computed Tomography (CT) showed free fluid and signs of obstruction. He was taken to emergency surgery, finding the Roux-en-Y anastomosis obstructed by a large intraluminal clot, requiring an enterotomy for its extraction. Discussion: Postoperative intestinal obstruction secondary to an intraluminal clot is unusual, it should be suspected in patients with symptoms of intestinal obstruction. The ideal method for diagnosis is tomography and treatment is with relaparotomy to remove the clots. Knowledge of this entity is important for any doctor, since it is a rare complication in which a good diagnostic suspicion and timely treatment are needed.

**Keywords:** Gastrectomy; Intestinal obstruction; Postoperative period; Small intestine; Thrombosis

### Introduction

An intestinal obstruction due to intraluminal blood clots is a postoperative complication that is infrequently reported in literature. We reported the case of a patient with an intestinal obstruction due to postoperative intraluminal blood clots from a Roux-en-Y hepaticojejunostomy. Clinical Case: A 53-year-old male patient appeared with recurring cholangitis secondary to a benign stenosis of the bile duct after a laparoscopic cholecystectomy performed 2 years prior. Treatment with an endoprosthesis by endoscopic retrograde cholangiopancreatography (ERCP) did not improve cholangitis episodes, for which reason transition to reconstruction by hepaticojejunostomy was considered. He showed signs of intestinal obstruction during early postoperative care. The Computed Tomography (CT) scan of the abdomen with contrast showed free fluid and signs of obstruction. The

patient was taken to an emergency surgery, where the Roux-en-Y anastomosis was found to be obstructed by a large intraluminal blood clot. It required an enterotomy to be extracted. Discussion: A postoperative intestinal obstruction secondary to intraluminal blood clots is unusual, but must be suspected in patients with symptoms of intestinal obstruction. The ideal method for diagnosis is by tomography and treatment involves a relaparotomy to extract the blood clots. It is important for doctors to have knowledge of this condition, since it is a rare complication that requires good diagnostic insight and timely treatment. Palavras-chave: Thrombose; Small intestine; Intestinal Obstruction; Gastrectomy; Post-operative period. Intestinal obstruction due to intraluminal clot is a rare postoperative complication reported in the literature, among its causes is Roux Y, which has been widely used in procedures such as gastrectomy for cancer, gastric bypass for obesity and in hepaticojejunostomy or choledochojejunostomy as an end-to-end anastomosis [1]. Complication rates for Roux-en-Y hepaticojejunostomy are relatively low in large series [2,3] but are

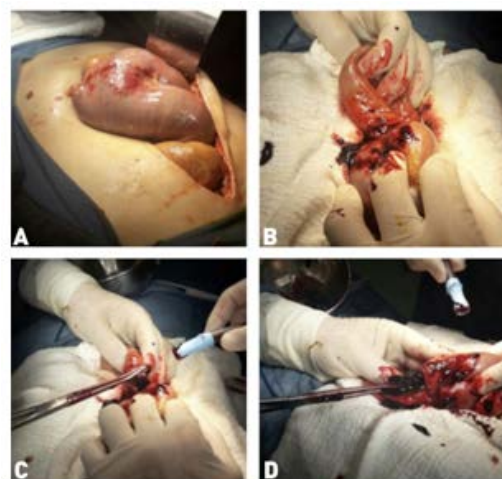
of important consideration to the surgeon, as this is a complication in which prompt repair is required.

The prevalence of intestinal obstruction due to postoperative clots in hepaticojejunostomy is not known in the world and similar cases have not been reported in Colombia; However, the main cause of intestinal obstruction due to postoperative clots occurs in laparoscopic gastric bypass surgery and has an average presentation time of 15 days, with an approximate range of 5 to 15 days [4]. The different etiologies that generate intestinal obstruction after gastric bypass surgery include: non-compliance with diet in 46%, anastomotic edema in 23%, narrowing of the jejunostomy in 23% and intraluminal clots in 8% [4,5]. In hepaticojejunostomy, the main complications are intestinal obstruction (adhesion and intussusception), which represents 4.5% of complications, and approximately 4% of patients report pancreatitis or ascending cholangitis [3]. This is a very rare entity without reports at the national level, probably due to underreporting; however, it is highly suspicious for the diagnosis, since, in the event of this complication, rapid confirmation by images (mainly tomography) and timely treatment are necessary. As a goal, the formation of intraluminal clots that cause intestinal obstruction should be included in the differential diagnosis when faced with similar clinical findings in the immediate postoperative period after a hepaticojejunostomy, so it is important, for the surgeon and the general practitioner, the knowledge of this complication. We report the case of a patient with intestinal obstruction due to postoperative intraluminal hematoma of a Roux-Y hepaticojejunostomy. A 53-year-old male patient with a history of type 2 diabetes mellitus, arterial hypertension, grade III hepatic steatosis, stage V acute renal failure that required hemodialysis. In 2017, an open cholecystectomy was performed due to choledocholithiasis, which could not be resolved by ERCP; secondary to this, he presented recurrent cholangitis, which was managed one year later with ERCP endoprosthesis, presenting recurrence in episodes of cholangitis, for which no improvement was found.

It presents with a clinical picture of 10 days of evolution, consisting of abdominal pain in the epigastrium, generalized itching, fever of 38.5°, for which it is considered a diagnosis of cholangitis and antibiotic management is started. On physical examination, he was jaundiced, with pain on abdominal palpation and no signs of peritoneal irritation. A cholangioresonance was performed, which showed severe dilation of the extrahepatic bile duct and the Wirsung duct with the presence of stones inside; therefore, it was decided to perform reconstruction of the bile duct. It was decided to reconstruct the bile duct with Roux-Y with transmesocolic end-to-side hepatojejunal anastomosis, lateral lateral intestinal anastomosis and a subhepatic nelaton drain was installed, without intra-surgical complications, or in the immediate postoperative period. On the second postoperative day, he presented significant hematemesis without alteration of vital signs,

so it was decided to suspend enoxaparin and start an omeprazole drip. Subsequently, the hemoglobin drops to 8 g / dl, for which 2 units of blood cell concentrate are transfused. The next day, the hemoglobin rises to 9 g/dl without improvement in the condition.

The patient continues with abdominal pain and worsening of his general condition, a contrasted abdominal Computed Tomography (CT) is performed, which reveals signs of intestinal obstruction and free fluid, with occupation of the proximal intestine, for which he is taken to relaparotomy. An obstruction of the proximal small intestine is found secondary to tamponade by abundant clots at the level of the Roux-Y, a distal enterotomy is performed and 250 cc of intraluminal clots are extracted (Figure 1), the Roux-Y is reinforced in its anterior part, He installed an anterior drain close to the pylorus in case of rebleeding, the drain was extracted to the right flank, a 1-liter bag was left and transferred to the ICU. The patient evolves towards improvement, so he is transferred to hospital after 3 days and later.



**Figure 1:** A: Finding of intraluminal hematoma in Roux-Y, B: Enterotomy for clot extraction, C: Start of intraluminal clot extraction, D: Completion of intraluminal clot extraction.

When intestinal obstruction due to intraluminal clots occurs, hematemesis is a cardinal sign; Furthermore, it is important to regularly check the hemoglobin levels, as anemia is generated by intestinal bleeding [6]. Which must be replaced with hemoconcentrates if necessary, as was done in the patient. The use of computed tomography for patients with this clinical presentation has been the diagnostic method of choice [7]; in addition, computed tomography can provide important information on the cause and position of the obstruction and rule out other possible early postoperative complications [8]. Obstruction resulting from intraluminal blood clot formation in the small intestine is caused by inadequate hemostasis in the stapled anastomosis, inadequate verification of the anastomoses, or as a cause of undiagnosed pre-

existing disease, such as a clotting disorder and it is rarely seen in the immediate postoperative period [9]. In this case, adequate hemostasis was verified and the anastomosis was verified. Regarding comorbidities, in grade 3 hepatic steatosis that the patient presented, there is still no liver dysfunction that could explain any deficit in coagulation factors; However, the patient's chronic kidney failure, for which he required dialysis, may be the cause of coagulation dysfunction, which could have contributed to the complication presented.

The principles of the technique in hepaticojejunostomy that minimize the possibilities of complications include the low tension, the anastomosis should Start by being as large as possible and there should be complete apposition of the bile duct lining to the jejunal mucosa. Another important cause of obstruction as a differential diagnosis is intramural hematoma, which presents similar symptoms with a postoperative time similar to that of intraluminal clots; the first report of intramural hematoma in man was in 1838 by McLaughlan [10]. Cases of intestinal obstruction due to intramural hematoma and intraluminal clots have been described, mainly in trauma [11,12], laparoscopic gastric bypass with Y-de-Roux (8) [13-17], spontaneous obstruction as in the case of a child with 8 years [18], hemophilia [19], anticoagulant treatments [20-24] and as a complication of endoscopy [25]. Table 1 describes the cases of intraluminal clots with their causes.

Intraluminal Clots						
Year	Sex	Age of patient L	Place of obstruction	Cause	Treatment	Reference
2017	F	29	Jejuno-jejunostomy	Gastric bypass	Laparoscopy and enterotomy	9
2017	M	39	Pancreatic bile loop	Gastric bypass	Laparoscopy and enterotomy	29
2016	M	53	Jejuno-jejunostomy	Gastric bypass	Laparoscopy and enterotomy	14
2015	F	20	Not specified	Gastric ulcer	Intestinal lavage with tube	30
2015	M	8	Distal ileus	spontaneous	Resection segmental	18
2014	M	71	Jejunum	hepaticojejunostomy	Laparoscopy and enterotomy	1
2014	F	34	Jejuno-jejunostomy	Gastric bypass	Laparoscopy and enterotomy	7
2012	M	68	Proximal duodenum	Ulcer by stress	Laparoscopy and enterotomy	31
2009	E	38	Jejuno-jejunostomy	Gastric bypass	Laparoscopy and enterotomy	15
2005	F	35	Jejuno-jejunostomy	Gastric bypass	Laparoscopy and enterotomy	17
1998	M	54	Jejuno-jejunostomy	Gastrectomy total	Laparoscopy and enterotomy	32

**Table 1:** Causes of intraluminal clots.

## Source

Own elaboration. In general, an intramural hematoma is spontaneously reabsorbed in 14 to 90 days [26]. So surgical intervention is rarely necessary; therefore, the treatment for intramural hematoma is non-surgical [27]. Because most of these hematomas resolve spontaneously, surgical management is rare [28]. On the contrary, the recommended treatment for a postoperative intraluminal clot intestinal obstruction is done, [29,30]. Either by suctioning or removing the clot by laparoscopy by opening the cavity, or by endoscopy. However, the most widely used surgical method for evacuation of hematomas is laparoscopic or open drainage [31]. Laparoscopic emergency reoperation with enterotomy is the most recommended to avoid greater morbidity or mortality [9].

## Conclusion

Intestinal obstruction due to intraluminal clots is a very rare complication of Roux-Y hepaticojejunostomy. However,

it is important for the doctor to be aware of this postoperative complication, since a timely diagnosis is needed based on symptoms such as hematemesis and severe crampy abdominal pain. With this, the diagnosis must be confirmed with an abdominal tomography to be taken to surgery for enterotomy with correction of the anastomosis, if necessary.

## References

1. Shah MM, Rather AA, Khan FA (2014) Acute Bowel Obstruction after Hepaticojejunostomy Caused by Blood Clots. Journal of the society of laparoendoscopic surgeon. 30:1-4.
2. Ohi R, Yaoita S, Kamiyama T, Ibrahim M, Hayashi Y, et al. (1990) Surgical treatment of congenital dilatation of the bile duct with special reference to late complications after total excisional operation. J Pediatr Surg. 25: 613-617.
3. Yamataka A, Ohshiro K, Okada Y, Fujiwara T, Kohno S, et al. (1997) Complications after cyst excision with hepaticocenterostomy for choledochal cysts and their surgical management in children versus adults. J Pediatr Surg. 32: 1097-1102.

4. Lewis CE, Jensen C, Tejjarian T, Dutson E, Mehran A (2009) Early jejunojejunostomy obstruction after laparoscopic gastric bypass: case series and treatment algorithm. *Surg Obes Relat Dis*. 5: 203-207.
5. Koppman JS, Li C, GandsasA (2008) Small bowel obstruction after laparoscopic Roux-En-Y gastric bypass: a review of 9,527 patients. *J Am Coll Surg*. 206: 571-584.
6. Pazouki A, Pakaneh M, Khalaj A, Tamannaie Z, Jangjoo A, et al. (2014) Blood bezoar causing obstruction after laparoscopic Roux-en-Y gastric bypass. *Int J Surg Case Rep*. 183-185.
7. Abbas MA, Collins JM, Olden KW (2002) Spontaneous intra-mural small-bowel hematoma: clinical presentation and long-term outcome. *Arch Surg*. 137: 306-310.
8. Soricelli E, Facchiano E, Quartararo G, Beltrame B, Leuratti L, et al. (2017) Large Hemobezoar Causing Acute Small Bowel Obstruction After Roux-en-Y Gastric Bypass: Laparoscopic Management. *Obes Surg*. 27: 1906-1907.
9. Felsher J, Brodsky J, Brody F (2003) Small bowel obstruction after laparoscopic Roux-en-Y gastric bypass. *Surgery*. 134: 501-505.
10. McLaughlan J (1838) Fatal false aneurysmal tumor occupying nearly the whole of the duodenum. *Lancet* 2. 1838: 30.
11. Homma Y, Mori K, Ohnishi Y, Fujioka K, Terada T, et al. (2016) Ultrasound follow-up in a patient with intestinal obstruction due to post-traumatic intramural duodenal hematoma. *J Med Ultrason*. 43: 431-434.
12. Chang C-W, Chen M-J, Shih S-C, Wang H-Y, Tsai C-H, et al. (2010) Delayed duodenal intramural hematoma with obstruction. *Am J Surg*. 199: 77-78.
13. Green J, Ikuine T, Hacker S, Urrego H, Tuggle K (2016) Acute small bowel obstruction due to a large intraluminal blood clot after laparoscopic Roux-en-Y gastric bypass. *J Surg Case Reports*. 8: 143.
14. Peeters G, Gys T, Lafullarde T (2009) Small Bowel Obstruction after Laparoscopic Roux-en-Y Gastric Bypass Caused by an Intraluminal Blood Clot. *Obes Surg*. 19: 521-523.
15. Helling TS, Balliro JM, Nguyen NT, Longoria M, Wilson SE (2005) The lethality of obstructing hematoma at the jejunojejunostomy following Roux-en-Y gastric bypass. *Obes Surg*. 15: 290-293.
16. Awais O, Raftopoulos I, Luketich JD, Courcoulas A (2005) Acute, complete proximal small bowel obstruction after laparoscopic gastric bypass due to intraluminal blood clot formation. *Surg Obes Relat Dis*. 1: 418- 422.
17. Lim YJ, Nam SH, Kim SJ (2015) Large intraluminal ileal hematoma presenting as small bowel obstruction in a child. *Iran J Radiol*. 12: 8212.
18. Delibegovic M, Alispahic A, Gazija J, Mehmedovic Z, Mehmedovic M (2015) Intramural Haemorrhage and Haematoma as the Cause of Ileus of the Small Intestine in a Haemophiliac. *Med Arch (Sarajevo, Bosnia Herzegovina)*. 69: 206-207.
19. Schroeder RM, Kohler JE, Mak GZ, Kandel JJ (2014) Bowel obstruction from intramural hematoma in two children treated with low molecular weight heparin: Case report and review of the literature. *J Pediatr Surg Case Reports*. 2: 483-485.
20. Zammit A, Marguerat DG, Caruana C (2013) Anticoagulation-induced spontaneous intramural small bowel haematomas. *BMJ Case Rep*.
21. Brar P, Singh I, Kaur S, Doley RP, Brar R, Sahni A, et al. (2011) Anticoagulant-induced intramural hematoma of the jejunum. *Clin J Gastroenterol*. 4: 387-390.
22. Veldt BJ, Haringsma J, Florijn KW, Kuipers EJ (2011) Coumarin-induced intramural hematoma of the duodenum: case report and review of the literature. *Scand J Gastroenterol*. 46: 376-379.
23. Altıkaya N, Parlakgümüş A, Demir Ş, Alkan Ö, Yıldırım T (2011) Small bowel obstruction caused by intramural hematoma secondary to warfarin therapy: a report of two cases. *Turk J Gastroenterol*. 22: 199-202.
24. Grasshof C, Wolf A, Neuwirth F, Posovszky C (2012) Intramural duodenal haematoma after endoscopic biopsy: case report and review of the literature. *Case Rep Gastroenterol*. 6: 5-14.
25. Wassner JD, Yohai E, Heimlich HJ (1977) Complications associated with the use of gastrointestinal stapling devices. *Surgery*. 82: 395-399.
26. Birns MT, Katon RM, Keller F (1979) Intramural hematoma of the small intestine presenting with major upper gastrointestinal hemorrhage. *Gastroenterology*. 77: 1094-1100.
27. Eiland M, Han SY, Hicks GM (1978) Intramural hemorrhage of the small intestine. *JAMA* 239: 139-142.
28. Shimizu H, Maia M, Kroh M, Schauer PR, Brethauer SA (2013) Surgical management of early small bowel obstruction after laparoscopic Roux-en-Y gastric bypass. *Surg Obes Relat Dis*. 718-724.
29. Ruiz-Tovar J (2017) Hemobezoar causing intestinal obstruction at the foot of loop during the postoperative period of a Roux-en-Y Gastric Bypass. *BMI | Ibero-American Metabolic Bariatric*. 7: 1859-1961.
30. Mizumura N, Imagawa A, Kawasaki M, Okumura S, Toyoda S, et al. (2015) Small Bowel Obstruction Caused by Blood Clots: A Rare Complication of Peptic Ulcer. *J Med Cases*. 6: 477- 479.
31. Siddiky A, Gupta P (2012) Proximal small bowel obstruction caused by a massive intraluminal thrombus from a stress ulcer. *J Surg case reports*. 1: 6.
32. Onda M, Urazumi K, Abe R, Matsuo K (1998) Obstructive Ileus caused by blood clot after emergency total gastrectomy in a patient with hemophilia A: report of a case. *Surg Today*. 28: 1266-1269.