

## Research Article

# Hemiarthroplasty (HA) with a Two-Step Osteotomy in Unstable Intertrochanteric Osteoporotic Fractures of Senile Patients (A Report of 65 Cases)

Guishan Gu<sup>1</sup> and Yinghua Li<sup>2</sup>

<sup>1</sup>Department of Bone and Joint, First Hospital of Jilin University, Changchun 130021, China

<sup>2</sup>Department of Nuclear Medicine, First Hospital of Jilin University, Changchun 130021, China

**\*Corresponding author:** Guishan GU, Department of Bone and Joint, First Hospital of Jilin University, Changchun 130021, China, Tel: 86-431-88782457; Email: guguishan@sina.com

**Citation:** Gu G, Li Y (2016) Hemiarthroplasty (HA) with a two-step osteotomy in Unstable intertrochanteric Osteoporotic Fractures of Senile patients (A report of 65 cases). Emerg Med Inves 2016: 119. DOI: 10.29011/2475-5605.000019

**Received Date:** 10 November, 2016; **Accepted Date:** 12 December, 2016; **Published Date:** 17 December, 2016

### Abstract

**Background:** Although Hemi Arthroplasty (HA) remains controversial, it has been the supplement in the treatment of unstable intertrochanteric osteoporotic fractures in senile patients. A newly designed two-step osteotomy with hemiarthroplasty was introduced in this study.

**Methods:** Sixty five consecutive patients (aged from 75 to 92 years with a mean of 81 years old) with unstable intertrochanteric fractures including 21 male cases (21 hips) and 44 female cases (44 hips) were treated in our hospital from August 2006 to October 2015 (Evans type III in 20 cases, Evans type □ in 45 cases) with a newly designed two-step osteotomy technique with bipolar hemiarthroplasty by a senior orthopedic surgeon through posterior approach under general anesthesia. All cases were evaluated by Zuckerman functional recovery score (FRS) [1] and operative risk assessment software 1 (ORAS1), based on the Possum and P-Possum score system [2]. The duration and blood loss have been recorded. All prostheses consisted of Link SP II femoral stem and bipolar femoral head and were followed up for more than 1 year.

**Results:** The average pre-injured FRS, predictive value of operative morbidity and mortality were 82.7 (81.6—84.9), 9.2% (7.1%—14.9%) and 3.4% (2.1%—4.3%), respectively. The average operation time was 50 minutes with a mean intra operative blood loss of 310 ml. There were no operative or anesthetic complications or deaths within 30 days after operation. Sitting up was permitted 3 to 4 days, and partial weight bearing was allowed 5 to 7 days after operation. The average FRS was 78.3 at 30 days and 83.9 at 1 year postoperatively. Eleven patients died of unrelated causes (Five due to myocardial infarction and the others due to cerebral hemorrhage during at least one-year follow-up) (table 1).

**Conclusion:** Bipolar hemiarthroplasty with a two-step osteotomy technique for unstable intertrochanteric fractures in the senile patients is a good choice for early ambulation and good hip function. Internal fixation (IF), especially with intramedullary nail, has been the gold standard in the treatment of unstable intertrochanteric osteoporotic fractures in senile patients. However, high internal fixation failure rate because of severe osteoporosis, coxa vara, displaced greater and lesser trochanters, makes orthopedic surgeon puzzled in the decision making. Although it remains controversial, hemiarthroplasty (HA) has been the supplement in the treatment, because bipolar hemiarthroplasty can not only achieve early mobilization but also get good hip function. But because of difficult anatomical reduction, poor bone quality, local complicated anatomical structure and many comorbidities, The surgical technique remains challenging to orthopedic surgeon. The purpose of this study was to introduce bipolar hemiarthroplasty with a newly-designed two-step osteotomy technique and observe its clinical result for unstable intertrochanteric fractures in senile patients.

**Keywords:** Hemiarthroplasty, Osteoporosis, Intertrochanteric Fracture

## Methods

### Patients

Sixty five consecutive patients with unstable intertrochanteric fractures aged from 75 to 92 years with a mean of 81 years were treated in our hospital from August 2006 to October 2015 (Evans type III in 20 cases, Evans type □ in 45 cases). Who received bipolar hemiarthroplasty with a newly-designed two-step osteotomy technique performed by a senior orthopedic surgeon through posterior approach under general anesthesia. All cases were evaluated by Zuckerman functional recovery score (FRS) [1] and operative risk assessment software 1 (ORAS1), based on the Possum and P-Possum score system [2]. The duration and blood loss have been recorded. There were 21 male cases(21 hips)and 44 female cases(44 hips). All prostheses consisted of Link SP II (Waldemar Link GmbH & Co, KG, Barkhausenweg 10, 22339 Hamburg, Germany) femoral stem and bipolar femoral head. All patients were followed up for more than 1 year (table 1).

Gender	M(21 cases), F(44cases)
Age	M (84 yrs old), F(73 yrs old), average 81 years old
Diagnosis	Intertrochanteric fractures
Evans	Type III(20cases), IV(45cases)
Comorbidities	Hypertension48 M(31cases), F (11cases)
	Hyperlipemia61 M(55cases), F(6cases)
	Diabetes mellitus38M(32cases), F(6cases)
	Urinary tract infection37 (M 37cases)
Operative morbidity and mortality	9.2%3.4%
Anesthesia	general anesthesia
Approach	Posterior approach
Prosthesis	Link SP II (WaldemarLink GmbH & Co, KG, Barkhausenweg 10, 22339 Hamburg, Germany)
FRS	Pre-injured 82.7 post-operation 78.3( at 30 days) and 83.9 (at 1 year )
Complications	Death 11(5 due to myocardial infarction and 6 due to cerebral hemorrhage).
	Infection none
	Dislocation none

**Table 1:** Clinical data on intertrochanteric fracture with bipolar hemiarthroplasty.

### Surgical technique

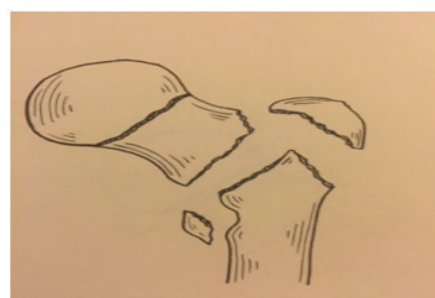
Patients under general anesthesia were operated by a senior orthopedic surgeon via a posterior approach in lateral position with

a buttress between two legs. Prophylactic intravenous antibiotics (2g of cefazolin) were administered preoperatively. Preoperative planning including assessment of fracture, determination of rotation center, identification of femur length and preparation for prosthesis template should be done carefully. The bipolar hemiarthroplasty with a two-step osteotomy was done in four stages:

- (1) Exposure
- (2) Two-step Osteotomy
- (3) Intramedullary preparation of femur
- (4) Insertion of Link SP II bipolar prosthesis, reduction and closure.

### Exposure

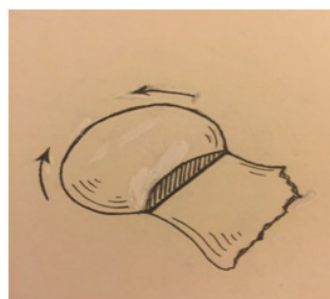via posterior approach. iliotibial band was incised and the fibers of the gluteus maximus were separated, followed by division of the piriformis tendon, conjoined tendon of the obturator internus and the gemelli as well as exposure to posterior joint capsule. T-type incision of capsule was made with the long part of T going along the axis of femoral neck (Figure 1 A)



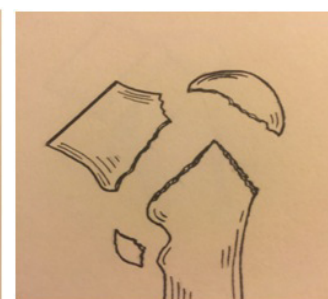**Figure 1A:** Type VI intertrochanteric fracture.

### Two-step Osteotomy

The first step of osteotomy should be taken vertically to the neck at the sub-capital level when the hip was slightly rotated internally after retracting the capsule above and below the femoral neck with two Hoffman hooks (Figure 1 B). Four main fragments including the greater and lesser trochanters. Femoral shaft and the retained portion of the neck will be left after removal of the femoral head (Figures 1C and 1D).

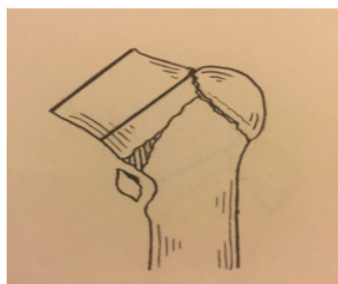


**Figure 1C:** Retraction of two parts for removal of femoral head.

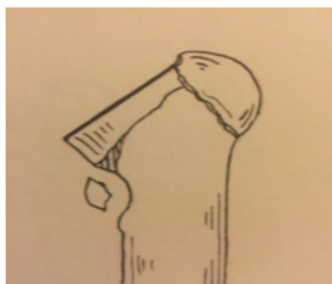

**Figure 1D:** Postosteotomy picture.

The second step of osteotomy should be taken vertically to the neck roughly about 1 to 2 cm or a little higher above lesser trochanter. Which can be determined by either greater or lesser trochanter after their reduction and external inferior compression of the retained portion of the neck during the traction of the leg (Figures 1E and 1F). The reductive greater and lesser trochanters were immobilized with coated vicryl plus antibacterial suture or Ethibond suture. The proximal femur recovered to anatomical structure roughly, which is always used as a marker for determination of the leg length.



**Figure 1E:** Reduction of fracture and determination of second line of osteotomy.



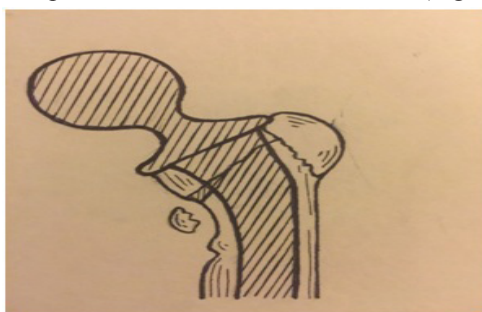**Figure 1F:** Second step of Osteotomy.

### Intra medullary preparation of femur

The femoral canal was broached with appropriate ante version mainly based on inter condylar line of distal femur. After the retained portion of the neck and femur were fixed with fracture fixing apparatus. A bipolar prosthesis trial was then inserted and reduction was done. Ante version of femoral head, size of prosthesis, length of leg should be decided based on either comparing with the opposite leg or the greater or lesser trochanter.

### Insertion of Link SP II bipolar prosthesis, reduction and closure

The second-generation cementing technique and cement restrictor were used in all cases. Check the ante version, leg length by above mentioned methods again during the final fixation of the stem. Traction and reduction were made, the capsule, tendon of the piriformis, conjoint tendon of the obturator internus as well as gemelli were repaired and the incision was closed (Figure 1G).

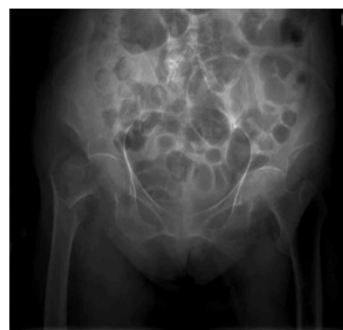

**Figure 1 G:** Insertion of prosthesis.

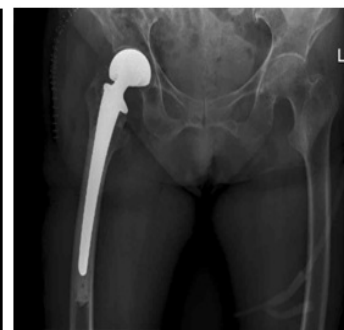All patients underwent a routine postoperative physiotherapy protocol that included early partial weight bearing with a walker 5 to 7 days after surgery. Rehabilitation then progressed as tolerated by the patients. Patients were examined postoperatively at 4 weeks, 6 weeks, 3 months, 6 months, 1 year and thereafter annually. At each follow-up visit, a clinic-radiological examination was done and the patient was evaluated using FRS. Antero posterior radiographs of the hip were analyzed at each follow-up to note evidence of loosening.

## Results

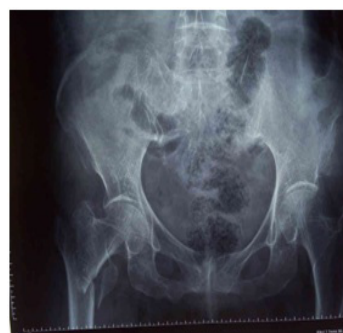The average pre-injured FRS, predictive value of operative morbidity and mortality were 82.7(81.6—84.9), 9.2%(7.1%--14.9%) and 3.4%(2.1%--4.3%), respectively. The average operation time was 45 minutes with a mean intra operative blood loss of 300 ml. There were no operative or anesthetic complications or deaths within 30 days after operation. Sitting up was permitted 3 to 4 days, and partial weight bearing was allowed 5 to 7 days after operation. The average FRS was 78.3 at 30 days and 83.9 at 1 year postoperatively. Eleven patients died of unrelated causes (Five due to myocardial infarction and the others due to cerebral hemorrhage) during at least one-year follow-up (Figures 2A, 2B; 3A, 3B ) (Table 1).



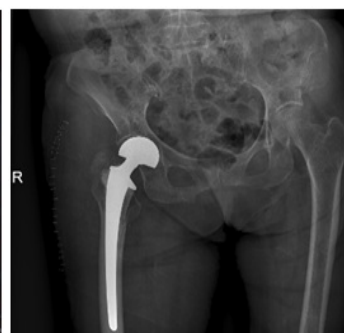**Figure 2A:** An 81-year-old female with intertrochanteric fracture (Evans VI) preoperative X-ray).



**Figure 2B:** An 81-year-old female with intertrochanteric fracture (Evans VI) postoperative X-ray).



**Figure 3A:** An 86-year-old female with intertrochanteric fracture (Evans VI) preoperative X-ray).



**Figure 3B:** An 86-year-old female with intertrochanteric fracture (Evans VI) postoperative X-ray).



## Discussion

Bipolar hemiarthroplasty for unstable intertrochanteric fracture has well been accepted after its initial use as a salvage procedure for failed pinning since 1971. Tronzo [3], Rosenfeld et al [4] reported good results with both long and straight-stemmed Leinbach prosthesis. Since then many surgeons concluded that bipolar hemiarthroplasty is an effective way to treat the unstable intertrochanteric fracture in the senile patients. It can decrease complications, reduce mortality, improve the patient's life quality, and reduce family burden (3-7).

However, reconstruction of proximal femur which the surgeons must face during the operation puzzled them for a long time. The severe comminuted greater trochanter, separated lesser trochanter, sacrificed calcar and coxa vara make it rather difficult to determine the leg length and ante version of femoral head during the operation which may lead to more hemorrhage, longer operative time and more complications. While hemiarthroplasty with a two-step osteotomy may solve the problem due to its quick reconstruction of proximal end of femur, short operative time and less hemorrhage.

The key rationale of the two-step osteotomy focuses on recovery of leg length and the ante version of femoral head without strict concern about anatomical reconstruction of the proximal femur and rigid fixation moreover bone healing.

The first step of osteotomy, a line vertically to the neck at the sub-capital level, can not only remove the femoral head but also keep the femoral neck in situ (Figures 1B, 1C, 1D) which makes fragments prone to reduction without any further separation. The soft tissues around the proximal femur such as bone membrane, ligaments (ilio-femoral, pubo-femoral, ischi-femoral ligaments), partial capsule sometimes remains intact. All these structures can help the reduction of greater and lesser trochanter during the operation. The osteotomy line should as high as possible for the purpose of remaining the femoral neck as much as possible. Abduction and external inferior compression during the traction of the leg may make the retained portion of the neck sink into the upper part of femur which means much more bone can be kept during the operation, therefore bone union can achieve here easily. Moreover much less hemorrhage than previous method [8] can achieve because of no further separation of surrounding tissues. The rough reduction (both greater and lesser trochanters) after immobilization with coated vicryl and antibacterial suture or Ethibond can be used as a marker for determination of the leg length and make it easily to decide the line of the second step (Figures 1E,1F). Pay much attention to keep the femoral neck in its reduced place during the

preparation of femoral canal. All 65 cases underwent hemiarthroplasty by this two-step osteotomy technique, which may be easily performed in the case of Evans type III intertrochanteric fractures due to part of the lesser trochanter remaining intact, however difficultly performed in the cases of Evans type IV fractures because of free greater and lesser trochanter. All these cases have good functional reconstruction of proximal femur (preoperative FRS vs postoperative FRS,  $P < 0.01$ ) after operation, (Figures 2A, 2B; 3A, 3B) during which the capsule, tendon of piriformis, conjoined tendon of the obturator internus and gemelli had been repaired either to its original site, gluteus medius muscle, or posterior lateral edge of proximal femur. No dislocation or infection occurred during 30 days up to one-year follow-up. But eleven patients died of unrelated causes (Five due to myocardial infarction and the others due to cerebral hemorrhage) during at least one-year follow-up. Short duration due to this two-step osteotomy technique can lead to less hemorrhage, shorter anesthetic time that can decrease patients' length of stay in the operating room, less complications therefore can be achieved,

In conclusion, hemiarthroplasty with a two-step osteotomy technique can not only recover the function, relieve pain, but also decrease the complications after operation because of its quick reconstruction of proximal femur, short operative time, less blood loss and early weight bearing.

## References

1. Zuckerman JD, Koval KJ, Aharonoff GB (2000) A functional recovery score for elderly hip fracture patients: II. Validity and reliability. *J Orthop Trauma* 14: 20-25.
2. Bonicoli E, Parchi P, Piolanti N, Andreani L, Niccolai F, et al. (2014) Comparison of the POSSUM score and P-POSSUM score in patients with femoral neck fracture. *Musculoskelet Surg* 98: 201-204.
3. Tronzo RG (1974) The use of an endo-prosthesis for severely comminuted trochanteric fractures. *Orthop Clin North Am* 5: 679-681.
4. Rosenfeld RT, Schwartz DR, Alter AH (1973) Prosthetic replacement for trochanteric fractures of the femur. *J Bone Joint Surg Am* 55: 420.
5. Stern MB and Goldstein TB (1977) The use of the Leinbach prosthesis in intertrochanteric fractures of the hip. *Clin Orthop Relat Res* 128: 325-331.
6. Stern MB and Angerman A (1987) Comminuted intertrochanteric fractures treated with Leinbach prosthesis. *Clin Orthop Res*: 75-80.
7. Parker MJ and Handoll HH (2006) Replacement arthroplasty versus internal fixation for extracapsular hip fractures in adults. *Cochrane Database Syst Rev* 19: CD000086.
8. Gu GS, Wang G, Sun DH, Qin D, Zhanget W (2008) Cemented bipolar hemiarthroplasty with a novel cerclage technique for unstable intertrochanteric hip fractures in senile patients. *Chin J Traumatol* 11: 13-17.