

First Case of Pulmonary Lophomoniasis in Mexico

José Antonio de Diego Cabrera^{1*}, Ma. Elena Villagrán Herrera², Ricardo F. Mercado-Curiel², Hebert Luis Hernández-Montiel², José Martínez-Ibarra³

¹Department of Preventive Medicine, Autonomous University of Madrid, Spain

²Department of Biomedical Research, Autonomous University of Querétaro, México

³Laboratory of Medical Entomology, University of Guadalajara, México.

***Corresponding author:** José Antonio de Diego Cabrera, Department of Preventive Medicine, Autonomous University of Madrid, Spain. Tel: +34 914975350; Email: antonio.diego@uam.es

Citation: De Diego-Cabrera JA, Villagrán-Herrera ME, Mercado-Curiel RF, Hernández-Montiel HL, Martínez-Ibarra JA (2017) First Case of Pulmonary Lophomoniasis in Mexico. J Trop Med Health JTMH-104. DOI: 10.29011/JTMH-104.000003

Received Date: 23 November, 2017; **Accepted Date:** 18 December, 2017; **Published Date:** 27 December, 2017

Summary

Infection in humans by the intestinal protozoan of cockroaches and finish called *Lophomonas blattarum*, diagnosed in respiratory infections of children 2 to 5 years polluted by road or by air orally, with cysts or trophozoites contents in feces of the cockroach *Periplaneta americana*. Respiratory Infections in adult's diagnosis is difficult do that is no longer recognized as a human pathogen and are only related in immunocompromised patients, transplant patients with pulmonary disease and those living in poor and unhealthy sanitary conditions. Normally, your presence is manifested by fever of 38°C to 39°C, cough with thick sputum, respiratory failure and lung abscesses. Laboratory diagnosis is based on bronchoscopic biopsies and pap smears bronchoalveolar lavage. In our case was possible to visualize the protozoan, is prepared fresh bronchial aspirates, wet assembly with saline and stained with pap smear, Harris hematoxylin and eosin, Giemsa and PAS-Blue-alciano (peroxidase), which take compare paragraph staining techniques and microscopic observation.

Keywords: Endocommensal; Eosin-PAS-Alcian Blue (peroxidase); Harris hematoxylin; Multiflagellated protozoan: *Periplaneta americana*; Wet Mount

Introduction

The bronchopulmonary lophomoniasis is a condition caused by eating or accidentally suck cysts or trophozoites of protozoan intestinal anaerobic multiflagelado, *Lophomonas blattarum* (Parabasalid: Hypermastigia, Cristomonadida, Lophomonadidae). This parasite has been characterized as an endocommensal in the gut of some arthropods, like termites and cockroaches (Dyctioptera: Blattoidea), which pollute its path, food, dust and clothes with their secretions and feces [1]. Cockroaches (Figure 1).



Figure 1. intradomiciliary Cockroach (*Periplaneta americana*).

Are strong perfectly recognized pests closed, dark places, which abound at the beginning of hot weather and become visible

at night when leaving their natural habitat (sewers and drains) to look for food in the periphery and / or inside of the houses room [2]. They are usually carriers of microorganisms (fungi and intestinal parasites) and have been seen mainly in kindergartens, schools or hospitals. To date have identified several groups of intestinal parasites carried by your digestive tract, some health interest as *Blastocystis spp* and others own the same vector (nematode *Thelastoma spp*), and protozoans poliflagelados as *Lophomonas blattarum* [3].

Lophomonas blattarum, main vector protozoan parasite commensal intestinal tract normally located on arthropod. Photo. Villagrán Herrera 2017.

Research conducted in dissected, large and small intestines of 110 copies of American Periplaneta (cockroach pipe) in the city of Wuhan showed in preparations stained with Giemsa and views 1000X, ovals, boules, 20 to 40 microns, with some lock flagella extended down the central axis of the parasite and one end trumpet shaped enveloping the sole core shown. Also, it showed a further small axostilo terminal to multiflagellar part. Based on the above morphological characteristics, the parasite was identified as *L. blattarum*. Of the 110 cockroaches, 44 were positive for *Lophomonas blattarum* (44%) [4]. *Lophomonas* gender, since 1990, has been considered among the protozoa that cause damage to the respiratory tract, especially in immunocompromised individuals (HIV / AIDS, with neoplasias, use of corticosteroids and transplant patients) and in adult and pediatric asthmatic individuals [5-8]. Signs and symptoms of infection are similar to *Lophomonas* bronchitis or pneumonia and bronchopulmonary pathologies of various etiologies, so it is difficult to correct diagnosis. This forces us to properly address the microbiological study of sputum samples, brushings, biopsy or washed broncho-alveolar, either fresh or stained, especially when observing multiflageladas forms preparations, because if you do not have enough experience can be confused trophozoites of *Lophomonas blattarum* with fragments of ciliated epithelial cells (ciliocitoria) of the bronchi [9,10].

It is important to note that conventional techniques such as Gram stain, Giemsa, Papanicolao not allow adequate visualization of multiflagelado. Thus, it is necessary that suspicion, first a wet mount is made with saline in all respiratory tract samples reach the laboratory for parasitological diagnosis, and subsequently extended perfectly smear stained with special stains such as Masson [11]. The most important species are clinically *Lophomonas blattarum* and *Lophomonas striata*. *L. striata* species was first identified in the gut of the cockroach *Blatta orientalis* by Stein in 1860 [1]. *L. blattarum* structure was identified in the light microscope in 1911 and in 1990 with an electron microscope and scanning.

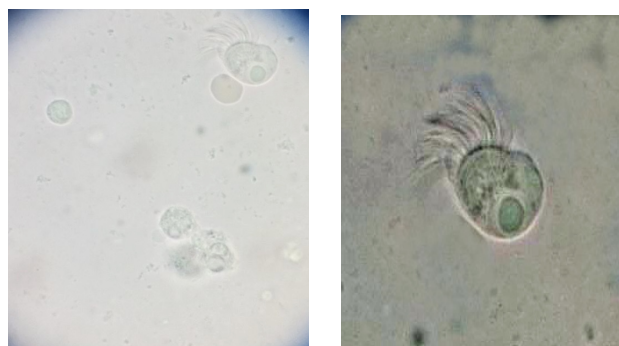
The shape of trophozoite *Lophomonas* usually round, oval or pear-shaped, a size range between 15 to 50 microns in diameter, with a tuft of flagella forming a bunch located at the front end, being larger, those found far apical cleft. Phagocytic vacuoles containing

in their cytoplasm, with rhythmical movements outward directed to the apical end in order to eliminate or excretions trap foreign materials [1].

Case Presentation

Male of 50 years old, doctor native of Pachuca Hidalgo, who lives in the municipality of Cadereyta for 18 years. He denies travel abroad without physical activity, indicates proper grooming. Refers 9 years ago diagnosis of non-Hodgkin lymphoma, treated with radiotherapy and chemotherapy. For post-treatment edema, it was performed thoracentesis and pericardiocentesis and gastrostomy, which he held for one year. 6 months ago, presented respiratory symptoms, characterized by fever, malaise, coughing, mild respiratory failure data, it is given antibiotic therapy is administered salbutamol and after 15 days this remission. 1 month ago presents respiratory symptoms with the same characteristics, refers to chest radiography was performed with data unspecified pneumonia. It presents 6 days ago fatigue, weakness, hyporexia, malaise, fever of 38.5°, self-medicate levofloxacin 750 mg every 12 hours, ceftriaxone 1 g every 24 hours, paracetamol and metamizol 500 mg orally three days later added cough, sputum streaked with blood, then it becomes a uniform red color, likewise the cough persists and increases the amount of phlegm. It has mild dyspnea, without predominance of schedule, salbutamol self-medicates, showing improvement with the drug application.

Currently the fever persists, malaise and mild headache concerns. You are prompted for newly issued Spitting samples and will conduct studies on fresh saline and various smears, which are stained with hematoxylin and eosin, Pap smear, PAS-Alcian Blue- and Giemsa. The study reveals fresh trophozoites and cysts of a multiflagellated protozoan identified as *Lophomonas blattarum* (Figures 2a and 2b).



Figures 2a and 2b. wet mount with saline, which are observed trophozoites and cysts *Lophomonas blattarum*. X400. Photos: Villagrán Herrera 2017.

In smears before dye them lot of polymorphonuclear leukocytes are observed coincident with an acute inflammatory process. (Figure 3).

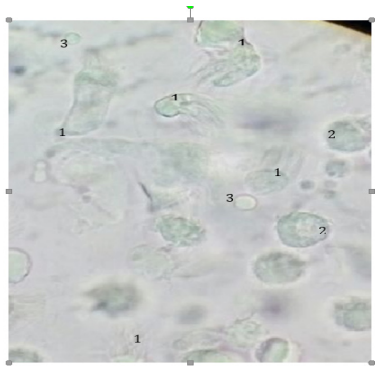


Figure 3: Mounting wet with saline. multiflagellated trophozoites (1) and cysts (2) in a sample of undyed morning expectoration observed. the vacuole and the many scourges in its narrowest seen in some ways. These features are supported by *Lophomonas blattarum*. erythrocytes (3) show a process of bleeding throat appreciated. X400. Photo: Villagrán Herrera 2017.

Following identification multiflagellated protozoan is started treatment with Metronidazole 500 mg every 8 hours orally for 7 days, improving symptoms, decreasing dyspnea, following nonproductive cough.

Discussion

In the cases reported in Peru, China and Spain (Table 1).

Autor(s) y años	Caso(s) registrados	País
Chen & Meng (1993)	1	China
Dong et al. (2000)	1	China
He et al. (2011)	2	China
Kang et al. (2008)	1	China
Liu et al. (2009)	1	China
Liu et al. (2007)	1	China
Martínez Girón et al. (2007)	1	España
Martínez Girón & Doganci (2010)	1	España
Miao et al. (2008)	1	China
Shi et al. (2007)	1	China
Wang (2012)	26	China
Wang et al. (2006)	1	China
Yang et al. (2000)	1	China
Yao (2008)	1	China
Yao et al. (2009)	1	China
Yao et al. (2008)	1	China
Yao et al. (2008)	1	China
Yao et al. (2008)	1	China
Yao et al. (1999)	1	China
Zerpa et al. (2010)	6	Perú
Zhang, F. et al. (2010)	6	China
Zhang, R. S. et al. (2010)	1	China
Zhang et al. (2011)	1	China
Zhou et al. (2006)	1	China

Fariba Berenji et al. (2015)	1	Irán
Total	61	

Table 1. Reported cases of bronchopulmonary diseases *Lophomonas blattarum*. [6].

where found this protozoan in sputum samples must be added, one reported case of sinusitis in Iran [12] whose common denominator, deficiencies in the immune system, the It makes extremely sensitive to any milder infection by it. It also indicates a possible airborne transmission, influenced by a moist environment through waste and environmental dust and aspiration, trophozoites or cysts of the protozoan stay in the lung epithelium develop infection with similar manifestations to any pathology pulmonary bacterial, fungal and even parasitic, further hindering its accurate diagnosis.

Our patient developed respiratory symptoms pointing possible miliary tuberculosis or pathology of acute airways, since in the expectorant product threads blood were observed in some of the emissions, so without wet study with saline, differential diagnosis not It would have been possible to achieve. The immunocompromised patient was a crucial and decisive factor for infection to develop, like self-medication and the lack of an accurate diagnosis were important factors for complete recovery is delayed.

Conclusions

This particular case was the first diagnosed in Mexico, and illustrates casual *L. blattarum* infection, a rare opportunistic pathogen, probably acquired by the patient airway developing lung infection, due to its immuno-compromised immune status. It is essential that physicians consider *Lophomonas blattarum* in their differential clinical diagnosis. Since some dust mites are vectors similar flagellates, whose respiratory allergy manifestations are presented in a similar manner and lack of an accurate diagnosis, chronic allergies become unresponsive to treatment administered.

Conflict of interests

The authors declare that no conflict of interest in connection with the publication of this case.

Acknowledgments

It is important to mention the support of the H. T. Evelyn Hernandez Flores, for his collaboration in staining smears of the sputum sample.

References

1. Gile GH, Slamovits CH (2012) Phylogenetic position of *Lophomonas striata* Butschli (Parabasalia) from the hindgut of cockroach *Pireplaneta Americana*. Protist 163: 274-83.

2. Ewel, John J, Madriz, Arnoldo Tosi, Joseph A (1976) Zonas de Vida de Venezuela. Memoria explicativa sobre el mapa ecológico. 2a edición. Editorial Sucre, Caracas, Venezuela 56-67.
3. Dalmiro Cazorla-Perfetti, Pedro Morales Moreno, Patricia Navas Yamarte (2015) IDENTIFICATION OF *Lophomonas blattarum* (HYPERMASTIGIA: CRISTOMONADIDA, LOPHOMONADIDAE), CAUSAL AGENT OF BRONCHOPULMONARY LOPHOMONIASIS, IN SYNANTHROPIC COCKROACHS FROM THE CORO UNIVERSITY HOSPITAL, FALCON STATE, VENEZUELA. Saber, Universidad de Oriente, Venezuela. 27: 511-514.
4. Yang JX, Tang YY, Fang ZM, Tong ZZ, Li YL, et al. (2014) Investigation on *Lophomonas blattarum* infection in *Periplaneta americana* in Wuhan City. Zhongguo Ji Sheng Chong Xue Yu Ji Sheng Chong Bing Za Zhi 32: 161-162.
5. Zerpa R, Ore E, Patiño L, Espinoza YA (2010) Hallazgo de *Lophomonas* sp. en secreciones del tracto respiratorio de niños hospitalizados con enfermedad pulmonar grave. Rev. Perú. Med. Exp. Salud Pública 27: 575-577.
6. Martínez-Girón R, Van Woerden HC (2013) Clinical and immunological characteristics associated with the presence of protozoa in sputum smears. Diagn Cytopathol 41: 22-27.
7. Martínez-Girón R, Van Woerden HC (2014) Bronchopulmonary lophomoniasis: emerging disease or unsubstantiated legend?. Parasit. Vectors 7: 284.
8. Xue J, Li Y, Yu X, Li D, Liu M, et al. (2014) Bronchopulmonary Infection of *Lophomonas blattarum*: a case and literature review. Korean J. Parasitol 52: 521-525.
9. Mu XL, Shang Y, Zheng SY, Zhou B, Yu B, et al. (2013) A study on the differential diagnosis of ciliated epithelial cells from *Lophomonas blattarum* in bronchoalveolar lavage fluid. Zhonghua Jie He He Hu Xi Za Zhi 36: 646-650.
10. Martínez-Girón R, van Woerden HC (2013) *Lophomonas blattarum* and bronchopulmonary disease. Journal of Medical Microbiology 62: 1641-1648.
11. Martínez-Girón R, Van Woerden HC, Doganci L (2011) *Lophomonas* misidentification in bronchoalveolar lavages. Intern Med 50: 2721-2723.
12. Fariba Berenji, Mahmoud Parian, Abdolmajid Fata, Mahdi Bakhshaei, Fereshte Fattahi (2016) First Case Report of Sinusitis with *Lophomonas blattarum* from Irán. Case Reports in Infectious Diseases 16: 2.