

Dorsal Tackling for Fractures on the Base of the First Metacarpal: Anatomical Study

Náquira Luis Felipe¹, Ramírez Juan Felipe¹, Arcila Mario², Gómez Miguel¹, Villegas-González Mauricio¹, Victoria Eugenia Restrepo Noriega^{3*}

¹Orthopedist and Traumatologist, Medellín, Colombia.

²Anesthesiologist and Algesiologist, Medellín, Colombia.

³Medicine and Surgery UR, Epidemiologist UNAB, Medellín, Colombia

*Corresponding author: Victoria Eugenia Restrepo Noriega, Medicine and Surgery, Universidad del Rosario, Resident of Epidemiology UNAB, Surgical Assistant for Orthopedics and Traumatology, Clinica el Rosario, Headquarters, Medellín, Colombia

Citation: Felipe NL, Felipe RJ, Mario A, Miguel G, Mauricio VG, et al. (2020) Dorsal Tackling for Fractures on the Base of the First Metacarpal: Anatomical Study. Acad Orthop Res Rheum 4: 130. DOI: 10.29011/2688-9560.100130

Received Date: 27 April, 2019; **Accepted Date:** 08 May, 2019; **Published Date:** 15 May, 2019

Abstract

Introduction: The surgical tackling of intra-articular fractures of the thumb base is made whether by a radiopalmar incision or through a curve incision described by Wegner. However, we seek to describe an exclusively dorsal tackling of the hand between the first and second metacarpal, which allows a better anatomic exposure and a lower index of neurological complications.

Methodology: Dissection of 4 cadaveric specimens, making use of an exclusively dorsal tackling for exposure of the carpometacarpal joint of the first finger of the hand and later photographic recording of findings.

Results: The exclusively dorsal tackling of the hand allowed the identification in all cases of the dorsal sensitive branch of radial nerve, its suitable separation and protection and the exposure of more than 80% of the articular surface of the carpometacarpal joint of the first finger.

Discussion: The exclusively dorsal tackling of the hand for the treatment of intra-articular fractures of the first metacarpal base allows a suitable protection of the sensitive branch of the radial nerve, as well as a better exposure of the fracture and the articular surface, which would allow to decrease the risk of complication in the long run.

Keywords: Bennett; Dorsal; Fracture; Joint; Nerve; Rolando; Wegner

Introduction

The surgical tackling of intra-articular fractures of the thumb base is made whether by a radiopalmar incision or through a curve incision described by Wegner [1]. Our project sought to describe an exclusively dorsal tackling in the hand, between the first and the second metacarpal base, in order to perform the respective anatomic correlation in corpses and in this way corroborate the best articular assessment of the first finger base, the easiness it offers to tackling for surgical management and the decrease in the incidence of nervous injuries of the dorsal sensitive branch of the radial nerve that this tackling offers.

The intra-articular fractures of the first metacarpal base are a challenge for any orthopedist, because a deficient reduction or even a subluxation can result in the patient suffering a functional restriction, chronic pain, weakness and clamp limitation. A reason why a surgical suitable tackling at the time of operating a patient is fundamental not only for the intraoperative development of the surgery, but also for patient's rehabilitation and functionality in the future.

The most common intra-articular fractures of the first metacarpal base are the Bennett Fracture and the Rolando Fracture, each of them with their surgical characteristics and indications [1]. In the case of the Bennett Fracture, described as a fracture in which the metacarpal base axis displaces laterally [2], is managed through close reduction and immobilization techniques; however, in many

occasions the immobilization by a ferule is not sufficient, a reason why it is necessary to use a close fixation with pines, following the Wagner technique [1,3,4]. But in those cases in which the reduction is not satisfactory and an articular incongruence is maintained, it is necessary to use open reduction and fixation through Wagner technique [5], in which a curve incision is made on the dorsal-radial face of the first metacarpal, making the curve toward the wrist fold, and being always very careful with the dorsal sensitive branch of the radial nerve, after the dissection per planes the carpometacarpal joint is cut and the fracture is exposed for its later fixation [3,4,6].

On the other hand, the Rolando fractures are characterized by having an intra-articular stroke in “Y”, generally without any displacement of the metacarpal axis, which makes these fractures more complex at the time of obtaining an anatomic reduction [1,6,7]. Therefore, this kind of fractures generally requires an open management and internal fixation, most of them with the Wagner open surgical tackling, in order to achieve the exposure of the articular surface for allowing tackling [7].

Although many of these fractures allow a suitable management and tackling of the back radial incisions of the hand, the radiopalmar incisions and tackling [8] are also an option at the time of attempting to obtain an anatomic reduction of the fracture, and in this way decrease the risk of arthrosis in the short term.

Methodology

A study was made of basic and surgical sciences anatomic type description, on corpses provided by the Latin American Center of Investigation and Training about Minimal Invasion Surgery in the city of Bogota. A uniform anatomic dissection was carried out on 4 cadaveric specimens, without exclusion of age and sex. Photographic recording was made, and the images were collected following a data protection protocol in order to avoid their reproduction, disclosure or loss.

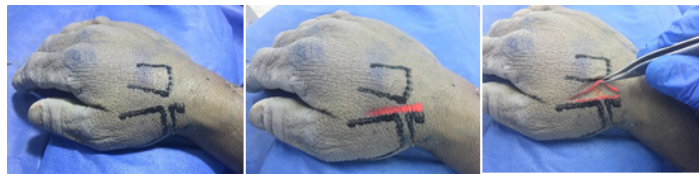Ethical considerations

In accordance with the principles established in the international ethical guides for biomedical investigation in human beings (CIOMS 2002 Guides) and in Resolution 008430 dated on the 4th day of October 1993, it is considered that this investigation is classified as a no-risk investigation, because it is an observation study in which anatomic dissections were made on corpses with the purpose of documenting, through photographic recording, an anatomic exposure that allows the dorsal tackling of the hand. All protocols related to management and investigation in corpses were applied.

Results

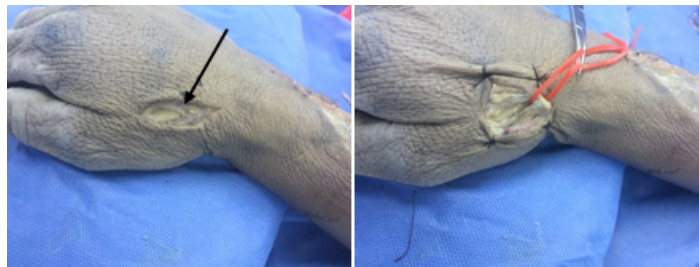Four cadaveric specimens were dissected, on 100% of the same an initial graphic recording was made about anatomic repairs (base of first metacarpal, scaphoids and base of second metacarpal) (Figure 1). Afterwards, an exclusively dorsal tackling was drawn

between the base of the first and the second metacarpal (Figure 2). An incision of the skin was made on the already illustrated tackling (Figure 3).

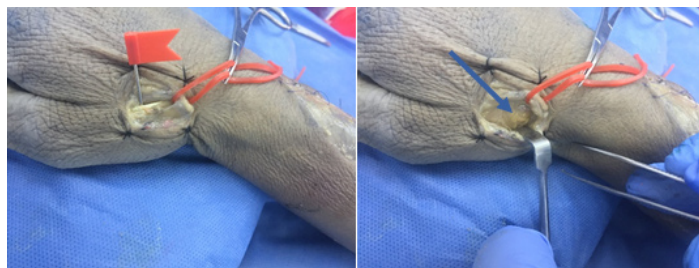


From left to right: Figure 1: Initial graphic recording of anatomic repairs (base of first metacarpal, scaphoids and base of second metacarpal). **Figure 2:** Exclusively dorsal tackling between the base of the first and second metacarpal (Red line). **Figure 3:** Incision of the skin over the exclusively dorsal tackling.

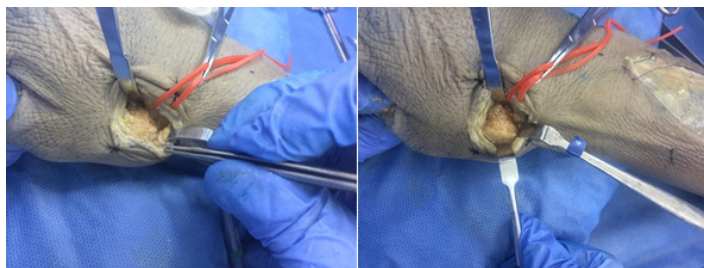
In 100% of the dissections, the dorsal sensitive branch of radial nerve was identified, which allowed to repair it and reject it for continuing with the dissection (Figures 4,5). The tendon of the long abductor in the thumb was identified (Figure 6) and the tendon was separated toward radial (Figure 7), which allowed to see the articular capsule of the first metacarpal base, which was tore apart and allowed to exposure more than 80% of the articular surface of the first metacarpal base (Figures 8,9). Finally, the articular capsule was closed plane by plane.



From left to right: Figure 4: Identification of the sensitive dorsal branch of the radial nerve (black arrow). **Figure 5:** Separation of the sensitive dorsal branch of the radial nerve (red band).



From left to right: Figure 6: Identification of the long tendon of the thumb abductor (red band). **Figure 7:** Separation of the long tendon of the thumb abductor toward radial and identification of the carpometacarpal joint capsule of the first finger in the hand (blue arrow).



From left to right: Figure 8: Incision of the carpometacarpal capsule of the first finger in the hand and exposure of the articular surface (black arrow). **Figure 9:** Exposure of more than 80% of the articular surface of the first metacarpal with limitation to visualize the more palmar and cubital portion.

Discussion

The Wagner tackling, although being widely used, has as its main complication the injury of the sensitive dorsal branch of the radial nerve, which leads at the short and long run to anesthesia on the episthenar or even to chronic pain of neuropathic type. Additionally, this tackling doesn't allow a full exposure of the carpometacarpal articulation of the first finger. And it is there where our project sought to describe an exclusively dorsal tackling in the hand, between the base of the first and second metacarpals that allowed a suitable visualization of the dorsal sensitive branch of the radial nerve, making in this way its separation easier and without injury. Added to the visualization of more than 80% of the articular surface that allows an anatomic reduction and a correct internal fixation at the time of intervening a patient, which would allow to decrease short- and long-term complications such as anesthesia, chronic pain, functional limitation and arthrosis.

References

1. Arguelles F, Mut T, Navarro A, García A (1976) Fracturas de la base del primer metacarpiano: clasificación y tratamiento. *Rev Esp De Cir Ost* 11: 223-239.
2. Kang JR, Behn AW, Messana J, Ladd AL (2019) Bennett Fractures: A Biomechanical Model and Relevant Ligamentous Anatomy. *J Hand Surg Am* 44: 154.e1-154.e5.
3. Rivlin M, Fei W, Mudgal C (2015) Bennett Fracture. *J Hand Surg Am* 40: 1667-1668.
4. Kamphuis SJM, Greeven APA, Kleinvelde S, Gosens T, Van Lieshout EMM, et al. (2019) Bennett's fracture: Comparative study between open and closed surgical techniques. *Hand Surg Rehab* 38: 97-101.
5. Greeven APA, Van Groningen J, Schep NWL, Van Lieshout (2019) Open reduction and internal fixation versus closed reduction and percutaneous fixation in the treatment of Bennett fractures: A systematic review. *Injury* 50: 1470-1477.
6. Van Niekerk JL, Ouwens R (1989) Fractures of the base of the first metacarpal bone: results of surgical treatment. *Injury* 20: 359-362.
7. Carlsen BT, Moran SL (2009) Thumb Trauma: Bennett Fractures, Rolando Fractures and Ulnar collateral Ligament Injuries. *J Hand Surg Am* 34: 945-952.
8. Levy V, Mazzola M, Gonzalez M (2018) Intra-articular Fractures of the Base of the First Metacarpal Bone: Treatment Through a Volar Approach. *Hand (NY)* 13: 90-94.