

Displaced Occluder Removed Fourteen Years after Interventional Therapy

Fang Liu^{1*}, Haizhou Zhang^{2*}, Mingliang Dong^{2*}, Yong Li², Li Yu², Qingbao Li²

¹Department of Image, Shandong Medical College, China

²Department of Cardiac Surgery, Shandong Provincial Hospital Affiliated to Shandong First Medical University, China

* The authors contributed equally to this work.

***Corresponding author:** Qingbao Li, Department of Cardiac Surgery, Shandong Provincial Hospital Affiliated to Shandong First Medical University, 324, Jingwu Road, Jinan 250021, China. Tel: +86-53168773127; Email: qingbao2004@sina.com

Citation: Liu F, Zhang H, Dong M, Li Y, Yu L, et al. (2020) Displaced Occluder Removed Fourteen Years after Interventional Therapy. Ann Case Report 14: 398. DOI: 10.29011/2574-7754/100398

Received Date: 14 May, 2020; **Accepted Date:** 28 May, 2020; **Published Date:** 04 June, 2020

Central Message

Interventional therapy for congenital heart disease is common and safe now. The displacement of occluder is one of the most undesirable complications, and usually it can be treated in time and effectively. Here we reported a case of patent ductus arteriosus occluder displacement cured 14 years after interventional therapy. We also showed the changes of the heart and lungs caused by the occluder displacement. The case is very rare, and it can help us to analyze the reasons and treatments of occluder displacement.

Keywords: Congenital heart disease; Interventional therapy; Occluder displacement

Introduction

Patent Ductus Arteriosus (PDA) can shunt blood between aorta and pulmonary arteries, which in turn causes significant problems. Interventional therapy with occluder has been suggested to be the standard treatment of PDA. Although displacement of occluder is a rare complication, it can lead to terrible outcomes. For some cases, surgical treatment is the unique effective method at present. We describe a rare case undergoing surgical removal of a PDA occluder 14 years after percutaneous closure.

A 15-year-old female, who accepted PDA interventional

therapy 14 years ago at the local hospital, was admitted for 4 days of hemoptysis. Nearly no murmur was heard over the heart. The pulse oxygen saturation of four limbs is 97% (left hand), 94% (right hand), 96% (left foot), and 95% (right foot) respectively. The echocardiogram showed a PDA, 1.8cm in diameter. Slow blood flow from left to right through PDA was a little more than that from right to left. And a displaced occluder, attached to the right pulmonary artery opening, allowing only a few blood flows to the distal arteries, was revealed. The mean pulmonary artery pressure was 84mmHg. CT examination confirmed the existence of the PDA and the displaced occluder. And CT also showed that small pulmonary arteries in right lung field were much fewer than that in left lung field (Figure 1).

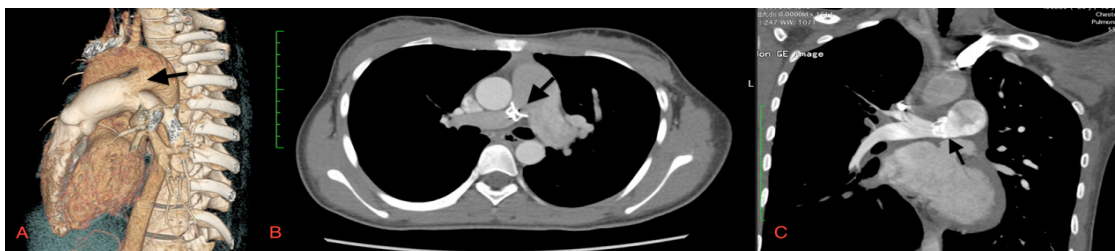


Figure 1: (A) Three-dimensional images showing the PDA. (B) Cross section CT image showing the displaced occluder. (C) Longitudinal section CT image showing the displaced occluder and fewer pulmonary arteries in right lung field.

During operation, the patient was operated upon under standard cardiopulmonary bypass with aorto-bicaval cannulation and a continuously perfused empty beating heart at 35°C through a median sternotomy. The PDA was sutured directly with four 4-0 prolene stitches, and the occluder, covered with proliferative intima and attached tightly to the right pulmonary artery, was separated and removed carefully from the artery wall finally, without damaging the endarterium (Figure 2). No thrombus was found around the occluder or in the pulmonary arteries. The young patient tolerated the operation well and was discharged in 7 days. The mean pulmonary artery pressure decreased from 84 mmHg to 35 mmHg (Figure 3).

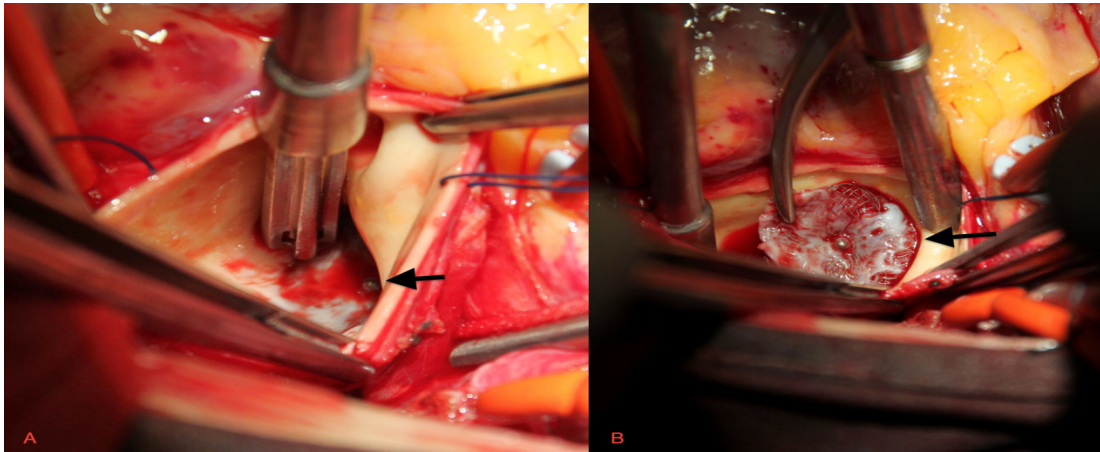


Figure 2: (A) The occluder was covered with proliferative intima and attached tightly to the right pulmonary artery. (B) The occluder was separated and removed carefully from the artery wall.

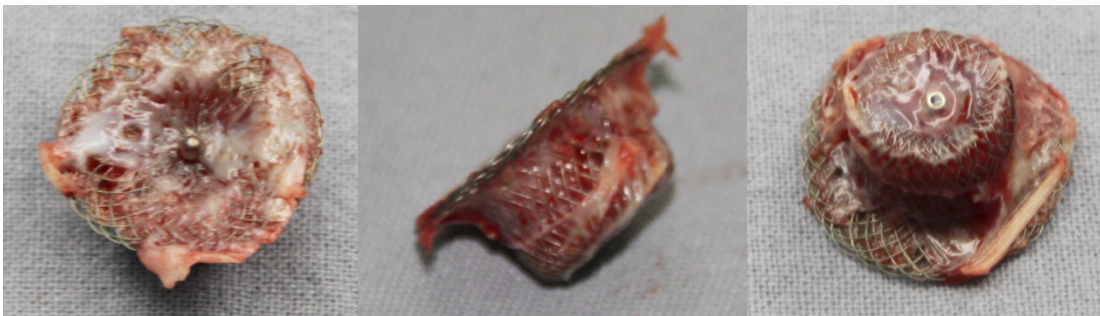

Figure 3: Different angles to show the removed occluder.

Comment

For congenital heart disease patient with indication, interventional therapy is safe, effective and minimally invasive [1]. The PDA occlusion rate is as high as 98.1% after the short-term, mid-term, and long-term follow-ups [2]. Displacement of occluder is caused mainly by the following reasons: a. improper indication; b. too small occluder selection; c. incorrect imaging judgment of occluder shape and position before release; d. unskilled technical operation; e. quality problems of occluder and delivery system; f. external force after operation. Since the displacement of occluder may endanger the patient's life and complicate the clinical treatment, after the interventional closure, the patient's condition should be observed carefully, and the ultrasound or chest X-ray examination should be reexamined in time. Once the occluder falls off, it should be taken out by intervention or operation immediately [3]. The optimal antithrombotic strategy after PDA interventional therapy is undisputed. Antiplatelet therapy with aspirin is the most frequently used regiment [4,5]. Usually, in our center, patients are given heparin intravenously after PDA closure, and then aspirin was taken for 6 months. It is really lucky for this case that there was no thrombus formed around the occluder, which may in turn caused fatal pulmonary embolism. It is clear that the use of aspirin avoids this risk.

The occluder is usually complete endothelialised in 6 months, and then it is not easy to fall off [6]. As to our case, it is really hard to determine the sure time when the occluder displaced, because her guardian refused all the postoperative review and follow-up. But

because the patients have to be reexamined before discharge, it is obvious that the occluder is not displaced during hospitalization. Therefore, it is most probably that the displacement occurred within 6 months after discharge. The changes of the heart and lung, and appearance of the occluder, also suggest that the displacement occurred long time ago. PDA is persistent due to the occluder displacement. The pathophysiological changes caused by PDA, including left ventricular enlargement, pulmonary artery thickening and pulmonary artery pressure increase, were not removed. On the contrary, the occlusion of right pulmonary artery resulted in sparse vascular shadow in the right lung field and obvious thickening of left pulmonary artery. Fortunately, when the patient came to see the doctor, there was still an indication of surgery. Otherwise, once Eisenmenger's syndrome happened, there would be no chance of surgery.

Anyway, interventional therapy is still a good treatment for some congenital heart disease. With the accumulation of experience and the proficiency of operation technology, the complications can be minimized.

COI Statement

No potential conflicts of interest to disclose.

Funding Statement

No funding for this article.

References

1. Rao PS, Sideris EB, Haddad J, Rey C, Hausdorf G, et al. (1993) Transcatheter occlusion of patent ductus arteriosus with adjustable buttoned device: Initial clinical experience. *Circulation* 88: 1119-1126.
2. Behjati-Ardakani M, Rafiei M, Behjati-Ardakani MA, Vafaeenasab M, Sarebanhassanabadi M (2015) Long-term Results of Transcatheter Closure of Patent Ductus Arteriosus in Adolescents and Adults with Amplatzer Duct Occluder. *N Am J Med Sci* 7: 208-211.
3. Jang GY, Son CS, Lee JW, Lee JY, Kim SJ (2007) Complications after transcatheter closure of patent ductus arteriosus. *J Korean Med Sci* 22: 484-490.
4. Polzin A, Dannenberg L, Sophia Popp V, Kelm M, Zeus T (2016) Antiplatelet effects of clopidogrel and aspirin after interventional patent foramen ovale/ atrium septum defect closure. *Platelets* 27: 317-321.
5. Kim KM, Kim H, Chi HS, Park JS, Kim SB (2010) Comparison of antiplatelet potency of sarpogrelate, aspirin, and beraprost in healthy volunteers according to *in-vitro* closure time. *Blood Coagul Fibrinolysis* 21: 262-265.
6. Wilson W, Taubert KA, Gewitz M, Lockhart PB, Baddour LM, et al. (2007) Prevention of infective endocarditis: guidelines from the American Heart Association: a guideline from the American Heart Association Rheumatic Fever, Endocarditis, and Kawasaki Disease Committee, Council on Cardiovascular Disease in the Young, and the Council on Clinical Cardiology, Council on Cardiovascular Surgery and Anesthesia, and the Quality of Care and Outcomes Research Interdisciplinary Working Group. *Circulation* 116:1736-1754.