

# Journal of Anaplastology & Reconstructive Surgery

Renz O, et al. J Anaplast Reconstr Surg: JARS-101.

DOI: 10.29011/JARS-101. 000001

## Case Report

## Decision-Making and Challenging Surgery in a Child with a Giant Tumor of the Sacro-Gluteal Region: A Humanitarian Aid Context

Oliver Renz\*, Paul Hechenleitner, Gerd Wimmer, Murat Sanal, Beatrice Häussler

Department of Pediatric Surgery, University Hospital Innsbruck, Austria

\*Corresponding author: Oliver Renz, Department of Pediatric Surgery, University Hospital Innsbruck, Austria. Tel: +4351250480810; Email: oliver.renz@tirol-kliniken.at

**Citation:** Renz O, Hechenleitner P, Wimmer G, Sanal M, Häussler B (2018) Decision-Making and Challenging Surgery in a Child with a Giant Tumour of the Sacro-Gluteal Region: A Humanitarian Aid Context. J Anaplast Reconstr Surg: JARS-101. DOI: 10.29011/JARS-101. 000001

**Received Date:** 02 August, 2018; **Accepted Date:** 06 August, 2018; **Published Date:** 15 August, 2018

### Abstract

Sacrococcygeal teratoma (SCT) is a common germ cell tumor in infancy and early childhood. SCTs are generally benign tumors; however, malignant elements can be present, and their frequency increases with the age of the patient. In the rare case of a nine-year-old girl from Zimbabwe with a giant sacro-gluteal tumor, appropriate decision-making was a very demanding task, especially under the circumstances of humanitarian aid. A total resection of the tumor with reconstructive surgery of soft tissue was performed. Histology showed a mature Altman Type II teratoma consisting of fully differentiated tissues from somatic sites. Post-operative care included wound treatment and physiotherapy. Due to meticulous decision-making, this case of SCT was treated successfully.

**Keywords:** Childhood; Humanitarian Aid; Sacrococcygeal Teratoma

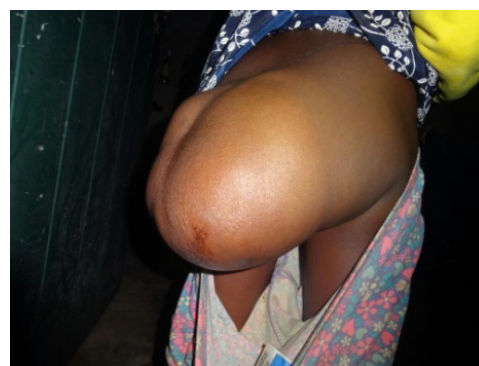### Introduction

Mature fetiform and malignant sacrococcygeal teratomas are rare tumors presenting mainly in neonates. Primary sacral tumors such as chordomas, osteoblastomas, and sacrococcygeal teratomas, presenting as large external tumor masses, are very rare in young adults [1, 2]. In our case, a nine-year-old girl from Zimbabwe presenting with a huge SCT was treated at our Department of Pediatric Surgery.

### Case Presentation

In December 2017, our Department of Pediatric Surgery received a request for humanitarian aid from the local non-profit relief organisation, “Lovemore - Tirol für Zimbabwe”, to provide treatment at our hospital for a nine-year-old girl from Zimbabwe presenting with a huge mass in the gluteal region. There was no detailed knowledge of her medical history available, and diagnostic findings were limited to standard blood count, X-ray image of

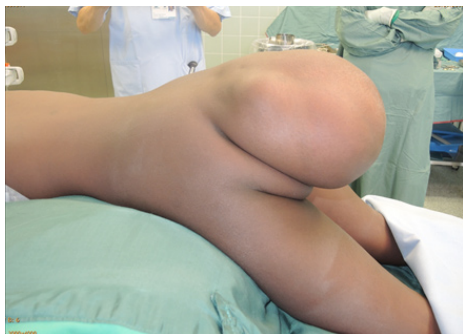the pelvic region, one ultrasound investigation, and two patient photographs (Figures 1 and 6).



**Figure 1:** The first photo of our patient from Zimbabwe.

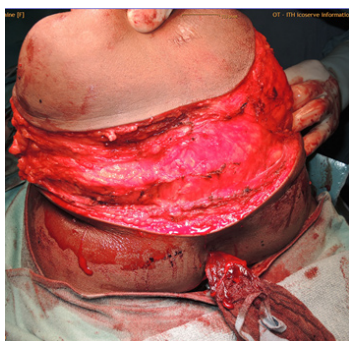
Generously, the chief financial officer of our hospital guaranteed coverage of all financial costs. Following admission to our hospital, further preoperative assessment confirmed our assumption of benign SCT by means of alpha-fetoprotein and beta-hCG tests, serum levels of which were within the normal range.

Ultrasound examination (duplex sonography) and an MRI scan showed mature Altman Type II SCT. Neuro-urological assessment revealed lower urinary tract dysfunction with post-void residual urine due to tumour compression, but without coexisting bowel dysfunction. Accurate preoperative planning was necessary to ensure the best possible functional and cosmetic results of this complex surgical procedure, since errors in treatment can rarely be corrected at a later date (Figure 2).

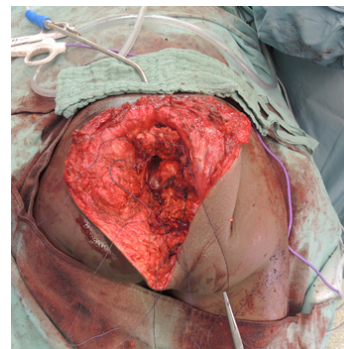


**Figure 2:** With the patient in the prone position, the pre-operative tumor size is exposed.

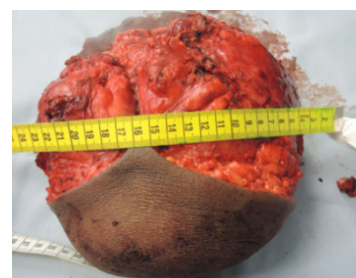
Surgery for the complete excision of the SCT, including removal of the coccyx, was performed. During the operation, special attention was paid to the conservation of both ureters in the pelvis and the nerve supply to the bladder and rectum, in addition to the protection of the sphincter muscle innervation. The main afferent presacral tumour artery was selectively ligated. Although the tumor was adherent to the surrounding tissue, all structures could be identified and separated without damage. Despite the remaining large wound area, primary skin closure could be achieved. Following reconstructive pelvic floor surgery, the remaining deep tumor cavity was closed with muscle layers and a supply of soft tissue (Figures 3, 4, and 5).



**Figure 3:** Intraoperative imaging.



**Figure 4:** Intraoperative imaging.



**Figure 5:** The removed tumor, with a size of 20 x 19 x 15 cm and a weight of 3 kg.

## Discussion

Overall, the key ethical question in humanitarian relief projects remains: do we do more harm than good? A major invasive surgical procedure should offer the best chance of a cure; however, due to the risk of possible postoperative complications such as wound healing problems, neurological deficits, and urinary and fecal incontinence, which may not be treated sufficiently, in addition to the need for urgent or long-term follow-ups, this is not usually feasible in low-income developing countries. Under these circumstances, we worked out three essential key criteria for decision-making, and finally accepted the major surgical challenge.

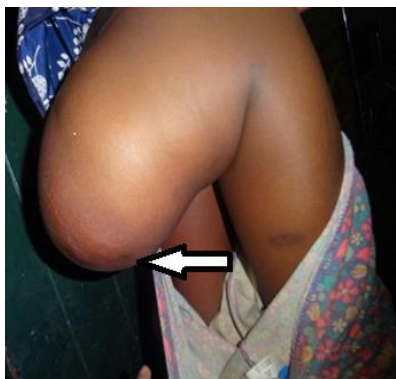### First key criterion

There was the challenging task of ensuring the correct differential diagnosis based on poor previous diagnostic findings. According to the report, the tumour had been present since birth, with a slow growth rate, and a recent photograph showed the child to be in good overall health, both of which were encouraging. On the other hand, an increase in tumour mass implied certain risks for the patient. However, as tumor size increases over time, so does the

risk of malignant transformation, and the subsequent development of metastatic disease [3, 4]. Therefore, complete surgical resection was the cornerstone of management in this setting, even though surgical resection is often an extensive procedure and can cause significant acute and long-term side effects [5, 6–10]. Taking into account all available information for the assessment, we diagnosed a mature sacrococcygeal teratoma. Finally, a histological examination confirmed a mature teratoma consisting of fully differentiated tissues from various somatic sites, with complete tumour resection in healthy tissue.

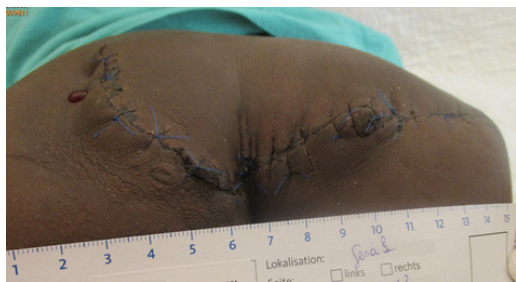## Second key criterion

A crucial factor for decision-making was that the tumor had already reached a critical size. It was expected to be only a matter of time until the tumor penetrated through the skin, which would most likely be followed by purulent infection with septicemia and possible fatal consequences (Figure 6).



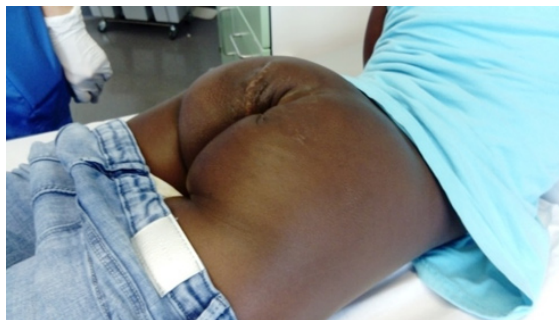**Figure 6:** The second photo of our patient from Zimbabwe showing the risk of a pressure ulcer (arrow).

Another important aspect was that without treatment further tumor growth would cause significant neurological malfunction and serious incontinence problems [7]. Postoperative neuro-urolological examination showed normal neurological bladder function without residual urine, and there were no postoperative bowel dysfunction problems such as incontinence or fecal soiling. During the first postoperative week, we observed good wound healing without any acute infection (Figure 7).



**Figure 7:** One week after the surgical intervention.

However, a spontaneous perforated and emptying seroma hollow space in the wound area subsequently led to a delayed healing process. This was followed by open phase-specific wound treatment during inpatient stay, which was completed as outpatient care (Figure 8).



**Figure 8:** Finally, the healing process led to a pleasing scar, with an excellent cosmetic result.

## Third key criterion

An important decision guidance for us was the quality of life aspect. The girl's father had left her mother and older siblings shortly after her birth, since disability is still considered a disgrace and cruse in Zimbabwe. Subsequently, poverty became worse for the family. Growing up, the girl had been increasingly socially marginalised in many different ways; and due to the increasing tumor size, the simplest of movements and activities such as sitting, running, and getting dressed had become more burdensome. For her, an extraordinary girl indeed, a new life with a completely new body image is just beginning (Figure 9).



**Figure 9:** Farewell photo prior to the patient returning home (with the consent of all persons for publication).

## Conclusion

In general, it can be said that, in pediatric surgery, there is a fine line between doing harm and good; however, the situation is particularly aggravated under the circumstances of humanitarian aid



in patients from low-income developing countries. For this reason, conscientious and careful decision-making is a precondition, and more than any overblown surgical ambition, first and foremost, is a mandatory ethical and moral obligation to medical care.

## References

1. Sood N, Kamboj M, Chaabra M (2013) Sacrococcygeal fetiform teratoma altman type 1: a rare case report in a 11-year-old girl. *Indian J Surg* 75: 359-361.
2. Puri A, Agarwal MG, Shah M, Srinivas CH, Shukla PJ, et al. (2009) Decision making in primary sacral tumors. *Spine J* 9: 396-403.
3. Rescorla FJ, Sawin RS, Coran AG, Dillon PW, Azizkhan RG (1998) Long-term outcome for infants and children with sacrococcygeal teratoma: a report from the Children's Cancer Group. *J Pediatr Surg* 33: 171-176.
4. Calaminus G, Schneider DT, Bökkerink JP, Gadner H, Harms D, et al. (2003) Prognostic value of tumor size, metastases, extension into bone, and increased tumor marker in children with malignant sacrococcygeal germ cell tumors: a prospective evaluation of 71 patients treated in the German cooperative protocols Maligne Keimzelltumoren (MAKEI) 83/86 and MAKEI 89. *J Clin Oncol* 21: 781-786.
5. Swamy R, Embleton N, Hale J (2008) Sacrococcygeal teratoma over two decades: birth prevalence, prenatal diagnosis and clinical outcomes. *Prenat Diagn* 28: 1048-1051.
6. Schropp KP, Lobe TE, Rao B, Mutabagani K, Kay GA, et al. (1992) Sacrococcygeal teratoma: the experience of four decades. *J Pediatr Surg* 27: 1075-1078.
7. Partridge EA, Canning D, Long C, Peranteau WH, Hedrick HL, et al. (2014) Urologic and anorectal complications of sacrococcygeal teratomas: prenatal and postnatal predictors. *J Pediatr Surg* 49: 139-142.
8. Huddart SN, Mann JR, Robinson K, Raafat F, Imeson J, et al. (2003) Sacrococcygeal teratomas: the UK Children's Cancer Study Group's experience. I. Neonatal. *Pediatr Surg Int* 19: 47-51.
9. Mann JR, Gray ES, Thornton C, Raafat F, Robinson K, et al. (2008) Mature and immature extracranial teratomas in children: the UK Children's Cancer Study Group Experience. *J Clin Oncol* 26: 3590-3597.
10. Marina NM, Cushing B, Giller R, Cohen L, Lauer SJ, et al. (1999) Complete surgical excision is effective treatment for children with immature teratomas with or without malignant elements: A Pediatric Oncology Group/Children's Cancer Group Intergroup Study. *J Clin Oncol* 17: 2137-2143.