

Case Report

Savoj J, et al. Curr Trends Intern Med 2: 104.

DOI: 10.29011/2638-003X.100004

Combination of Unfractionated Heparin (UFH) and Triple Antiplatelet Therapy After Percutaneous Coronary Intervention (PCI) May Increase the Risk of Life Threatening Hemothorax in a Patient with Recent Rib Fracture

Javad Savoj, Asma Jamil, Syed Iftikhar, Rajesh Gulati*

Department of Internal Medicine, Riverside Community Hospital/UCR School of Medicine, USA

*Corresponding author: Rajesh Gulati, Department of Internal Medicine, Riverside Community Hospital/UCR School of Medicine, USA. Tel: +19517883252; Fax: +18558723252; Email: rgulati@medsch.ucr.edu

Citation: Savoj J, Jamil A, Iftikhar S, Gulati R (2018) Combination of Unfractionated Heparin (UFH) and Triple Antiplatelet Therapy After Percutaneous Coronary Intervention (PCI) May Increase the Risk of Life Threatening Hemothorax in a Patient with Recent Rib Fracture. Curr Trends Intern Med 2: 104. DOI: 10.29011/2638-003X.100004

Received Date: 23 March, 2018; **Accepted Date:** 06 April, 2018; **Published Date:** 16 April, 2018

Abstract

It is a well-known fact that ST Elevation Myocardial Infarction (STEMI) is an emergent condition which requires urgent intervention. Oftentimes, STEMI presents in the setting of a cardiac arrest or arrhythmia during which the patient has required chest compressions. If Return of Spontaneous Circulation (ROSC) is thus achieved, a very common circumstance for these patients is the appearance of fractured ribs. Due to this traumatic experience, these fractures and injuries can likely pose a bleeding risk. However, at the same time urgent anti-coagulative and anti-platelet activity is known to be a standard care in such patients. The bleeding risk involved with such therapies has been explored in other conditions such as subarachnoid hemorrhage and it has been deemed to be a risk factor which must be evaluated closely. Similarly, post-PCI bleeding complications have been explored with regards to complex MI, free wall ruptures, etc. However, the same caution has not been evaluated with regards to rib fractures and potential complication of hemothorax in those with MI receiving antiplatelet and anti-coagulation medications. We propose that this is a common scenario, which must at least be evaluated or considered prior to beginning treatment with such medications and is a potential complication which must at least be considered following revascularization.

Introduction

ST Elevation Myocardial Infarction (STEMI) is a medical emergency that requires immediate recognition and intervention. Aside from the many guidelines described by the American College of Cardiology/American Heart Association (ACC/AHA) regarding STEMI management, complications arising from the use of Dual Antiplatelet Therapy (DAPT) along with the anticoagulation still need to be evaluated. ACC/AHA guidelines in 2013 and 2016 recommended a similar DAPT regimen for patients being treated with Bare-Metal Stent (BMS) and Drug-Eluting Stent (DES) placement in the acute setting [1,2]. Both organizations recommend the initiation of DAPT, specifically Acetylsalicylic Acid (ASA) and P2Y₁₂ inhibitors, prior to a patient undergoing PCI for STEMI [1]. Anticoagulation is also a standard of care in these patients and specifically, Unfractionated Heparin (UFH) and Glycoprotein IIb/IIIa (GPIIb/IIIa) inhibitors are the medications which

have been recommended [1]. One caveat is that Bivalirudin, a Direct Thrombin Inhibitor (DTI), is recommended as opposed to UFH if there is significant risk of bleeding [1]. Currently, recent trauma and subsequent rib fracture is not considered a risk factor for high likelihood of bleeding. We propose that patients who have recent history of rib fracture secondary to trauma or recent chest compressions should be shown particular attention with regards to antiplatelet and anticoagulant treatment of STEMI per protocol. One such complication which we demonstrate in this case is that of a patient who developed severe hemothorax secondary to bleeding from a recent rib fracture after being treated with standard of care treatment for STEMI.

Case Presentation

70-year-old male with history of coronary artery disease was presented to Emergency Department (ED) with STEMI. Patient

had history of rib fracture following mechanical fall 5 days earlier (Figure 1). Patient was taken to the cardiac catheterization unit. Right before procedure patient was coded due to ventricular fibrillation. Patient was intubated, Cardiopulmonary Resuscitation (CPR) was started and after defibrillation he regained sinus cardiac rhythm. PCI revealed occluded previous distal right coronary artery stent which was ballooned and re-stented (Figure 2). Being in cardiogenic shock after PCI, intra-Aortic balloon pump was placed to stabilize hemodynamics. After receiving intracoronary Abciximab (a GPIIb/IIIa inhibitor) and a bolus of UFH, patient was started on heparin drip and DAPT with ASA and Clopidogrel and was transferred to Intensive Care Unit (ICU). After one day being stable in ICU, patient was extubated. However, patient was complaining of worsening of chest wall pain. Follow up x-ray and subsequent CT scan of the chest after 48 hours from PCI showed massive right hemothorax and chest wall hematoma around the fractured ribs area (Figure 3,4). Heparin and antiplatelet medications were all stopped. Patient's hemoglobin dropped from 11.4 to 6.3 g/dl in 24 hours. Patient was intubated again and started on intravenous fluids, vasopressors, and blood transfusion. Interventional Radiologist was consulted for possible embolization. However, source of bleeding was not found. Anticoagulation reversal and platelet transfusion was not done due the high risk of coronary restenosis and MI. Patient's bleeding was eventually stopped after a few hours of closed monitoring and resuscitation. He regained stable vital sign after 24 hours and was extubated. IABP was removed. ASA was started after 48 hours and Clopidogrel was added 2 days after ASA. Patient was transferred in stable condition to a long-term acute care facility.

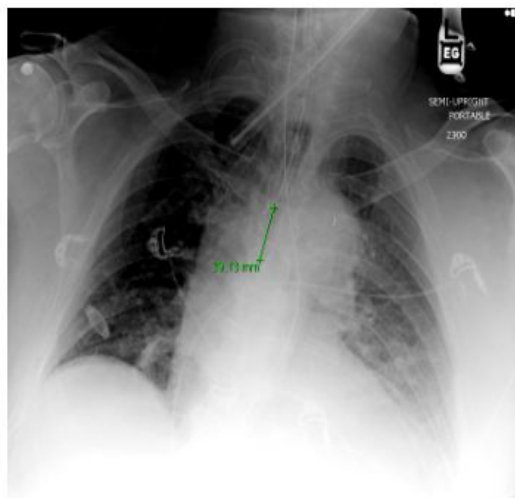


Figure 1: Acute rib fracture of the left second to fourth rib, the left costophrenic angle is slightly obscured which could be secondary to left side pleural effusion or small hematoma caused by rib fracture or lung contusion before start of UFH and antiplatelet medications.

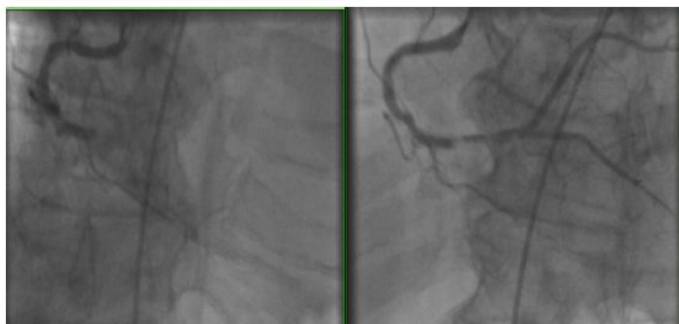


Figure 2: PCI showed right coronary artery restenosis (before and after ballooning).

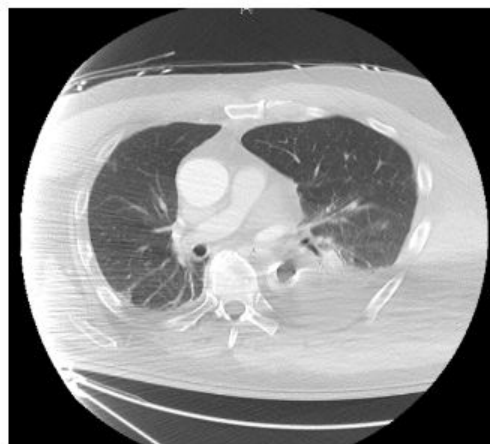

Figure 3: Left intrathoracic hematoma with extension to extra thoracic soft tissue.

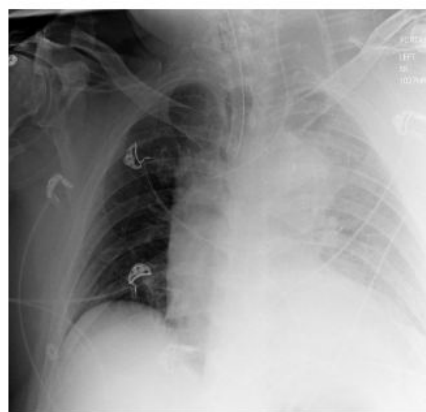

Figure 4: Left side hematoma on chest x-ray.

Discussion

Rib fractures are more commonly encountered in routine practice than generally considered [3]. Having rib fractures should

be specifically considered in the setting of trauma as well as CPR in patients who have history of recent cardiac arrest with chest compression. Emond et al. In a 6-year cohort prospective study on 1382 patients showed that there is 10.9% chance of delayed hemothorax within 14 days of chest trauma in patients with minor thoracic injury. They proposed the validated Quebec minor thoracic injury clinical decision rule, using age, rib fracture location, and number of rib fractures as different variables to identify patients at high risk of delayed hemothorax with 90% specificity [4]. Our patient with history of recent rib fracture needed immediate PCI in the setting of STEMI. In consistence with current guidelines, Abciximab was administered during PCI. UFH intravenous infusion as well as DAPT were both started and continued until the patient showed symptoms of bleeding. Current guidelines do not specifically address the duration of heparin use along with DAPT. There is no data available to evaluate the risk of bleeding after PCI in patients receiving both DAPT and UFH.

Although the use of GPIIb/IIIa along with UFH has been associated with higher risk of bleeding, but most studies have recommended this combination if the benefit outweighs the risks [5]. Amongst the GPIIb/IIIa inhibitors, Abciximab has been shown to be more effective in prevention of the stent restenosis but at the cost of higher risk of bleeding complications [6]. As mentioned earlier Bivalirudin is preferred over UFH, if high risk of bleeding is suspected but the distinction between high and low risk is still not well defined [7].

According to current guidelines, patients with history of major bleeding (e.g. intracranial bleeding) or recent history of oral anticoagulants intake are considered high risk for bleeding [2]. However, the safety of receiving DAPT along with anticoagulation in patients with history of recent chest trauma and rib fracture is still unclear.

Conclusion

Our case is an example of patient with recent history of rib fracture as a potential major risk factor for post PCI bleeding. More studies are required to assess the characteristics of rib fracture (e.g. location, number of fractured ribs, and patient's age) as a major bleeding risk factor. Moreover, more studies are warranted to assess the risk vs. benefit of using Bivalirudin instead of UFH in these patients.

References

1. O'Gara PT, Kushner FG, Ascheim DD, Casey DE Jr, Chung MK, et al. (2013) 2013 ACCF/AHA guideline for the management of ST-elevation myocardial infarction: executive summary: a report of the American College of Cardiology Foundation/American Heart Association Task Force on Practice Guidelines. *J Am Coll Cardiol* 61: 485-510.
2. Levine GN, Bates ER, Bittl JA, Brindis RG, Fihn SD, et al. (2016) 2016 ACC/AHA Guideline Focused Update on Duration of Dual Antiplatelet Therapy in Patients With Coronary Artery Disease: A Report of the American College of Cardiology/American Heart Association Task Force on Clinical Practice Guidelines. *J Am Coll Cardiol* 68: 1082-115.
3. Kralj E, Podbregar M, Kejžar N, Balažic J (2015) Frequency and number of resuscitation related rib and sternum fractures are higher than generally considered. *Resuscitation* 93: 136-141.
4. Émond M, Guimont C, Chauny JM, Daoust R, Bergeron É, et al. (2017) Clinical prediction rule for delayed hemothorax after minor thoracic injury: a multicentre derivation and validation study. *CMAJ Open* 5: 444-453.
5. Faxon DP (2005) Use of antiplatelet agents and anticoagulants for cardiovascular disease: current standards and best practices. *Rev Cardiovasc Med* 6: 3-14.
6. Wong YW, Prakash R, Chew DP (2010) Antiplatelet therapy in percutaneous coronary intervention: recent advances in oral antiplatelet agents. *Curr Opin Cardiol* 25: 305-311.
7. Ghosh BD, Swaminathan RV, Kim LK, Feldman DN (2012) Reperfusion therapy in ST-elevation myocardial infarction: guidelines, strategies, pharmacology, and stent selection. *Minerva Med* 103: 431-439.