



Case Report

A Gastric Adenocarcinoma Case Presenting with Hematuria

Hacı Arak*, Fatih Teker

Department of Medical Oncology, Gaziantep University School of Medicine, TR-27310, Gaziantep, Turkey

*Corresponding author: Hacı Arak, Department of Medical Oncology, Gaziantep University School of Medicine, TR-27310, Gaziantep, Turkey

Citation: Arak H, Teker F. (2022) A Gastric Adenocarcinoma Case Presenting with Hematuria. J Urol Ren Dis 07: 1267. DOI: 10.29011/2575-7903.001267.

Received Date: 25 April, 2022; **Accepted Date:** 29 June, 2022; **Published Date:** 01 July 2022

Abstract

Gastric cancer is one of the most common cancers. The vast majority of gastric cancers are histologically classified as adenocarcinoma and may cause unexpected organ metastases. Primary bladder tumor is a common urological malignancy. The incidence of secondary bladder tumor from a distant organ is extremely rare. Secondary bladder tumors are usually caused by metastasis from anatomically adjacent organs such as the cervix, colon, and prostate. Differentiation of primary and secondary adenocarcinomas of the bladder is difficult, yet important in terms of making the right treatment choice. Metastasis of gastric adenocarcinoma to the bladder is very rare. The case presented herein is a 50-year-old male patient who underwent total gastrectomy for gastric adenocarcinoma and presented with hematuria while receiving systemic therapy. The mass lesion located in patient's bladder was resected using cystoscopy, and he was diagnosed with gastric adenocarcinoma metastasis as the final diagnosis. There are currently no guidelines for the management of this rare condition. Therefore, it is aimed with this case report to contribute to the limited literature on this rare condition.

Keywords: Gastric adenocarcinoma; Hematuria; Secondary bladder cancer

Introduction

Gastric cancer is the fifth most common cancer worldwide and the third most common cause of cancer-related deaths. Risk factors for gastric cancer include *Helicobacter pylori* infection, advanced age, familial history of gastric cancer, high salt intake, and a diet low in fruit and vegetables[1]. Histologically, 95% of gastric cancers are classified as adenocarcinomas. Surgery is the only curative method of treatment in the early stage of gastric cancers. The patients are generally diagnosed with gastric cancer when it is at the local, regional or metastatic stage. The median survival of patients at metastatic stage is approximately 1 year. Since gastric cancer can spread directly through serosal spread, lymphogenic or vascular dissemination, it can cause unexpected metastases[2]. Metastatic bladder tumors constitute 2% of all bladder tumors. Secondary bladder neoplasms usually originate in the bladder itself or in surrounding organs such as the colon, prostate gland, or

cervix. Only 4.3% of these secondary tumors originate from gastric cancer[3]. This case report features a metastatic bladder tumor originated from a primary gastric adenocarcinoma.

Case Report

A 50-year-old male patient was presented to the hospital with new onset dyspepsia and weight loss. Other than dyspepsia, the patient had no complaints including nocturia, urgency and hematuria. The patient was a smoker and his medical history was unremarkable, however he had a cousin with stomach cancer in his familial history. He was planned to have gastroscopy given the warning symptoms. In gastroscopy, an ulcerovegetant mass starting from the small curvature of the stomach and extending to the antrum was observed. The biopsy taken during gastroscopy was assessed as gastric adenocarcinoma. The preoperative PET/CT (Positron Emission Tomography and Computed Tomography) images of the patient are shown in Figure 1.

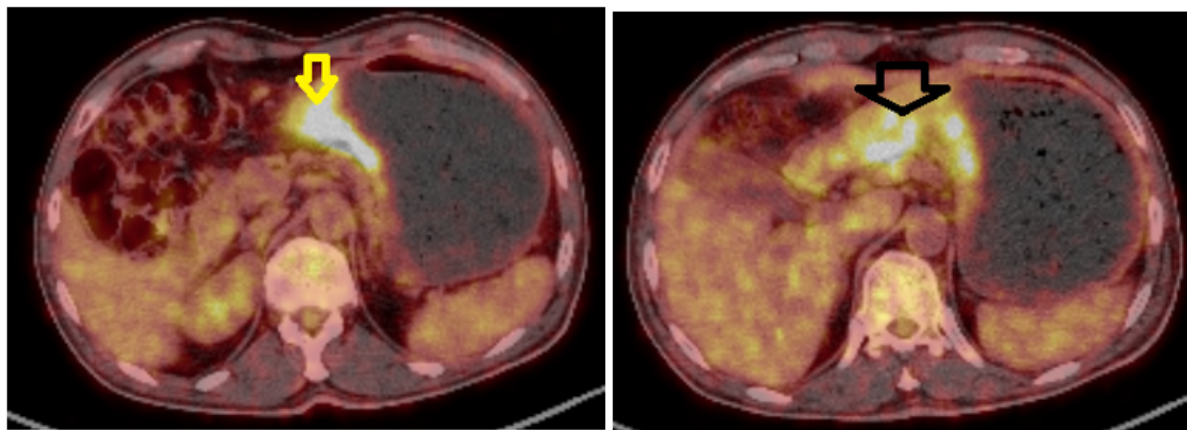


Figure 1: Axial 18F FDG PET/CT images of the patient: **A)** Prominent diffuse FDG uptake was observed through the thickened medial wall structures located in the distal portion of the corpus of the stomach. **B)** Circular wall thickening with markedly increased FDG uptake was observed in the antral section of the stomach in continuity with the hypermetabolic corporeal wall structures.

Distant metastasis was not observed on the preoperative CT images of the patient. He was planned to have surgical treatment since he was considered to be resectable. Accordingly, he was performed total gastrectomy and Roux-en-Y esophagojejunostomy. During the surgery, a lesion compatible with 2x2 cm metastasis was observed in segment 4 of the liver. Thus, metastectomy was performed in the same session. The histopathological evaluation of the surgical material revealed that the tumor was infiltrated into the serosa, lymphovascular and perineural invasion was present, and there was metastasis in 13 of the 29 lymph nodes that had been removed. Consequently, he was diagnosed with gastric well-differentiated adenocarcinoma and liver adenocarcinoma metastasis. The adenocarcinoma was staged as pT4N3M1 according to the 8th TNM staging system. C-erbB-2, which was examined with immunohistochemistry, was negative.

The systemic treatment of the patient was started with oxaliplatin+capecitabine (CAPEOX) chemotherapy protocol every 3 weeks in the postoperative period. No distant organ metastasis was observed in the follow-up evaluation performed after 3 cycles of CAPEOX. The patient's ECOG (Eastern Cooperative Oncology Group) performance score was determined as 1. His oral intake was sufficient with no nausea and vomiting. The level of the tumor marker, CEA (carcinoembryonic antigen) test, was 1.18 and normal. Considering that the patient's clinical condition was improving, it was planned to complete the CAPEOX protocol in 6 cycles. During

the 5th cycle, the patient was admitted to the emergency service with left flank pain and macroscopic hematuria. In the intravenous (IV) contrast-enhanced abdominal CT performed, it was observed that the bilateral renal pelvicalyceal structures were moderately dilated and there was significant thickening in the bladder posterior and right lateral walls (Figure 2). In addition, the CEA level had increased to 9.11 from the previous level of 1.11. The results of his laboratory test were as follows: hemoglobin: 12.3 g/dL (normal range: 12.5-16.5 g/dL), creatine: 1.05 mg/dL (normal range 0.6-1.2 mg/dL), sodium: 141 mmol/L (135-145 mmol/L), and potassium: 3.8 mmol/L (3.5-5 mmol/L). Since the patient had hematuria and hydronephrosis, cystoscopy was planned. A hyperemic, suspicious tumoral mass, which is 5 cm in size, was observed in the posterior wall of the bladder via the cystoscope, and the mass was resected cystoscopically. The histopathological evaluation of the mass taken from the bladder revealed that the cytokeratin (CK)-7, CEA, and caudal-type homeobox 2 (CDX2) were positive, whereas CK-20 and GATA-3 were negative (Figure 3). Consequently, a definite diagnosis of gastric adenocarcinoma metastasis was made. In the follow-up gastroscopy performed during this period, no recurrence was observed in the stomach. The complaints of flank pain and hematuria regressed. Having developed distant organ metastasis, the patient died 2 months later due to disease progression and cachexia. For this case report, "informed consent" was obtained from the patient's legal representative.

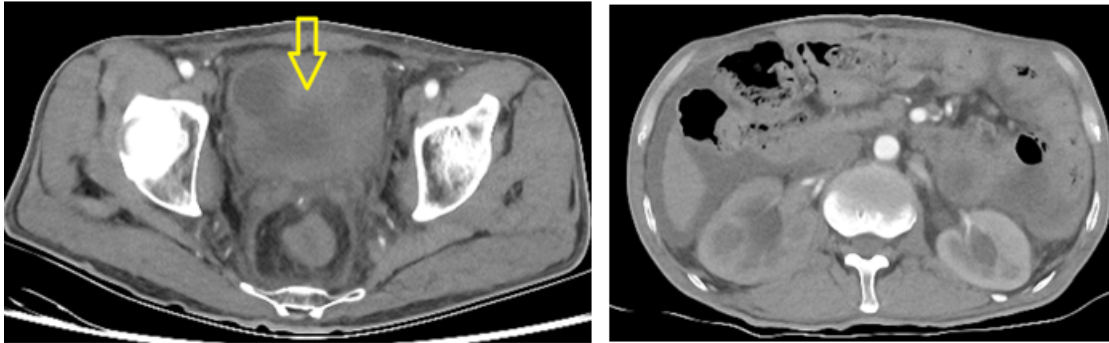


Figure 2: Axial CT images of the patient: **A)** CT scan has demonstrated diffuse irregular thickening of the bladder wall. **B)** Bilateral renal pelvicalyceal structures appear moderately dilated in this CT scan.

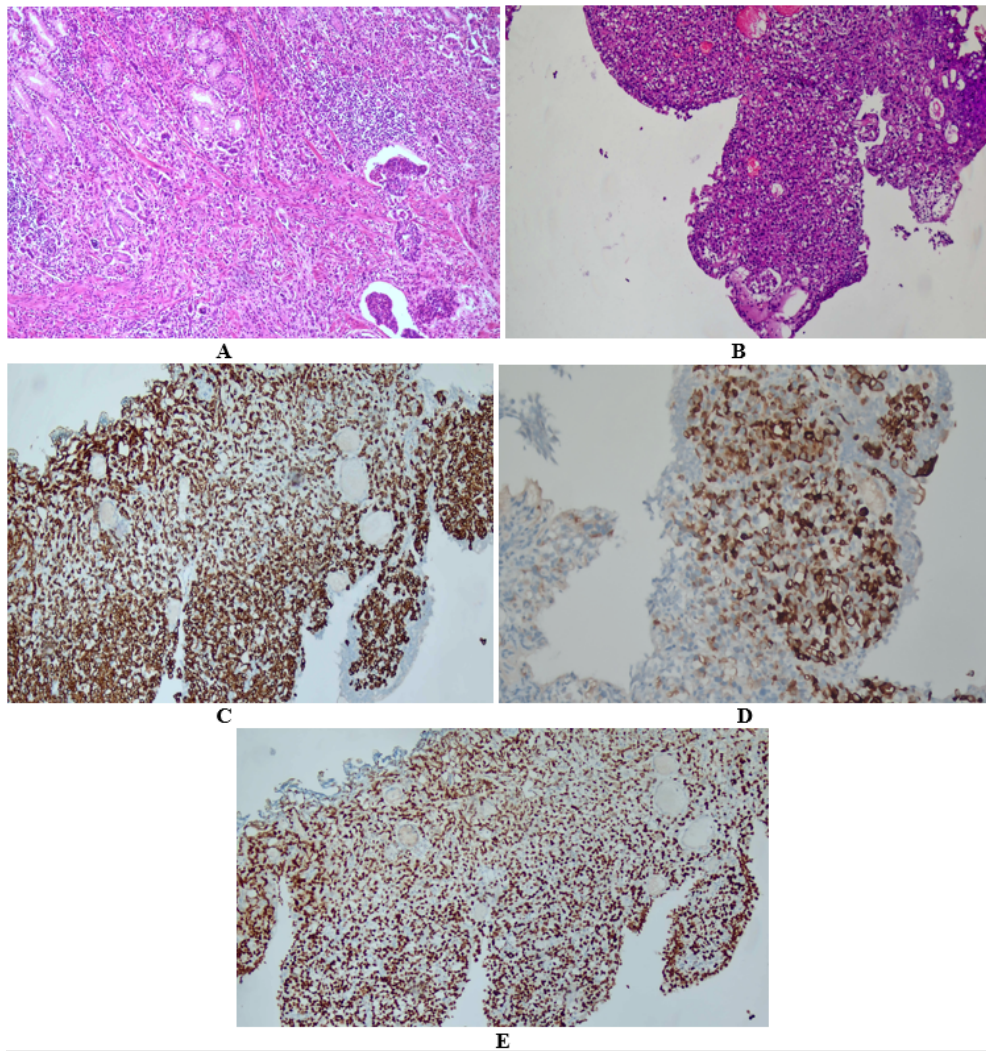


Figure 3: Immunohistochemical evaluations of patient specimens. Gastric adenocarcinoma(**A**), urothelial cancer(**B**), CK7 positivity(**C**), CK20 negativity(**D**), GATA3 negativity(**E**).

Discussion

More than 95% of the bladder tumors are reportedly transitional cell carcinoma. The remaining 4% of the bladder tumors include adenocarcinoma, squamous cell carcinoma and other rare subtypes of bladder tumors. Secondary bladder tumors constitute less than 2% of all bladder tumors. Malignant tumors rarely metastasize to the urinary bladder. Most of the information on metastatic tumors of the bladder has been obtained from autopsy series. Primary tumors located in the prostate, colon, rectum or cervix can directly invade the bladder. Additionally, cancers such as melanoma and gastric and breast cancers can spread to the bladder through lymphatic, hematogenic or peritoneal dissemination [4,5]. In an analysis of 282 cases with secondary bladder tumors, Bate et al reported direct extension from the colon (21%), prostate (19%), rectum (12%), and cervix (11%) regions to the bladder. In the same series, it was reported that the gastric cancer (4.3%), melanoma (3.9%), lung cancer (2.8%) and breast cancer (2.5%) have metastasized to the bladder through lymphatic or hematogenous or peritoneal dissemination [3]. Gastric cancers frequently metastasize to liver (48%), peritoneum (32%), lung (15%), and bone (12%) [2]. There are also case reports in the literature of atypical metastasis sites of stomach cancer such as skin, testis, breast, cervix, and bladder [6]. There is a total of 20 case reports in the literature, including this case report, that reported bladder metastasis secondary to gastric cancer. The majority of these case reports are from Japan, which is not striking considering the high incidence of gastric cancer in Japan. Of these cases, 8 presented with hematuria, whereas the remaining cases presented with dysuria and hypogastric pain. Hydronephrosis was present in 9 cases. The average age of the cases was over 50 (min.: 38, max.: 90) years [7]. Synchronous bladder metastasis was noted during the diagnosis of primary gastric tumor in 5 cases only. In the remainder of the cases, bladder metastasis was observed after a median period of 24 months following the diagnosis of gastric cancer. In one of these cases, recurrence was observed in the bladder 10 years later [8]. Signet-ring cell carcinoma histology was observed in 12 of the cases. The treatment methods administered to these cases included systemic chemotherapy, transurethral resection (TUR) and partial cystectomy [9]. In comparison, the case presented herein presented with hematuria and hydronephrosis and bladder metastasis was observed 5 months after the diagnosis. As for the treatment method, he was performed TUR.

Histologically, the incidence of primary and secondary adenocarcinoma of the bladder are both less than 2%. Differentiation of primary and secondary bladder adenocarcinoma by histopathological and immunohistochemical evaluation is difficult, yet important in terms of making the right treatment choice. Radical cystectomy is preferred in the treatment of primary bladder adenocarcinoma, whereas systemic treatment is preferred in the treatment of secondary adenocarcinoma [10]. It

was reported in previous studies that polypoid formation or the presence of Brunner's nests in the tumor and glandular or mucous metaplasia in the mucosa and the presence of epithelial cell foci suggest primary origin. Immunohistochemical studies may help in the interpretation of the morphological findings. CK7 and CK20 were found to be positive in 73% and 82% of the cases with primary bladder tumors, respectively. In one of the cases, where both CK7 and CK20 were positive and CDX2 was negative, a primary bladder tumor was considered. Colorectal cancer was considered in cases where both CK7 and CDX2 were negative and CK20 was positive. Lastly, gastric cancer was considered in cases where both CK7 and CDX2 were positive and CK20 was negative [11]. GATA-3 immunohistochemical marker is generally positive in bladder and breast adenocarcinoma, and negative in gastric adenocarcinoma [12]. In comparison, the immunohistochemical studies revealed that the CK7, CDX2, CEA and p53 were positive whereas CK20 and GATA-3 were negative in the case presented herein. These findings suggested gastric cancer for the primary tumor, CK7, CDX2 and CEA positivity suggested gastric cancer. On the other hand, primary bladder adenocarcinoma was ruled out based on GATA-3 and CK20 negativity. In conclusion, as in the case presented herein, gastric cancer can metastasize to unexpected sites in the body. Metastasis of gastric cancer to the bladder is very rare, but should be considered if the patient presents with a symptom such as hematuria. The prognosis of bladder metastasis from gastric cancer is poor and thus a multidisciplinary approach should be adopted in its management.

References

1. Smyth EC, Nilsson M, Grabsch HI, van Grieken NC, Lordick F (2020) Gastric cancer. *Lancet* 396:635-648.
2. Riihimäki M, Hemminki A, Sundquist K, Sundquist J, Hemminki K (2016) Metastatic spread in patients with gastric cancer. *Oncotarget* 7:52307-52316.
3. Bates AW, Baithun SI (2000) Secondary neoplasms of the bladder are histological mimics of nontransitional cell primary tumours: clinicopathological and histological features of 282 cases. *Histopathology* 36:32-40.
4. Okutur K, Eren OO, Demir G (2015) Metastasis of Gastric Signet-Ring Cell Carcinoma to the Urinary Bladder: A Case Report and Review of the Literature. *Case Rep Oncol Med* 2015:127516.
5. Pirhan Y (2020) Analysis of Prognostic Factors Affecting Postoperative Survival in Stage III Gastric Cancer Patients. *Dicle Tıp Dergisi* 47:34-42.
6. Gülmez A, Dikilitas M (2020) A rare case Of gastric cancer: Isolated vaginal metastasis. *Curr Probl Cancer* 44:100566.
7. Matsushashi N, Yamaguchi K, Tamura T, Shimokawa K, Sugiyama Y, et al. (2005) Adenocarcinoma in bladder diverticulum, metastatic from gastric cancer. *World J Surg Oncol* 3:55.
8. András C, Tóth L, Pósán J (2013) Occurrence of bladder metastasis 10 years after surgical removal of a primary gastric cancer: a case report and review of the literature. *J Med Case Rep* 7:204.

Citation: Arak H, Teker F. (2022) A Gastric Adenocarcinoma Case Presenting with Hematuria. J Urol Ren Dis 07: 1267. DOI: 10.29011/2575-7903.001267.

9. Neves TR, Covita A, Soares M, Nogueira R, Lima MS, et al. (2011) Bladder metastasis of gastric adenocarcinoma. Report of 2 cases and bibliographic review. Arch Esp Urol 64:544-550.
10. Busto Martín LA, Janeiro Pais M, González Dacal J, Chantada Abal V, Busto Castañón L (2010) Signet-ring cell adenocarcinoma of the bladder: case series between 1990-2009. Arch Esp Urol 63:150-153.
11. Dadhania V, Czerniak B, Guo CC (2015) Adenocarcinoma of the urinary bladder. Am J Clin Exp Urol 3:51-63.
12. Ellis CL, Chang AG, Cimino-Mathews A, Argani P, Youssef RF, et al. (2013) GATA-3 immunohistochemistry in the differential diagnosis of adenocarcinoma of the urinary bladder. Am J Surg Pathol 37:1756-1760.