

Case Report

Ectopic Pancreas in Stomach: An Incidental Finding in A Trauma Patient, A Case Report with Review of Literature

Mamta Setia, Arulselvi Subramanian*, Prasenjit Das, Amit Gupta

Department of Lab Medicine, AIIMS Jai Prakash Narayan Apex Trauma Center, New Delhi, India

***Corresponding author:** Arulselvi Subramanian, Professor, Department of Lab Medicine, AIIMS Jai Prakash Narayan Apex Trauma Center, Ring Road, Sarojini Nagar, Raj Nagar, Safdarjung, New Delhi, Delhi 110029, India. Tel: +919868397275; Fax: +911126106826; Email: arulselvi.jpnatc@gmail.com

Citation: Setia M, Subramanian A, Das P, Gupta A (2018) Ectopic Pancreas in Stomach: An Incidental Finding in A Trauma Patient, A Case Report with Review of Literature. J Surg: JSUR-1109. DOI: 10.29011/2575-9760.001109

Received Date: 13 February, 2018; **Accepted Date:** 19 February, 2018; **Published Date:** 26 February, 2018

Abstract

Background: Ectopic pancreas is a rare condition with incidence of 0.5-13% in the general population. EP tissue can be found in any age and has male preponderance. Most common site of EP is upper gastrointestinal tract. Usually the patients are asymptomatic, but symptoms may develop depending upon the location and the size of the EP. In this case report, we describe incidentally detected EP in a trauma patient.

Case Report: We present the case of a 55 years old male patient presenting with melena, hematemesis and decreased urine output one day after trivial trauma. He had inter-trochanteric fracture of femur with post traumatic perforation peritonitis as diagnosed on X ray. Urgent Exploratory laparotomy was done for suspected perforation and multiple biopsies were taken on upper GI endoscopy. The biopsy specimen was examined histologically and Immunohistochemically concluding gastric ectopic pancreatic tissue with chronic pancreatic changes and ischemic mucosal ulceration with vascular thrombosis. It mimics many malignancies like Metastatic adenocarcinoma, gastrointestinal stromal tumor, gastrointestinal autonomic nerve tumor, lymphoma, etc so it was a diagnostic challenge in a trauma patient. The pancreatic focus was surgically excised and the postoperative and one year follow up of the patient remained uneventful. To our knowledge this is the first case report of an incidentally detected ectopic pancreatic tissue in a trauma patient. The diagnostic difficulties and the review of literature of EP are discussed here.

Conclusion: Although pancreatic heterotopia is rare, it should be always considered in the differential diagnosis of extra-mucosal gastric lesions.

Keywords: Ectopic Pancreas; Histopathology; Incidental

Introduction

Ectopic pancreas, also known as 'pancreatic choristoma, pancreatic rest or 'pancreatic acinar metaplasia' [1] refers to the presence of extra pancreatic tissue in unusual site, without any vascular or anatomical connection with the normal pancreas. EP can be seen in any age with male to female ratio of 3:1 [2]. It is found in approximately one in every 500-upper gastrointestinal surgical specimen [3]. Most common site of EP is upper gastrointestinal tract i.e. stomach (30 %), duodenum (25 %) and jejunum (15 %). Usually the patients are asymptomatic, rarely gastrointestinal bleeding, gastric outlet obstruction, gastric ulceration, pancreatitis, malignant degeneration and pseudocysts

[4]. may be the presentations. EP needs to be differentiated from malignancy, most commonly it mimics Gastrointestinal Stromal Tumour's (GISTs). In this case report, we describe incidentally found EP in a trauma patient.

Case Report

A 55 years old male patient presented with complaint of pain right side of hip and abdomen since 3 days, after a trivial trauma (fall in bathroom). There were 3 episodes of melena, one episode of hematemesis and decreased urine output since 2 days. On Physical examination, airways and circulation was normal with guarding and tenderness present in upper abdomen. His routine laboratory investigations including random blood sugar levels (61 mg/dl) were normal. He was previously diagnosed and treated

non-operatively for intertrochanteric fracture of right femur, in a primary health care centre. There was history of pain in right side of hip progressing to whole abdomen for which he was referred to AIIMS. No significant previous history of any co-morbidity. No history of alcohol abuse/smoking. On x ray examination, air under the diaphragm along with inter-trochanteric fracture of femur was observed leading to diagnosis of post traumatic perforation peritonitis. Upper GI endoscopy, showed normal stomach but oedematous and infiltrated duodenal mucosa at D1 D2 junction. CECT chest and abdomen showed subtle soft tissue density, thickening in distal body of stomach.

Omental fat density was increased. Urgent Exploratory laparotomy was done for suspected perforation. Multiple biopsies were taken along with Graham Patch Repair of the perforation. Later on, Mesh laparotomy was done to close the laparotomy wound. Post laparotomy patient developed bilateral pleural effusion with deranged coagulation profile and increased total WBC counts. After stabilizing the patient, CRIF with IL-IM NAIL was done for inter-trochanteric fracture femur. Histological examination of the biopsy specimen from gastric thickening showed gastric antral pyloric mucosal fragment with superficial mucosal ischemic ulceration (Figure 1) and mild chronic inflammation.

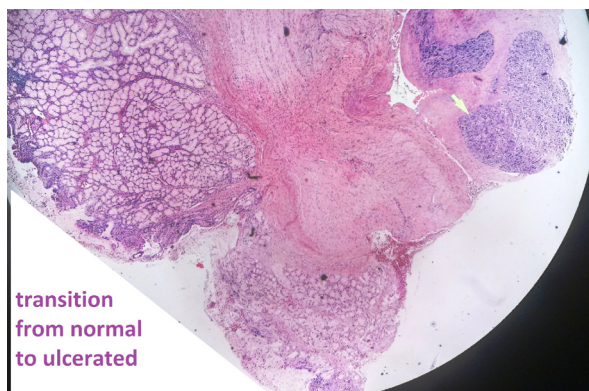


Figure 1: H&E, (4xs) Gastric layers with focal ulcerated mucosa; pancreatic tissue (P) in the muscular layer (with arrow);

In deeper part of the biopsy, in the muscularis propria and subserosa, organised collection of ducts and acini were noted, (Figure 2) with periductal fibrosis and necrosis of the part of adjacent wall.

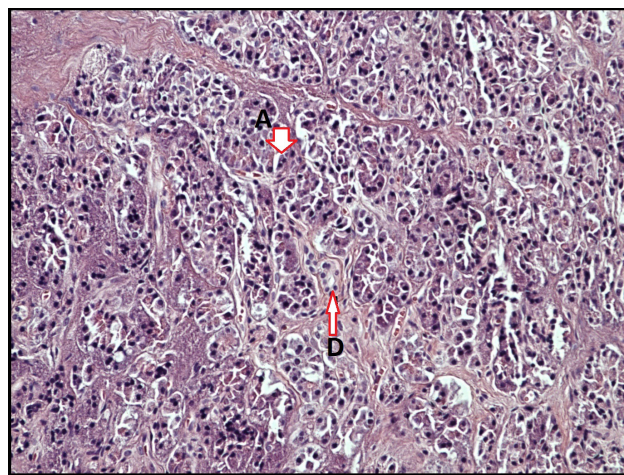


Figure 2: (H&E, 40 X) A: Acini, D: Pancreatic Duct. Higher magnification of pancreatic tissue in the gastric Muscular layer.

Vascular thrombus was also noted in the adjacent area. Because of the presence of ducts and acini in the muscle layer, the lesion was initially suspected to be adenocarcinoma, but no primary lesion was found on PET scanning. Immunohistochemically, the described ducts were found immune positive for cytokeratin, negative for chromogranin and Ki 67 labelling index was also extremely low. On reviewing the case again, the ducts were concluded to be pancreatic in origin. Concluding that gastric pancreatic heterotopias with chronic pancreatic changes and ischemic mucosal ulceration with vascular thrombosis was observed. The ectopic pancreatic focus was removed with uneventful postoperative and one year follow up period.

Discussion

Ectopic pancreas was first described in 1727 by Schultz in an ileal diverticulum and histologically confirmed by Klob [3] in 1859. Incidence of Ectopic pancreas in the general population is 0.5-13%, at autopsy 0.55-14 % and at necropsies is 0.6-13 % [3]. EP tissue can be found in any age and has male preponderance [4]. The incidence in the paediatric age group varies from 6 to 16% [5]. Most common site of EP is upper gastrointestinal tract i.e. stomach (30 %), duodenum (25 %) and jejunum (15 %), rarely it is found in hepatobiliary organs such as liver, gallbladder, common bile duct, cystic duct [3], Intracranially [6] or as umbilical mass [7]. Less

common sites involved are oesophagus, papilla of Vater, Meckel's diverticulum, mesocolon, mesentery, spleen, mediastinum and the fallopian tubes [5]. There are reports that EP has caused gastric outlet obstruction in infants [8] or children [9] and in an adult woman [4].

Symptoms

Usually the patients are asymptomatic, but when symptomatic most cases of ectopic pancreas in stomach present with symptoms like chronic or recurrent epigastric pain [3,7,10] severe dyspeptic symptoms [11] or nausea and vomiting [12]. Lesions greater than 1.5 cm in diameter are more likely to cause symptoms [13]. Pain is one of the most common symptoms. The possible explanation is that the pain is due to hormones and enzymes secreted by heterotopic pancreatic tissue, causing inflammation or chemical irritation of the involved tissues [14]. Some have reported symptoms of carcinoid syndrome [15]. In the paediatric age group, Gastric outlet obstruction and intussusceptions are the most common clinical presentations [7]. It can be associated with oesophageal atresia, umbilical polyps, Meckel's diverticulum, malrotation, an annular pancreas, a choledochal cyst and extra hepatic biliary atresia [5]. In our case, patient had melena and hematemesis.

Site

Specifically, in the stomach, the involvement of sub mucosal layer, muscularis and subserosal layer is 73%, 17% and 10%, respectively [14]. In the stomach, >95% of lesions are found in the antrum and prepyloric region, mainly situated close to the greater curvature [3]. However, in the present case, the ectopic pancreas was located on the distal part of gastric body, a relatively uncommon location for this rare disorder in the stomach.

Diagnosis and Differential Diagnosis

Diagnosis of EP is a challenge, even with the modern diagnostic modalities. No specific method is defined for its diagnosis yet, so laparotomy is required [4,16,17] Other suggested diagnostic methods are endoscopic biopsies, Intraoperative frozen sections and Upper GI endoscopy. Endoscopic biopsies usually are superficial and non-diagnostic but positive biopsies can lead to diagnosis [14,18]. Intraoperative frozen sections rule out other differential diagnoses of heterotopic pancreas, such as metastatic adenocarcinoma, gastrointestinal stromal tumor, gastrointestinal autonomic nerve tumor, lymphoma, carcinoid tumor and other malignancies [5]. Upper GI endoscopy shows EP as a broad based umbilicated sub mucosal lesion [19] in about 50 % of the cases but was unremarkable in our case. Endoscopic ultrasonography with fine needle aspiration cytology from sub mucosal lesions has a sensitivity of 80 to 100% in diagnosing EP [5]. It is often impossible to distinguish gastric heterotopic pancreas from

primary or metastatic cancer [15] as in our case and misinterpret it as another sub mucosal tumor, such as a GIST or as another malignancy on endoscopic examination [20]. Macroscopically, EP consists of lobular white or yellow nodular tumour's about 1-4 cm in diameter [4,10] The mean size of EP is 1.52 cm in diameter (range 0.2-4 cm) [4,21]

Development

Several theories for development have been proposed. Most common are the 'theory of metaplasia,' the 'theory of misplacement' and the latest addition, the 'theory of abnormalities of notch signalling' [13,22]. One theory suggests migration of pancreatic cells during foetal development; another theory suggests pancreatic metaplasia of the endodermal tissues localized in the gastric sub mucosa [23], no definite cause has been known yet.

Complications

Various complications like Haemorrhage due to mucosal erosion, ulcer formation and perforation are reported in EP [13], especially when located in the small intestine. The same complication occurred in our patient. Due to mucosal ulceration, he had episodes of melena and hematemesis. Malignant transformation may rarely occur. Up to 15 cases have been reported so far [21, 24]. In order, to be described as arising from heterotopic pancreas, the diagnosis of a carcinoma should fulfil three criteria:

- The tumour must be located within or very close to the ectopic pancreatic tissue,
- Transition between pancreatic structures and carcinoma must be identified and
- The non-neoplastic pancreatic tissue must comprise fully developed acini and ducts [14, 21].

Types

Histologically, based on the classification devised by Von Heinrich et al in 1909 and the subsequent modification by Gaspar Fuentes et al in 1973, pancreatic heterotopia is divided into four types histologically by Von Heinrich et al in 1909. It was further modified by Gaspar Fuentes et al in 1973 [13].

- Type I shows typical pancreatic tissue with acini, ducts and islet cells, similar to the normal pancreas.
- Type II shows only pancreatic ducts, while
- Type III has only acinar tissue and
- Type IV (endocrine pancreas) has only islet cells.

In the present study, the lesion was of type I, with acinar cells, Islet cells and pancreatic ducts found in the specimen.

Treatment

The treatment of incidentally detected asymptomatic histologically verified gastric heterotopic pancreas is debatable, [15] some reports suggest surgical removal to prevent future complications [3,7]. Medical treatment is not effective for heterotopic pancreas, and surgical excision is the first and best choice. Surgical excision provides symptomatic relief and is recommended especially if diagnostic uncertainty remains. In our case, the pancreatic focus was removed as the patient had episodes of hematemesis and melena. Postoperative period and the one year follow up period in our patient remained un-eventful.

Conclusion

Although pancreatic heterotopia is rare, it should be always considered in the differential diagnosis of extra mucosal gastric lesions [14]. To our knowledge this is the first case report of an incidentally detected ectopic pancreatic tissue in a trauma patient (Table 1).

Year/Author	Age/Sex	Site	symptoms
2016/Subasinghe, et al. [3]	50/F	Gastric fundus	burning epigastric pain, loss of appetite and associated GORD
2015/LIN, et al. [13]	48/f	lesser curvature of the middle gastric body	recurrent epigastric pain
2016/De Simone B, et al. [11]	63/f	antro-pyloric region	Vomiting and dyspeptic symptoms.
2010/Gokhale, et al. [5]	48/f	gastric antrum	recurrent epigastric pain
2012/Trifan, et al. [12]	31/m	gastric antral region post wall	epigastric pain, nausea and postprandial vomiting, weight loss
2007/Christodoulidis, et al. [14]	40/f	gastric antrum to the posterior wall	recurrent episodes of epigastric pain, nausea and vomiting
2008/Jiang, et al. [4]	46/f	prepyloric posterior gastric wall	Chronic epigastric pain and recurrent vomiting after meal.
2012/Yueh-Tsung Lee, et al. [23]	44/f	gastric antrum	severe epigastric pain with radiation to the back

Table 1: Cases of ectopic pancreatic tissue in stomach reported in the English literature.

References

- Kanthan R, Senger JL, Chibbar R, Kanthan S (2015) Pancreatic heterotopia: masquerading as malignancy: a 15-year single institutional surgical pathology review JOP 16: 397-402.
- Mulholland KC, Wallace WD, Epanomeritakis E, Hall SR (2004) Pseudocyst formation in gastric ectopic pancreas. JOP 5: 498-501.
- Subasinghe D, Sivaganesh S, Perera N, Samarasekera DN (2016) Gastric fundal heterotopic pancreas mimicking a gastrointestinal stromal tumour (gist): a case report and a brief review. BMC Res Notes 9: 185.
- Jiang LX, Xu J, Wang XW, Zhou FR, Gao W, et al. (2008) Gastric outlet obstruction caused by heterotopic pancreas: a case report and a quick review. World J Gastroenterol 14: 6757-6759.
- Gokhale UA, Nanda A, Pillai R, Al-Layla D (2010) Heterotopic pancreas in the stomach: a case report and a brief review of the literature. JOP. J Pancreas 11: 255-257.
- Heller RS, Tsugu H, Nabeshima K, Madsen OD (2010) Intracranial ectopic pancreatic tissue. Islets 2: 65-71.
- Caberwal D, Kogan SJ, Levitt SB (1977) Ectopic pancreas presenting as an umbilical mass. J Pediatr Surg 12: 593-599.
- Ozcan C, Celik A, Guclu C, Balik E (2002) A rare cause of gastric outlet obstruction in the new born: pyloric ectopic pancreas. J Pediatr Surg 37: 119-120.
- Ertem D, Tutar E, Cam S, Ugras M, Pehlivanoglu E (2006) Severe gastric outlet obstruction in a child with ectopic pancreas: is there a role for *Helicobacter pylori*? J Pediatr Gastroenterol Nutr 43: 385-387.
- Mehra R, Pujahari AK, Jaiswal SS (2015) Duodenal heterotopic pancreatic tissue: a case report and literature review. Gastroenterol Rep (Oxf) 3: 262-265.
- De Simone B (2016) Antro-pyloric stenosis and ectopic pancreas carcinoma: what is this? Annals of Clinical Case Reports - Surgery 1: 1019.
- Trifan A, Târcoveanu E, Danciu M, Huțanășu C, Cojocariu C, et al. (2012) Gastric heterotopic pancreas: an unusual case and review of the literature. J Gastrointestin Liver Dis 21: 209-212.
- Lin M, Fu Y, Yu H, Huang J (2015) Gastric heterotopic pancreas masquerading as a stromal tumor: a case report. Oncology Letters 10: 2355-2358.
- Christodoulidis G, Zacharoulis D, Barbanis S, Katsogridakis E, Hatzitheofiou K (2007) Heterotopic pancreas in the stomach: a case report and literature review. World J Gastroenterol 13: 6098-6100.

15. Yuan Z, Chen J, Zheng Q, Huang XY, Yang Z, et al. (2009) Heterotopic pancreas in the gastrointestinal tract. *World J Gastroenterol* 15: 3701-3703.
16. Shi HQ, Zhang QY, Teng HL, Chen JC (2002) Heterotopic pancreas: report of 7 patients. *Hepatobiliary Pancreat Dis Int* 1: 299-301.
17. Mönig SP, Selzner M, Raab M, Eidt S (1996) Heterotopic pancreas: A difficult diagnosis. *Dig Dis Sci* 41: 1238-1240.
18. Osanai M, Miyokawa N, Tamaki T, Yonekawa M, Kawamura A, et al. (2001) Adenocarcinoma arising in gastric heterotopic pancreas: clinicopathological and immunohistochemical study with genetic analysis of a case. *Pathol Int* 51: 549-554.
19. Agale SV, Agale VG, Zode RR, Grover S, Joshi S (2009) Heterotopic pancreas involving stomach and duodenum. *J Assoc Physicians India* 57: 653-657.
20. Kim JY, Lee JM, Kim KW, Park HS, Choi JY, et al. (2009) Ectopic pancreas: CT findings with emphasis on differentiation from small gastrointestinal stromal tumor and leiomyoma. *Radiology* 252: 92-100.
21. Emerson L, Layfield LJ, Rohr LR, Dayton MT (2004) Adenocarcinoma arising in association with gastric heterotopic pancreas: a case report and review of the literature. *J Surg Oncol* 87: 53-57.
22. Artavanis-Tsakonas S, Rand MD, Lake RJ (1999) Notch signalling: cell fate control and signal integration in development. *Science* 284: 770-776.
23. Lee YT, Lin H, Guo JC, Yan SL, Hou HJ, et al. (2012) Laparoscopy-assisted billroth I gastrectomy for ectopic pancreas in the prepyloric region. *Case Rep Gastroenterol* 6: 712-719.
24. Eisenberger CF, Gocht A, Knoefel WT, Busch CB, Peiper M, et al. (2004) Heterotopic pancreas--clinical presentation and pathology with review of the literature. *Hepatogastroenterology* 51: 854-858.