

Case Report

A Combination of Hodgkin's Lymphoma and Tuberculosis occurred with Bilateral Malignant Pleural Effusions

Daniel Valchev^{1*}, Mitko Mitev², Evelin Obretenov¹, Dimitar Kostadinov³, Danail Petrov⁴

¹Department of Clinic Thoracic Surgery, Trakia University, Stara Zagora, Bulgaria

²Department of Diagnostic Imaging, Trakia University, Stara Zagora, Bulgaria

³Department of Bronchology, Medical University of Sofia, Bulgaria

⁴Department of Clinic Thoracic Surgery, Medical University of Sofia, Bulgaria

***Corresponding author:** Daniel Valchev, Department of Clinic Thoracic Surgery, Trakia University, Stara Zagora, Studentski Grad, Stara Zagora 6000, Bulgaria. Tel: +35942699202; Email: dg_valchev@abv.bg

Citation: Valchev D, Mitev M, Obretenov E, Kostadinov D, Petrov D (2018) A Combination of Hodgkin's Lymphoma and Tuberculosis occurred with Bilateral Malignant Pleural Effusions. Ann Case Rep: ACRT-169. DOI: 10.29011/2574-7754/100069

Received Date: 27 March, 2018; **Accepted Date:** 06 April, 2018; **Published Date:** 13 April, 2018

Abstract

Simultaneous occurrence of tuberculosis and lymphoma is a rare combination. A primary malignant disease such as Hodgkin's disease (HD) can cause inhibition of cell-mediated immunity, which predisposes to concomitant tuberculosis infection. A congenital and acquired immune deficiency, the presence of autoimmune diseases suggests the development of tuberculosis. There is a close link between infectious mononucleosis caused by the Epstein-Barr virus and the development of Hodgkin's disease. We are describing a patient, aged 52 with simultaneous occurrence of tuberculosis combined with Hodgkin's lymphoma in a single cervical lymph node material developed with bilateral malignant pleural effusions and ascites, as the Hodgkin's disease has been determined at IV stage according to the Ann Arbor criteria.

Keywords: Cervical Lymphadenopathy; Hodgkin's Lymphoma; Mediastinal Lymphadenopathy; Tuberculosis

Introduction

The Hodgkin's disease affects people of all ages. It is less common than non-Hodgkin's lymphoma. Hodgkin's lymphoma represents about 10% of all lymphomas. According to the American Cancer Society, around 9,000 new cases of Hodgkin's disease (HD) are diagnosed each year in the United States. The exact causes of Hodgkin's disease are unknown. Research has shown that the malignant process leading to Hodgkin's disease can be caused by a combination of environmental and genetic factors along with a sensitive immune system. Hodgkin's disease occurs most often in people aged 15 to 40 years (Especially at Age of 20) and in people over age of 55. Children and teenagers are diagnosed in about 10-15% of Hodgkin's disease cases. Hodgkin lymphoma occurs *lightly more often in males than in females*. Women with Hodgkin's disease appear to have a slightly lower risk of recurrence after treatment than men [1]. In tuberculosis, there is a combination of direct DNA damage, inhibition of apoptosis, and prolonged chronic

inflammation that can strengthen the mutagenesis of progeny cells, and these effects combined with strengthened angiogenesis can result in microenvironments that are highly beneficial for tumorigenesis. The synthesis of available evidence has allowed us to identify three different types of association between malignant diseases and tuberculosis: cancer development against the backdrop of a previous tuberculosis infection; the coexistence of tuberculosis and malignant diseases in the same patient and / or clinical test; and the diagnostic challenges arising from the multilateral presentations of these two disorders.

Clinical Case

We are describing a patient at the age of 52, who has been hospitalized in the *Thoracic Surgery Clinics* on 10.01.2018 having complaints of about 3-4 months. The said complaints are: fatigue, mild breathlessness, dry irritable cough, weight loss of over 10 kg, prolonged night sweats, fever up to 38.5°C, which after antipyretic reception fell to 37.1-37.2°C. About three weeks ago, he felt a swelling in the right cervical area. Data taken from the objective condition: impaired general condition. Neck -in the right cervical

area, at lower third part are palpated multiple enlarged with diameter about 2 cm lymph nodes in a common conglomerate.

Paraclinical characteristics: HGB-103 g/l, RBC-4.11 10¹²/l, HCT-0.33 l/l, WBC-15.28/10.9, PLT-383/10.9, CRP-122; total protein 62.4 g/l, albumin 28.4 g/l.

A surgical biopsy-extravasation of a cervical lymph node was performed. Pathohistological result: Tuberculosis combined with Hodgkin's lymphoma. Immunohistochemistry: Focuses of caesarean necrosis prevail, surrounded by a macrophage-epitheloid composition in the absence of classical multi-core giant cells. On the periphery of the necroses there is a proliferation with mixed composition comprising separate transformed large cells close to the H + RS / Reed-Sternberg / element, predominantly mononuclear and abundance of eosinophilic granulocytes.

Immunomarking: CD 20 (+) indicates a small composition scarcely presented, CD 30 (+) marks groups /strands/ of cells including larger transformed lymphoids, CD 15 (+) marks heterogeneous composition, CD 3 (+) marks a small composition with abundant presence, CD 68 (+) marks an abundance of presented composition, CD138 (+) marks single cells.

In (Figures 1,2,3) are shown patches of the path histological result.

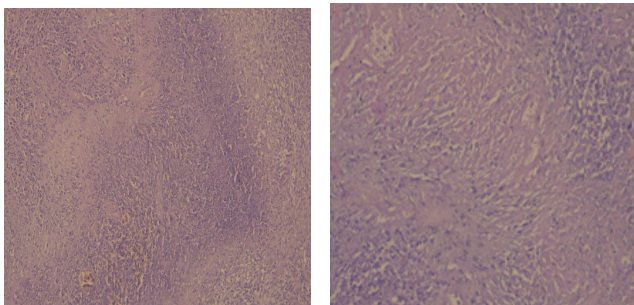


Figure 1: Increase of 100 times. **Figure 2:** Increase of 100 times.

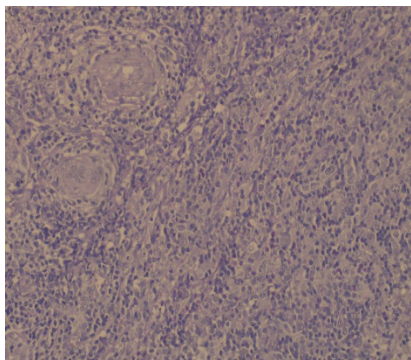


Figure 3: Increase of 200 times 2 giant cells visible.

In performed on January 18, 2018 Lung radiography - available data for bilateral pleural effusions, larger on the right. After performed

CT of chest and abdomen dated 22.01.2018. -available data for bilateral pleural effusions, more significant to the right, infiltrative outbreaks in the lung, right chest wall, spleen, left kidney, chiascal ascites, enlarged mediastinal, abdominal and axillary lymph nodes shown in (Figures 4,5,6,7,8).

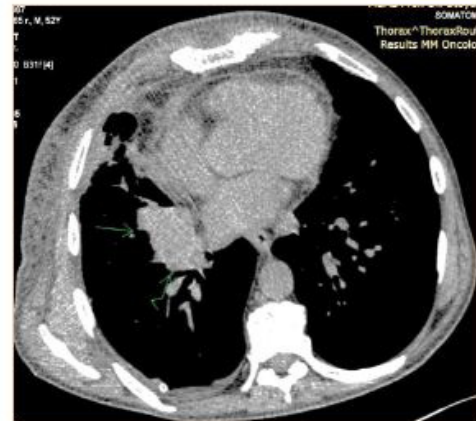

Figure 4: Infiltrative pulmonary Outbreak.

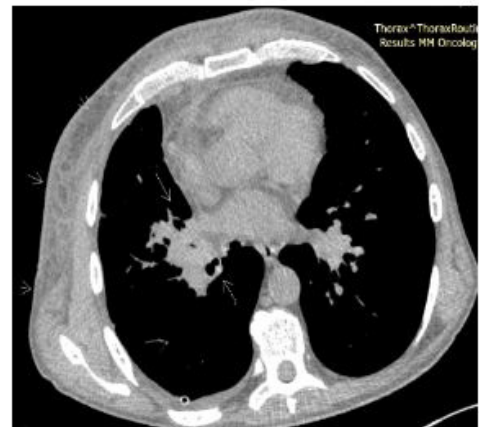

Figure 5: Infiltrative outbreak in the lung and the right side of the chest wall.

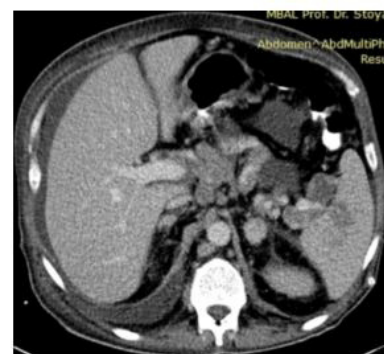


Figure 6: Infiltrative outbreak in the spleen.

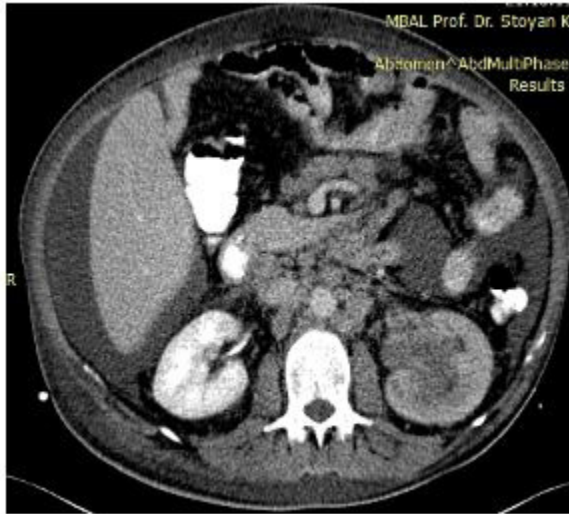


Figure 7: Ascites, infiltrative outbreak in left kidney and enlarged abdominal lymph nodes.

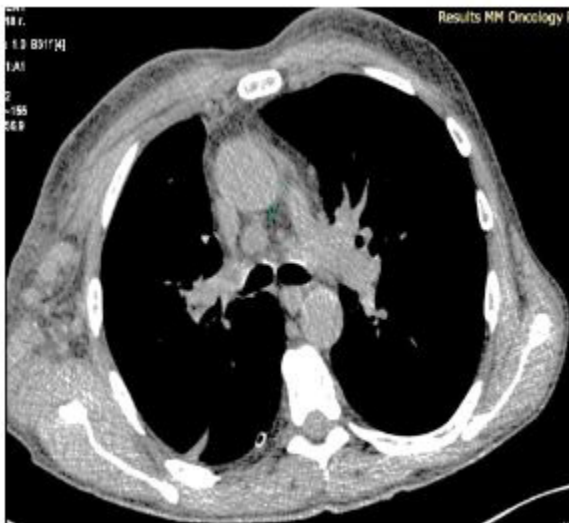


Figure 8: Increased mediastinal lymph nodes.

The lymphoma was staged in IV stage according to Ann Arbor criteria - widespread involvement of one or more extralymphatic organs, including any involvement of the liver, bone marrow, or nodular lung involvement. Two-sided thoracocentesis were performed with the insertion of pleural catheters. On the right was evacuated 1300 ml. pleural fluid having a lymph type. On the left 800 ml. yellowish clear pleural fluid. Biochemistry of pleural fluid from right pleural cavity: pH 7.0, Specific weight --1020, Rivalta (-) neg., Glucose - 3.41, Protein - 12.5 g/l, LDH - 136 U/L, Cell differentiation - presence of Er., Sg --70%, Eo - 1%, Ly -29%.

During the following days, due to the development of hypoproteinaemia and hypoalbuminemia - Total protein 51.7, albumin 22.1 and pleural fluid release in excess of 1000 ml / 24 h, it was not possible to perform pleurodesis. Human Albumin fl --100 ml therapy was started daily until correction of protein balance. Despite the replacement therapy, the total protein levels dropped to 41.1 g/l, albumin 17.0 g/l, and anemic syndrome continued to persist: HGB-96 g/l, RBC-3.52 10¹²/l, HCT-0.28 l / WBC-9.9 / 10⁹ > 9. At the same time was started an antitubercular quadruple scheme therapy: Tubocin 300 mg - 2 capsules morning, Ethambutol 400 mg - 2 tablets in the morning + 2 tablets evening, Isodinit 10 mg -3 tabs. morning, Pyrazinamide 500 mg - 2 tablets morning + 1 tabl. in the evening. Gradually, the overall condition has been improved and the patient was redirected to a specialized oncohematological center for chemotherapy and radiotherapy.

Discussion

Primary malignant disease, such as Hodgkin's lymphoma, may cause cell-mediated immune suppression, which predisposes to concomitant tuberculosis infection [2]. Immunosuppression is the main cause of mycobacterial infection in Hodgkin's disease, and tuberculosis is the main cause of death in these cases. Misdiagnosis or delay in the diagnosis of both tuberculosis and Hodgkin's disease may occur due to similar signs and symptoms such as cough, fever, loss of appetite, weight loss, night sweats, hepatosplenomegaly and mediastinal adenopathy. Whenever a patient is diagnosed with tuberculosis and his condition does not respond despite a regular treatment, should be then considered atypical mycobacteria, drug resistant tuberculosis, coexisting non-mycobacterial infections and malignancies [1]. Mycobacterial infections can lead to chronic persistent inflammatory process. There is sufficient evidence that *Mycobacterium tuberculosis* is capable of inducing damage to cellular DNA involved in inflammatory carcinogenesis [3]. Lymphadenitis is the most common form of extrapulmonary tuberculosis (TB) (5-10%), and in developing countries, its overall frequency is estimated to be approximately 40%. Approximately 90% of the cases include superficial lymph nodes in the head and neck area; generalized lymphadenopathy and hepatosplenomegaly are rarely described. The main histological features are: chronic granulomas, predominantly caesate necrosis, epithelial cell concentric layers, giant Langhans cells. The diagnosis of tuberculosis, however, must be confirmed by a positive laboratory test: a quantiferon test, a microbiological culture, or molecular tests (Mostly PCR Tests) [4]. The pleural effusions are a common symptom of Hodgkin's disease (HD). In 30% of patients with chest engagement of HD is registered a disturbed lymphatic drainage due to enlarged lymph nodes in the hilus or mediastinum, but it may also be due to direct involvement (Infiltration) of the pleura due to the tumor process. The lymph nodes are growing and coalesce in the vicinity, engaging the upper mediastinum. The pulmonary

parenchyma is affected in 38% of cases and is accompanied by mediastinal lymphadenopathy. Rarely the pleural effusion is the only manifestation of the disease, localized laterally on the internal thoracic wall and requiring a targeted CTK, puncture or thoracoscopic diagnosis.

Pathogenetically this is explained by obstruction of pleural lymphatic vessels, lymphostasis and effusion. The thoracoscopic drainage and the subsequent cytological examination of the pleural fluid are the most valuable means of diagnosis. As a rule, the pleural effusion is well-controlled by conventional chemotherapy [5]. The persistent release of pleural fluid over 500 ml / 24 hours for a longer period than 15 days did not allow a performance of chemical pleurodesis [6]. Moreover, the low pH-7.0 of the pleural fluid and the negative sample of Rivala combined with low quantity of glucose-3.41 and high LDH-136 U/L were identified as predictors of failed pleurodesis and low survival in malignant pleural effusions, despite the contestation as such by many authors [7-13]. The presence of pleural effusion due to lymphomas, primary or other, is considered to be one of the factors that adversely affects overall survival. The presence of pleural effusion during the presentation of lymphoma is not only associated with the extremely poor outcome of the disease but is also a predictor of relapse after chemotherapy and reduced survival, especially in cases of chest canal obstruction and disturbed lymphatic drainage, which is the primary mechanism for pathogenesis of pleural effusions in HD, and the direct pleural infiltration is predominant for NHL [14]. Often, in case of non-reaction to a drug therapy for one of the two diseases, the link between Hodgkin's lymphoma and tuberculosis should be discussed, especially in countries where the latter is endemic. Diagnosis may be difficult due to similarities in clinical picture, laboratory tests, and instrumental images [15].

Conclusion

The simultaneous development of Hodgkins lymphoma and tuberculosis is a serious condition where the two diseases mutually aggravate and quickly migrate to advanced stages. This requires a quick diagnosis process and timely combined treatment against both diseases. The only way for successful treatment is the close collaboration between surgeons, pathologists, oncohematologists and phthisiates (Pulmologists).

References

1. Reddy RC, Mathew M, Parameswaran A, Narasimhan R (2014) A case of concomitant Hodgkin's lymphoma with tuberculosis. *Lung India* 31: 59-62.

2. Mahajan K, Gupta G, Singh DP, Mahajan A (2016) Simultaneous occurrence of Hodgkin's disease and tubercular lymphadenitis in the same cervical lymph node: a rare presentation. *BMJ Case Rep*.
3. Falagas ME, Kouranos VD, Athanassa Z, Kopterides P (2010) Tuberculosis and malignancy. *QJM: An International Journal of Medicine* 103: 461-487.
4. Szumera-Ciećkiewicz A, Prochorec-Sobieszek M, Lech-Marañda E (2014) Quiz. Correct answer to the quiz. Check your diagnosisHodgkin's lymphoma mimicking tuberculosis in cervical lymph nodes. *Polish Journal of Pathology* 65: 83-88.
5. Kostov K, AzhderianS (2014) Pleural effusions in malignant hematopathies In *Spiro No.:* 1 (25) / March 2014, *Innovations in pulmonary diseases - 2013*.
6. Bertolaccini L, Viti A, Terzi A (2016) Management of malignant pleural effusions in patients with trapped lung with indwelling pleural catheter: how to do it. *J Vis Surg* 2: 44.
7. Muduly DK, Deo SVS, Subi TS, Kallianpur AA, Shukla NK (2011) An Update in the Management of Malignant Pleural Effusion. *Indian J Palliat Care* 17: 98-103.
8. Roberts ME, Neville E, Berrisford RG, Antunes G, Ali NJ (2010) Management of a malignant pleural effusion: British Thoracic Society Pleural Disease Guideline 2010. *Thorax* 65: 32-40.
9. Yoon D.W, Cho J.H, Choi Y.S, Kim J, Kim H.K, et al. (2016) Predictors of survival in patients who underwent video-assisted thoracic surgery talc pleurodesis for malignant pleural effusion. *Thoracic Cancer* 7: 393-398.
10. Zulkifli Amin, Stephen Diah Iskandar, Sibli (2017) Prognostic Factors of 30-day Survival of Patients with Malignant Pleural Effusion. *Indian J Palliat Care* 23: 321-324.
11. Heffner JE, Nietert PJ, Barbieri C (2000) Pleural fluid pH as a predictor of pleurodesis failure: analysis of primary data. *Chest* 117: 87-95.
12. Heffner JE, Nietert PJ, Barbieri C (2000) Pleural fluid pH as a predictor of survival for patients with malignant pleural effusions. *Chest* 117: 79-86.
13. Heffner JE, Heffner JN, Brown LK (2003) Multilevel and continuous pleural fluid pH likelihood ratios for evaluating malignant pleural effusions. *Chest* 123: 1887-1894.
14. Das DK (2006) Serous effusions in malignant lymphomas: a review. *Diagn Cytopathol* 34: 335-347.
15. Centkowski P, Sawczuk-Chabin J, Prochorec M, Warzocha K (2005) Hodgkin's lymphoma and tuberculosis coexistence in cervical lymph nodes. *Leuk Lymphoma* 46: 471-475.