



Case Report

Ectopic Breast Cancer Mimicking an Epidermal Inclusion Cyst: Case Report with Review of the Literature

Fantakis Antonios*, Toutziari Evdokia, Kolympa Georgia, Chatzikomnitsa Paraskevi, Alexandrou Dimitrios, Papadopoulos Vasileios

1st Department of Surgery, Aristotle University School of Medicine, Papageorgiou General Hospital of Thessaloniki, 56429 Ring Road N. Efkarpia, Thessaloniki, Greece

***Corresponding author:** Fantakis Antonios, 1st Department of Surgery, Aristotle University School of Medicine, Papageorgiou General Hospital of Thessaloniki, 56429 Ring Road N. Efkarpia, Thessaloniki, Greece

Citation: Antonios F, Evdokia T, Georgia K, Paraskevi C, Dimitrios A, et al (2025) Ectopic Breast Cancer Mimicking an Epidermal Inclusion Cyst: Case Report with Review of the Literature. Arch Surg Clin Case Rep 8: 247. DOI: 10.29011/2689-0526.100247

Received: 15 April 2025, **Accepted:** 21 April 2025, **Published:** 23 April 2025

Abstract

Ectopic breast cancer is a relatively rare entity, (0.3-0.6% of breast cancer), affecting mostly women. It usually appears along the milk lines, from the axilla to the groin, while it can be found in distant locations as well. A total of 299 cases have been reported. In this paper, a case of ectopic breast cancer of the axilla is reported, mimicking an epidermal inclusion cyst, initially treated with local resection, and almost being overlooked. After diagnosis was made, wide excision followed, with sentinel lymph node biopsy. Pathology revealed infiltrative ductal carcinoma of the breast, with site of in-situ ductal carcinoma. Ectopic breast cancer constitutes a challenging entity due to difficulty in diagnosis, which can be easily overlooked and therefore delayed, and the patients are usually diagnosed at a more advanced stage. Dealing with such cases is usually complex and should be performed at expert centers to achieve the best results.

Keywords: Breast Cancer; Ectopic Breast Cancer; Ectopic Breast Tissue; Axillary Cancer.

Introduction

Accessory breast tissue is present in 0.6-6% of the female population, and in 0.003-0.006% of the male population and can present all the pathological conditions that can affect it as an organ, as it can contain all the components of the normal breast tissue [1-5]. Breast cancer can occur in this type of tissue and represents 0.3-0.6% of all breast cancer cases and is characterized as ectopic breast cancer [2]. Due to delayed diagnosis, and even earlier metastasis to the regional lymph nodes, it tends to have worse prognosis than orthotopic breast cancer [6]. Additionally, higher rate of malignant transformation has been reported, with stagnation in the ductal lumen being a possible risk factor [4,7,8]. Such tumors are usually found along the milk line, from axilla to groin, but can also be found in other areas such as vulva, thighs, anus and even face, with

axilla being the most common site [1,9,10].

Diagnosis can be challenging as symptoms are not typical, and the locations of these tissues are not included in routine mammography and ultrasound [11]. Additionally, the development of breast cancer in ectopic breast tissue in the axilla can make the differential diagnosis between tumor and other benign pathologies such as enlarged lymph nodes, abscesses, lipomas, etc very difficult, which can lead to delay in diagnosis and treatment [2,12,13].

Case Report

A 58-year-old Caucasian woman, with insignificant medical and surgical history, visited our Surgical outpatient department for regular screening examination. Clinical examination revealed a palpable epidermal inclusion cyst-like mass of the right axilla, which was already scheduled for excision elsewhere. Mammography revealed a nodule of the upper left quadrant of the left breast with benign characteristics and without alterations in comparison

to previous tests and bilateral axillary lymph nodes with benign characteristics. Further investigation with U/S was advised and re-evaluation with the results. The patient visited our outpatient department with the results of the excisional biopsy which revealed invasive ductal carcinoma, suggestive of ectopic breast cancer of the right axilla. Immunohistochemical evaluation had not been performed. The patient was admitted for further investigation with magnetic resonance mammography which did not reveal any significant findings. The specimen was re-evaluated confirming a grade 2 ductal carcinoma, while immunohistochemical report was positive for estrogen (ER) and progesterone (PR) receptors, and negative for human epidermal growth factor (HER-2), with 20% Ki-67 proliferation index.

The patient underwent additional excision for clear margin resection and axillary sentinel lymph node biopsy, after discussion in the Tumor Board Meeting. Initially the patient underwent pre-operative lymphoscintigraphy with technetium-99mTc Sulphur colloid injection around the nipple. Intraoperatively, an elliptical incision on the right axilla was performed, including the scar of the previous operation, and the tissue surrounding the previous tumor was removed. With the use of a gamma-probe and LigaSure™ exact dissector, one sentinel lymph node was identified and removed (a). Additionally, a palpable lesion near the skin was identified, which was considered suspicious for infiltration, and was also removed (b), along with the scar tissue surrounding the previous excisional site (c). The 3 specimens were sent for histopathology examination which revealed: a) breast tissue with in-situ ductal carcinoma (DCIS), 1.9cm in diameter, b) breast tissue within the subcutaneous area, in which grade 1 infiltrating ductal carcinoma and DCIS were identified with perineural invasion, and c) scar tissue with site of DCIS and infiltrative ductal carcinoma on the side of the tumor, resected in clear margins. Immunohistochemistry revealed diffuse positivity in ER and PR (more than 90%), negative Her-2 receptors, and 20-30% Ki-67 proliferation index. Margins were positive.

The case was discussed again in the Tumor Board Meeting for

further treatment planning. The patient underwent radiation of the breast with radiation boost at the axilla, along with oral hormone therapy medication (letrozole 2.5mg QD). The patient is currently under follow in the outpatient department.

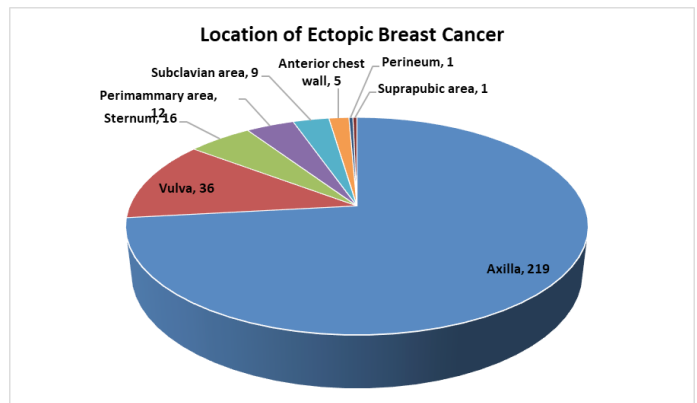


Figure 1: Distribution of ectopic breast cancer location.

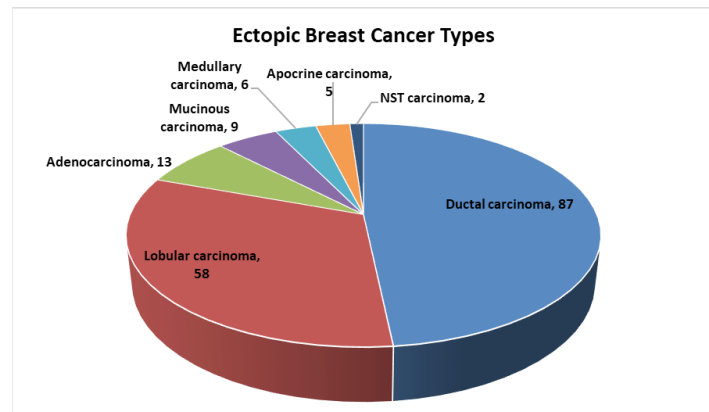


Figure 2: Distribution of histopathologic type of cancer, among patients with ectopic breast cancer. NST Non-specific type carcinoma.

Citation: Antonios F, Evdokia T, Georgia K, Paraskevi C, Dimitrios A, et al (2025) Ectopic Breast Cancer Mimicking an Epidermal Inclusion Cyst: Case Report with Review of the Literature. Arch Surg Clin Case Rep 8: 247. DOI: 10.29011/2689-0526.100247

Author	Year	Gender	Age	Location	Type	ER	PR	Her2
Greene et al [14]	1936	Female	59	Labia majora	Adeno-Ca	NA	NA	NA
Hendrix et al [15]	1956	Female	58	Labia majora	Adeno-Ca	NA	NA	NA
Guerry et al [16]	1976	Female	62	Labia majora	Ductal	NA	NA	NA
Guercio et al [17]	1984	Female	49	Labia majora	NA	NA	NA	NA
Cho et al [18]	1985	Female	60	Labia majora	Adeno-Ca	+	+	NA
Simon et al [19]	1988	Female	60	Labia majora	Adeno-Ca	+	+	NA
Rose et al [20]	1990	Female	68	Labia majora	Ductal	+	-	NA
Di Bonito et al [21]	1992	Female	46	Labia majora	NA	NA	NA	NA
Bailey et al [22]	1993	Female	65	Labia majora	Ductal	+	+	NA
Marshall et al [8]	1994	Female	52	Supernumerary nipple (below breast)	Lobular	NA	NA	NA
Levin et al [23]	1995	Female	62	Paraclitoral	Adeno-Ca	+	-	+
Evans et al [24]	1995	NA	NA	64 axilla 15 sternum 9 subclavian 2 labial	NA	NA	NA	NA
Kennedy et al [25]	1997	Female	NA	Labia majora	NA	-	-	NA
Irvin et al [26]	1999	Female	64	Lateral mons pubis	Adeno-Ca	+	+	NA
Gorisek et al [27]	2000	Female	81	Labia majora	Adeno-Ca	+	+	NA
Neumann et al [28]	2000	Female	81	Labia majora	Lobular	+	+	NA
Piura et al [29]	2002	Female	69	Labia majora	Adeno-Ca	+	+	NA
Chung-Park et al [30]	2002	Female	47	Labia minora	Mucinous	+	+	-
Roorda et al [31]	2002	Female	70	Inframammary	Ductal	+	+	NA
Yin et al [32]	2003	Female	84	Above clitoris	Mucinous	+	+	-
Giron et al [2]	2004	Female	65	Axilla	Lobular	+	+	NA
Fracchioli et al [33]	2006	Female	57	Vulva	Adeno-Ca	-	NA	NA
Lopes et al [34]	2006	Female	44	Vulva	Mucinous	+	NA	-
Van Herwaarden-Lindeboom et al [35]	2007	Female	46	Anterior chest wall	Lobular	+	+	*
North et al [36]	2007	Female	49	Paraclitoral	Ductal	+	+	-
Martinez-Palones et al [37]	2007	Female	49	Labia majora	Ductal	+	+	NA
Toman et al [38]	2008	Female	57	Perimammary	Lobular	+	+	+
Ogino et al [39]	2010	Female	70	Inframammary	Ductal	+	+	-
Naseer et al [40]	2011	Female	57	Labia majora	Ductal	+	+	-
Nihon-Yanagi et al [41]	2011	89 females	NA	86 axilla	52 ductal	NA	NA	NA
					Medullary 5	NA	NA	NA
				7 anterior chest wall	Mucinous 5	NA	NA	NA
		5 males	NA		Apocrine 4	NA	NA	NA
				1 NA	Lobular 2	NA	NA	NA
					NA 26	NA	NA	NA
Diniz da Costa et al [42]	2012	Female	82	Labia minora	Ductal	+	+	NA
McMaster et al [43]	2013	Female	60	Labia majora	Ductal	+	NA	NA

Citation: Antonios F, Evdokia T, Georgia K, Paraskevi C, Dimitrios A, et al (2025) Ectopic Breast Cancer Mimicking an Epidermal Inclusion Cyst: Case Report with Review of the Literature. Arch Surg Clin Case Rep 8: 247. DOI: 10.29011/2689-0526.100247

Bogani et al [44]	2013	Female	71	Labia majora	Ductal	+	+	NA
Lamb et al [45]	2013	Female	59	Labia majora	Adeno-Ca	+	+	-
Francone et al [6]	2013	Female	43	Anterior chest wall	Ductal	+	+	NA
Onel et al [46]	2013	Female	41	Inframammary	Lobular	+	+	+
Devine et al [12]	2013	Female	61	Axilla	Lobular	+	+	NA
Wysokinska et al [47]	2014	Female	82	Chest wall	Ductal	+	+	-
Xu et al [48]	2014	Female	59	Sternum	Adeno-Ca	-	-	-
Samanta et al [49]	2015	Male	60	Infraclavicular	Ductal	+	+	-
Cripe et al [50]	2015	Female	62	Labia majora	NA	NA	NA	NA
Zhang et al [13]	2015	11 females	NA	11 Axilla	8 ductal	NA	NA	NA
					3 lobular	NA	NA	NA
James et al [51]	2016	Female	72	Vulva	Ductal	+	+	-
Alavifard et al [52]	2016	Female	24	Axilla	Ductal	NA	NA	NA
Fama et al [53]	2016	Female	NA	Axilla	Lobular	+	+	NA
		Female		Axilla	Apocrine	NA	NA	NA
		Female		Axilla	Ductal	-	-	NA
		Female		Anterior chest	Ductal	+	+	NA
Eom et al [4]	2017	Male	70	Perineum	NST	+	+	-
Ishigaki et al [54]	2017	Female	72	Vulva	Ductal	+	+	-
Loh et al [55]	2017	Female	47	Inguinal – labia majora	NST	+	+	-
Soto et al [56]	2017	42 females	NA	Axilla	Lobular	+	+	NA
Sindoni et al [57]	2018	Female	NA	Axilla	Ductal	-	-	-
Lopes et al [65]	2018	Female	58	Vulva	Adeno-Ca	+	NA	+
Aramin et al [59]	2019	Female	43	Vulva	Ductal	+	+	+
Matak et al [60]	2019	Female	60	Vulva	Lobular	NA	+	NA
Peil et al [61]	2020	Male	81	Axilla	Adeno-Ca	-	-	-
Addae et al [11]	2021	Female	60	Axilla	Ductal	+	+	-
Byon et al [9]	2021	Male	65	Suprapubic	Ductal	+	+	-
Sghaier et al [62]	2021	Female	60	Axilla	Lobular	+	+	NA
		Female	48	Axilla	Ductal	+	+	-
		Female	53	Axilla	Ductal	-	-	+
		Female	60	Axilla	Ductal	+	+	-
		Female	33	Axilla	Medullary	-	-	-
Harris et al [63]	2022	Female	72	Axilla	Lobular	+	-	+
Toshima et al [64]	2024	Female	65	Axilla	Ductal	+	-	+
Current	2025	Female	58	Axilla	Ductal	+	+	-

Discussion

A thorough literature review revealed 299 cases of ectopic breast cancer (Table 1). Most of the cases (97%) presented in women, from 24 to 84 years old, with a mean age of 59 years old at time of diagnosis, while men constituted the rest 3%, with a mean age of 69 and a range from 60 to 81 years old at time of diagnosis. The most common site of ectopic breast cancer was the axilla, representing 73.24% of the cases, followed by vulva, sternum, perimammary area, subclavian area, anterior chest wall, perineum, and suprapubic area (Figure 1). The most common histological type of cancer was invasive ductal carcinoma (48.60%), followed by invasive lobular carcinoma (32.40%), adenocarcinoma, mucinous carcinoma, medullary carcinoma, apocrine carcinoma, and non-specific type carcinoma (Figure 2). Out of 53 patients with available immunohistochemistry data, 46 were positive for ER/PR receptors (86.79%), while 8 out of 30 patients had positive Her-2 receptors (26.67%) [2,4,6,8,9,11-64].

Ectopic breast tissue represents an unusual entity and the development of cancer at these sites is even rarer, constituting a problem that is easily overlooked. Most of the patients develop cancer along the milk lines which can aid to the diagnosis. Breast tissue can appear however in other areas as well, highlighting the need for thorough examination and investigation of every suspicious lesion, as well as the need for histopathological examination of every lesion removed, even if they are suspected to be benign by clinical features.

In the current case, the patient was advised to undergo further investigation of the palpable lesion, despite the lesion having clinically benign characteristics. The patient however underwent excision in another hospital which could have led to miss-diagnosis with significant impact in her survival, if the lesion hadn't been examined microscopically.

Additionally, ectopic breast tissue can appear in more than one area and can be diffusely scattered within the area. As such, ectopic breast cancer could turn out to be more complex than initially thought to be. Therefore, such cases should be referred to organized breast cancer centers that deal with these entities and be closely monitored.

Acknowledgements: The publication of the manuscript was supported financially by Anastasios Mavrogenis S.A.

Ethics: This manuscript is in accordance with General Data Protection Regulation (GDPR). As this is a case report for a patient that underwent routine surgery, no ethics committee approval was required.

Conflict of interest: The authors declare that there is no conflict of interest.

References

1. DeFilippis, E.M. and E.K. Arleo, (2014) The ABCs of accessory breast tissue: basic information every radiologist should know. *AJR Am J Roentgenol*, 202: 1157-62.
2. Giron, G.L, I. Friedman, and Feldman S (2004) Lobular carcinoma in ectopic axillary breast tissue. *Am Surg*, 70: p. 312-5.
3. Patel, B.K, Jafarian N, Abbott AM, Khazai L, et al, (2015) Imaging Findings and Management of Primary Breast Cancer in Accessory Axillary Breast Tissue. *Clin Breast Cancer*, 15: e223-9.
4. Eom, H.J, Ko BS, Song IH, Gong G, Kim H (2017) Ectopic Male Breast Cancer in the Perineum: A Case Report. *J Breast Cancer*, 20: 404-407.
5. Zhong, G.B, Ye X, Liu JL, Xiao SZ, Huang Q, et al, (2018) Male accessory breast cancer on the abdominal wall: a case report and literature review. *Onco Targets Ther*, 11: 6625-6631.
6. Francone, E, Nathan MJ, Murelli F, Bruno MS, Traverso E, et al, (2013) Ectopic breast cancer: case report and review of the literature. *Aesthetic Plast Surg*, 3: 746-9.
7. Ghosn, S.H, K.A. Khatri, and J. Bhawan (2007) Bilateral aberrant axillary breast tissue mimicking lipomas: report of a case and review of the literature. *J Cutan Pathol*, 34: 9-13.
8. Marshall, M.B, Moynihan JJ, Frost A, Evans SR (1994) Ectopic breast cancer: case report and literature review. *Surg Oncol*, 3: 295-304.
9. Byon, J.H, An A, Shin JY, Choi EJ (2021) Ectopic Male Breast Cancer in Suprapubic Area That Relapsed with Hematogenous Metastasis. *J Breast Cancer*, 24: 344-348.
10. Chan, N.G, Penswick JL, Lebel E, Driman DK (2007) Ectopic breast tissue presenting as an anal polyp. *Can J Surg*, 50: E23-4.
11. Addae, J.K, Genuit T, Colletta J, Schilling K (2021) Case of second primary breast cancer in ectopic breast tissue and review of the literature. *BMJ Case Rep*, 14.
12. Devine, C, Courtney CA, Deb R, Agrawal A (2013) Invasive lobular carcinoma arising in accessory breast tissue. *World J Surg Oncol*, 11: 47.
13. Zhang, S, Yu Y, Qu W, Zhang Y, Li J (2015) Diagnosis and treatment of accessory breast cancer in 11 patients. *Oncol Lett*, 10:1783-1788.
14. Greene, H, (1935) Adenocarcinoma of supernumerary breasts of the labia majora in a case of epidermoid carcinoma of the vulva. *Am J Obstet Gynecol*, 31: 660-3.
15. Hendrix, R.C. and S.J. Behrman (1956) Adenocarcinoma arising in a supernumerary mammary gland in the vulva. *Obstet Gynecol*, 8: 238-41.
16. Guerry, R.L. and H.R. Pratt-Thomas (1976) Carcinoma of supernumerary breast of vulva with bilateral mammary cancer. *Cancer*, 38: 2570-4.
17. Guercio, E, et al, [Adenocarcinoma occurring in an aberrant mammary gland located in the vulva]. *Minerva Ginecol*, 36: 315-9.
18. Cho, D, Buscema J, RosenShein N, Woodruff JD (1985) Primary breast cancer of the vulva. *Obstet Gynecol*, 66: 79S-81S.
19. Simon, K.E, Dutcher JP, Runowicz CD, wiernet al (1988) Adenocarcinoma arising in vulvar breast tissue. *Cancer*, 62: 2234-8.

20. Rose, P.G, Roman LD, Reale FR, Tak WK, et al, (1990) Primary adenocarcinoma of the breast arising in the vulva. *Obstet Gynecol*, 76: 537-9.
21. Di Bonito, L, S. Patriarca, and G. Falconieri, (1992) Aggressive "breast-like" adenocarcinoma of vulva. *Pathol Res Pract*, 188: 211-4; discussion 214-6.
22. Bailey, C.L, Sankey HZ, Donoven JT, Beith KA, Otis CN, et al, (1993) Primary breast cancer of the vulva. *Gynecol Oncol*. 50: 379-83.
23. Levin, M, cathro HP, Grosh WW, Rice LW, Anderson WA (1995) Primary breast carcinoma of the vulva: a case report and review of the literature. *Gynecol Oncol*, 56: 448-51.
24. Evans, D.M. and D.P. Guyton, (1995) Carcinoma of the axillary breast. *J Surg Oncol*, 59: 190-5.
25. Kennedy, D.A, Hermina MS, Xanos ET, Schink JC, Hafez GR (1997) Infiltrating ductal carcinoma of the vulva. *Pathol Res Pract*, 193:723-6.
26. Irvin, W.P, Cathro HP, Grosh WW, Rice LW, Anderson WA (1999) Primary breast carcinoma of the vulva: a case report and literature review. *Gynecol Oncol*, 1999. 73: 155-9.
27. Gorisek, B, Zegura B, Kavalar R, But I, Krajnac I (2000) Primary breast cancer of the vulva: a case report and review of the literature. *Wien Klin Wochenschr*, 112: 855-8.
28. Neumann, I, Strauss HG, Buchmann J, Koelbl H (2000) Ectopic lobular breast cancer of the vulva. *Anticancer Res*, 20: 4805-8.
29. Piura, B, Gemer O, Rabinovich A, Inbar IY (2002) Primary breast carcinoma of the vulva: case report and review of literature. *Eur J Gynaecol Oncol*, 23: 21-4.
30. Chung-Park, M, Liu CZ, Giampeli EJ, Emery JD, Shalodi A (2002) Mucinous adenocarcinoma of ectopic breast tissue of the vulva. *Arch Pathol Lab Med*, 126: 1216-8.
31. Roorda, A.K, hansen JP, Rider JA, Huang S, Rider D (2002) Ectopic breast cancer: special treatment considerations in the postmenopausal patient. *Breast J*, 8: 286-9.
32. Yin, C, J. Chapman, and O. Tawfik, (2003) Invasive mucinous (colloid) adenocarcinoma of ectopic breast tissue in the vulva: a case report. *Breast J*, 9:113-5.
33. Fracchioli, S(2006) Primary "breast-like" cancer of the vulva: a case report and critical review of the literature. *Int J Gynecol Cancer*, 16 Suppl 1:423-8.
34. Lopes, G, DeCesare T, Ghurani G, Vincek V, Jorda M, et al (2006) Primary ectopic breast cancer presenting as a vulvar mass. *Clin Breast Cancer*, 7: 278-9.
35. van Herwaarden-Lindeboom, M.Y, R. van Hillegersberg, and P.J. van Diest, (2007) Ectopic lobular breast cancer on the anterior chest wall: a rare entity. *J Clin Pathol*, 60: 940-1.
36. North, J, Perez D, Fentiman G, Sykes P, Dempster A, et al (2007) Primary breast cancer of the vulva: case report and literature review. *Aust N Z J Obstet Gynaecol*, 47: 77-9.
37. Martinez-Palones, J.M, Benavante AP, Feijoo BD, Moreno AG, et al, (2007) Sentinel lymph node identification in a primary ductal carcinoma arising in the vulva. *Int J Gynecol Cancer*, 17: 471-7.
38. Toman, N, A. Buschmann, and T. Muehlberger, (2008) Ectopic breast cancer without breast parenchyma. *Breast*, 17: 3-4.
39. Ogino, T, Ishitobi M, Komokie Y, Motomura K, Koyama H, et al (2010) Ectopic breast cancer located in the anterior chest wall. *Breast J*, 16: 320-1.
40. Naseer, M.A, Mohammed SS, George SM, Majumdar SK (2013) Primary ectopic breast cancer mimicking as vulval malignancy. *J Obstet Gynaecol*, 31: 553-4.
41. Nihon-Yanagi, Y, Ueda T, Kameda N, Okazumi S (2011) A case of ectopic breast cancer with a literature review. *Surg Oncol*, 20:35-42.
42. Diniz da Costa, A.T, Coelho AM, Lourenco AV, Bernardino M, et al, Primary breast cancer of the vulva: a case report. *J Low Genit Tract Dis*, 2012. 16(2): p. 155-7.
43. McMaster, J, A. Dua, and S.C. Dowdy (2013) Primary breast adenocarcinoma in ectopic breast tissue in the vulva. *Case Rep Obstet Gynecol*, 2013: 721696.
44. Bogani, G, Uccella, Darus CJ, Skripenova S, Weisberg T, et al (2013) Primary mammary-like ductal carcinoma of the vulva: a case report and analysis of the literature. *Am J Dermatopathol*, 35: 685-7.
45. Lamb, A, et al, (2013) Association of primary breast cancer of the vulva with hereditary breast and ovarian cancer. *J Clin Oncol*, 31: e231-2.
46. Onel, S, et al (2013) Ectopic breast cancer: A case report. *Ulus Cerrahi Derg*, 29: 96-8.
47. Wysokinska, E. and G. Keeney, (2014) Breast Cancer Occuring in the Chest Wall: Rare Presentation of Ectopic Milk Line Breast Cancer. *J Clin Oncol*, 32: e35-e36.
48. Xu, X, Gu Y, Zhu C, Yu Z, Li N, et al (2015) Ectopic breast cancer in the anterior chest wall: a case report. *J Obstet Gynaecol*, 35: 652-3.
49. Samanta, D.R, Bose C, Upadhyay A, Sheet S, Senapathi S (2015) Ectopic Male Breast Cancer: A Case Report. *J Clin Diagn Res*, 9: XD08-XD10.
50. Cripe, J, R. Eskander, and K. Tewari (2015) Sentinel lymph node mapping of a breast cancer of the vulva: Case report and literature review. *World J Clin Oncol*, 6:16-21.
51. James, C, E. Ramez, and T. Krishnansu, (2015) Sentinel lymph node mapping of a breast cancer of the vulva: case report and literature review. *World J Clin Oncol*, 6: 16-21.
52. Alavifard, R, Kadkhodayan S, Shandiz H, Dabbagh V, Sadeghi R (2016) Is sentinel node mapping possible in surgically removed ectopic axillary breast cancer? A case report. *Nucl Med Rev Cent East Eur*, 19: 29-30.
53. Fama, F, Cicciu M, Sindoni A, Scarfo P, Polliciano A, et al (2016) Prevalence of Ectopic Breast Tissue and Tumor: A 20-Year Single Center Experience. *Clin Breast Cancer*, 16: e107-12.
54. Ishigaki, T, Toriumi Y, Nosaka R, Kudou R, Imawari Y, et al (2017) Primary ectopic breast cancer of the vulva, treated with local excision of the vulva and sentinel lymph node biopsy: a case report. *Surg Case Rep*, 3: 69.
55. Loh, Z, Yeo B, Williams D, Gyorki DE (2019) Ectopic breast cancer in the inguinal region. *Breast J*, 25: 155-156.

Citation: Antonios F, Evdokia T, Georgia K, Paraskevi C, Dimitrios A, et al (2025) Ectopic Breast Cancer Mimicking an Epidermal Inclusion Cyst: Case Report with Review of the Literature. Arch Surg Clin Case Rep 8: 247. DOI: 10.29011/2689-0526.100247

56. Soto, S, Toesca A, Hamza A, Corte GA, Lera M, Peradze N, et al (2017) Supernumerary Axillary Breast Cancer. *Breast J*, 23: 246-248.
57. Sindoni, A, M. Gioffre-Florio, and F. Fama (2019) Ectopic breast tissue and cancer. *Breast Cancer Res Treat*, 174: 551-552.
58. Lopes, A, St Louis J, Balancin ML, Rodrigues AN, Silva LCFF, et al (2017) A Rare Presentation of Primary Breast Carcinoma in the Vulva: A Case Report and Literature Review. *Clin Breast Cancer*, 18: e291-e294.
59. Aramin, H, Koirala P, Shah A, Adams K, Buza N, et al (2019) Metachronous vulvar ectopic breast cancer, a case report and literature review. *Gynecol Oncol Rep*, 30: 100515.
60. Matak, L, Dukic B, Tupek T, Sikic NL, Mikus M (2020) Primary ectopic lobular breast cancer of the vulva: case report and review of literature. *J Obstet Gynaecol*, 40: 727-730.
61. Peil, N, Varga Z, Barysch MJ, Brussow C, Dedes KJ (2020) Ectopic axillary breast cancer in a male patient. *Clin Case Rep*, 8: 2324-2325.
62. Sghaier, S, Ghalledb M, Marghli I, Bouida A, Hassouna JB, et al (2021) Primary ectopic axillary breast cancer: a case series. *J Med Case Rep*, 15: 412.
63. Harris, M.K, Guo MZ, Mangino A, Taylor C, Carson WE (2022) Sentinel node mapping and biopsy in ectopic axillary breast cancer: A case report and review of the literature. *Clin Case Rep*, 10: e6052.
64. Toshima, K, Shien T, Nishimura MF, Suzuki Y, Nakamoto S, et al (2024) Ectopic Breast Cancer Arising within an Axillary Lymph Node. *Acta Med Okayama*, 78: 89-93.
65. Lopes, A., St Louis J, Balancin ML, Rodrigues AN, Silva LCFF, et al (2018) A Rare Presentation of Primary Breast Carcinoma in the Vulva: A Case Report and Literature Review. *Clin Breast Cancer*, 18: e291-e294.