

## Supermicrosurgical Reimplantation of the Distal Half of the Index Finger

Ahmed Mokhtar Mahmoud Elbayer\*, Iqbal Wani

Plastic Surgeons, Qatar

\*Corresponding author: Ahmed Elbayer MD. MS, Plastic surgeon, Hamad Medical Corporation, Qatar. Email: dr.ahmedmokhtar84@gmail.com

Citation: Elbayer A, Wani I (2019) Supermicrosurgical Reimplantation of the Distal Half of the Index Finger. Plast Surg Mod Tech 4: 149. DOI: 10.29011/2577-1701.100049

Received Date: 16 September, 2019; Accepted Date: 04 October, 2019; Published Date: 10 October, 2019

### Abstract

Supermicrosurgical reimplantation is challenging. Successful reimplantations depend on many factors, for example, type of injury, level of injury, surgical setup, and teamwork. In this work, we will review a case of supermicrosurgery reimplantation for distal half of the index finger with full surgical details. Revascularization at this level is extremely challenging due to the small size of the vessels, plus the common impression among hand surgeons that these injuries are not re implantable.

Supermicrosurgery is defined as microsurgery in less than 0.8 mm vessels. It is an evolved form of microsurgery but with the same principle: (1) enhanced working environment including microscopes and finer instruments; (2) detailed preoperative evaluation and planning; (3) Supermicrosurgical technique; and (4) postoperative care. Supermicrosurgery now provides reconstructive solutions to address lymphedema, distal finger amputations, allows minimal invasive reconstruction using a perforator to perforator approach, and will eventually allow targeted customized reconstruction (1).

**Keywords:** Amputation; Artery; Bone; Cut; Complex; Digit; Digital; Distraction; External; Fixator; Fractures; Fracture; Fixation; Hand; Index; Joint; Joints; K Wire; K Wires; Kirschner Wire; Kirschner Wires; Long; Little; Middle; Metacarpal; Microsurgery; Machine; Plate; Prosthesis; Reduction; Reimplantations; Ring; Reimplantation; Thumb; Screws; Supermicrosurgery; Supermicrosurgery; Skin; Vein

### Abbreviations

K Wires: Kirschner Wires

### Introduction

Supermicrosurgery is defined as dissecting and anastomosing of vessels between .3-.8 mm. It needs proper setup and tools with a trained team to accomplish successful results. It differs from regular microsurgery in:

1-It's More non-forgiving for technical mistakes since it has done on a much smaller scale. 2-proper Handling of the vessels is crucial for successful results. 3-Proper magnification is needed, usually 40x magnification or more. 4-Proper setup involves Supermicrosurgery set (using regular microsurgery set is possible sometimes, but vessel dilatation using regular micro-vessel dilator is sometimes challenging.

### Case presentation

A 38-year-old male had a complete amputation of the distal half of his right index finger. He works as a baker. He got his injury by a bread cutting machine during his work. Presented to the hospital and operated within 4 hours from the injury time. Surgery length: 5-6 hours (Figure 1).

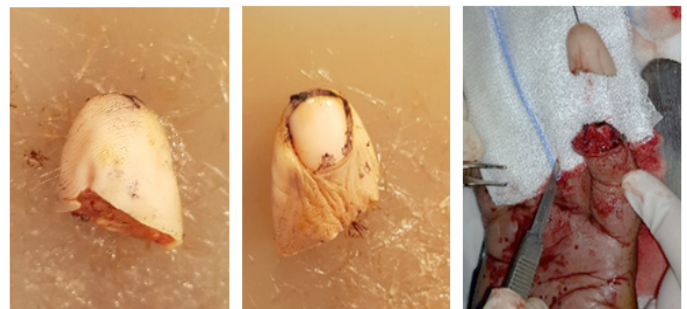


Figure 1: Pre-operative.

## Intraoperative Surgical Details

Preserving an amputated part done in the ER by wrapping the amputated part in Saline soaked gauze with placing it in a sterile ice container. In OR: carefully dissection for the Amputated part under the microscope. Careful dissection of the index finger under the microscope, the patient was under regional anesthesia. Trimming of the bone (few millimeters on each side done) and placing of vertical K Wire to fix the Amputated part, with x-ray to confirm. Ulnar digital artery anastomosis is done using 11-0 ethelon suture. Anastomosis of 1 vein done using 11/0 sutures. Skin approximating sutures taken at the end. The patient is placed on enoxaparin treatment dose post-op for ten days (Figures 2 and 3).

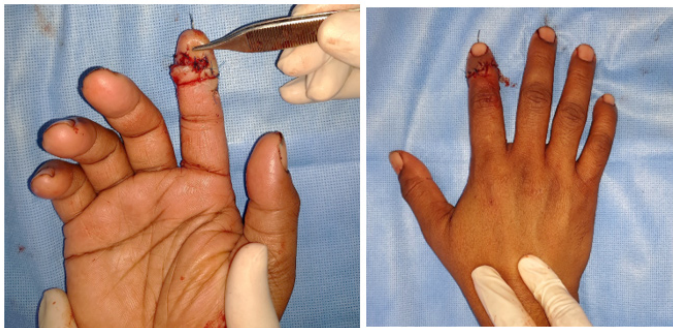


Figure 2: Post-operative picture.

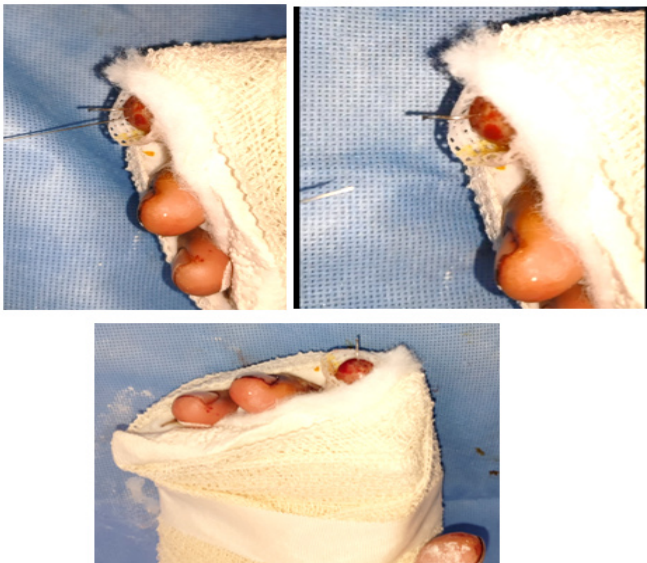

Figure 3: pricking test.

## Discussion

Successful Supermicrosurgery needs a systematic approach,

careful pre-operative preparation with proper setup and team. Vertical incision over the digital artery gives easier access and dissection. Tight suturing at the end might compromise blood supply (in this case, relieved by removing some sutures). Using micro bipolar cautery with low power is essential for dissection. Using micro Liga-clips is essential when ligation is indicated in proximity to the vessel. Triangulation technique is recommended to decrease mismatch in the size of the vessels if there is. Trimming of the bone using electrical saw (small blade) is essential. Patience, spending good time in preparations are two key points for successful results.

## Conclusion

Supermicrosurgery, a technique of dissection and anastomosis of small vessels ranging from 0.3 to 0.8 mm, has revolutionized the fields of lymphedema treatment and soft tissue reconstruction. The technique offers several distinct benefits to microsurgeons, including the ability to manipulate small vessels that were previously inaccessible. Thus, supermicrosurgery has become increasingly popular in recent years, and its applications have greatly expanded since it was first introduced 20 years ago. While supermicrosurgery was originally developed for procedures involving salvage of the digit tip, the technique is now routinely used in a wide variety of microsurgical cases, including lymphovenous anastomoses, vascularized lymph node transfers, and perforator-to-perforator anastomoses. With continued experimentation, standardization of supermicrosurgical training, and high-quality studies focusing on the outcomes of these novel procedures, supermicrosurgery can become a routine and valuable component of every microsurgeon's practice (2).

Supermicrosurgery is challenging. Following the right steps and taking enough time in preparation is the key to successful results. It's very important to have the right setup, right tools, and cooperative staff to have the time needed for good results. The learning curve will go up as far as we keep practicing and training without putting any psychological obstacles in front of us.

## Acknowledgment

I Thank Dr. JP Hong, my mentor, for inspiring me in my first Supermicrosurgery work.

## References

1. Hong JPJ, Song S, Suh HSP (2018) Supermicrosurgery: Principles and applications. *Surg Oncol* 118: 832-839.
2. Badash I, Gould DJ, Patel KM (2018) Supermicrosurgery: History, Applications, Training and the Future. *Front Surg* 5: 23.