

Results of Intrawound Antibiotic Vancomycin Powder in Preventing Postoperative Surgical Site Infection in Open Thoracic and Lumbar Surgery-A Prospective Randomized Study

Rushama Tandon*, Umang Savani

Department of Orthopedic Surgery, Northern Railway Central Hospital, New Delhi, India

*Corresponding author: Rushama Tandon, Department of Orthopedic Surgery, Northern Railway Central Hospital, New Delhi, India. Tel: +91-9810968883; Email: rushtan@rediffmail.com

Citation: Tandon R and Savani U (2019) Results of Intrawound Antibiotic Vancomycin Powder in Preventing Postoperative Surgical Site Infection in Open Thoracic and Lumbar Surgery-A Prospective Randomized Study. J Surg 11: 1217. DOI: 10.29011/2575-9760.001217

Received Date: 30 April, 2019; **Accepted Date:** 03 May, 2019; **Published Date:** 07 May, 2019

Introduction

Surgical site infections following spine surgery have significantly increased the mortality and morbidity of the patients and are a challenge to every surgeon [1,2]. Deep seated infections at the site of surgery cause significant patient morbidity and are a burden to our and health care system [3]. 20% of the 1.7 million hospital acquired infections in the United States of America were reportedly SSIs; approximately 2% of all operations result in SSI [4]. Of all the deaths, 77% are attributed to the infection at the operated site. Independent risk factors reported in the literature are geriatric age group, smoking, duration of the procedure, increased blood loss, increased levels of fusion in revision surgery, increased blood sugar levels and history of preceding SSI. The most common pathogens implicated in the causation of SSI include *Staphylococci*; *Enterobacteriaceae*, streptococcus, and enterococcus are second common pathogens [5]. A significant complication of instrumented spinal surgery is deep infection, which is reported to about 2.2%. This worsens the final clinical outcome as it is unexpected [6]. Antimicrobial Prophylactic Antimicrobials are routinely used for cases of orthopedic surgery with high risk which includes spinal instrumentation.

50% or even less prophylactic coverage of *Staphylococcus* organisms is given by IV Cephalosporins [7], IV vancomycin causes severe side effects like hypotension, kidney toxicity along with an inability to reduce the rate of SSI [8]. A high concentration of the antibiotic is achieved at the operated site by applying it locally, and systemic toxic effects are significantly reduced [9]. Thus, the antibiotics are able to reach the target site to prevent the occurrence of infection. Few studies have shown that locally applied vancomycin powder result in significant reduction in infection rate in instrumented as well as non-instrumented cases. In instrumented cases infection rate were 12% and significantly reduced after using

vancomycin powder locally to 0%. In non-instrumented cases infection rate were 10% and significantly reduced after using vancomycin powder locally to 0% [10]. In the single human study till date of prophylactically applied local antibiotics, vancomycin powder combined with systemic prophylactic antibiotics in elective spine surgery were effective in reducing rates of infection from 2.6% to 0.2%. Also, there were no reported adverse effects and radiographic results of both groups were the same [11]. Since the literature about locally applied Vancomycin after spine surgery is scant in the world and India, this study was undertaken in order to study the effect of local application of Vancomycin after both instrumented and un instrumented open Spine surgeries, in addition to standard intravenous (IV) & oral antibiotic prophylaxis

Materials and Methods

80 consecutive patients undergoing open thoracic, lumbar and thoracolumbar surgeries of the spine at Northern Railway Central Hospital from September 2014 to June 2016 were enrolled. Randomization into two groups was done using computer generated random numbers. Systemic antibiotic prophylaxis consisting of 1 g IV cefotaxime within 1 hour of surgical incision followed by 1 g IV cefotaxime every 8 hourly and 500 mg IV amikacin every 12 hourly for 1 day was given to all patients. Group A included the 40 consecutive open thoracic and lumbar spine surgery cases where additional vancomycin powder was used locally in the incision site; Group B included 40 consecutive patients in whom vancomycin powder was not used locally. Patients with a known history of previous spinal instrumented surgery, Infections at the surgical site, Infection at remote site, chronic infections, Uncontrolled diabetes, immunocompromised patients, Patients with previous or active spinal infection like Koch's spine or discitis and Anterior spinal surgery were excluded from the study.

All patients were prepared preoperatively with savlon followed by betadine and alcohol solution. Before closing the wound, Vancomycin powder at the rate of 500mg per level of surgery was applied directly to the tissues including muscle, deep fascia and subcutaneous tissues. Bone graft and dura mater are covered or protected before applying the antibiotic. The wounds were closed routinely with fascial and subcutaneous layers stitched with absorbable sutures and silk for the skin. After skin closure, the surgical incisions were cleaned again with betadine solution after skin closure, and a sterile dressing applied. A suction drain was applied in place for 48 hrs., and the dressing was checked on 2nd, 5th & 12th day. Age and gender of the patient, History of co-morbid conditions like diabetes etc., smoking time taken for surgery of each patient was obtained from the clinical chart reports. The Blood lost, Levels of fusion and duration of drain in situ were also recorded. Redness of skin, Edema at surgical incision, local rise of temperature, WBC count, ESR and CRP were evaluated on day 3,7 and 14 respectively. The incidence of SSI was recorded as the primary outcome of the study. SSI is classified into 2 types: deep SSI and superficial SSI. Culture results from the tip of the drain confirm deep infection, and the results of a swab cultured from discharge of the surgical wound confirmed Superficial infections. The treatment given accordingly for the cultured organisms was recorded when a SSI was confirmed. The patients were Follow up of patients for 3 months at 15 days, 1 month and 3 months was done.

Statistical Analysis

Statistical testing was conducted with the Statistical Package for the Social Services (version SPSS 20.0 The comparison of Normally distributed continuous variables were compared between groups using Student’s t test. Mann Whitney U test was used for Abnormal distribution continuous variables. Groups were compared for Nominal categorical data using Chi-squared test or Fisher’s exact test as required. In all the statistical tests, a p value of less than 0.05 was taken as significant.

Results

Age and gender of the patients showed no statistical difference The most common indication in both groups was PIVD (52.5% in Non-V group and 37.5%in V-group). About 57.5% of the study subjects had undergone non instrumented surgery. In vancomycin group, 57.5% had undergone non instrumented surgery. In non-Vancomycin group, 10% had red skin color on 2nd day, 15th day and 30th day and 10% had swelling and edema at the site of surgery during the follow up compared to vancomycin group. The surgical site had risen in local temperature in 10% of the cases of non-vancomycin group which was absent after 3 months of surgery. WBC count in both the groups showed no statistical difference. No studies were available to compare the results of this study. The

mean erythrocyte sedimentation rate and CRP in non-Vancomycin group and Vancomycin groups was higher just after surgery which reduced during the follow up (Table 1).

| Treatment | Non Vancomycin n (%) | Vancomycin n (%) |
|--|----------------------|------------------|
| Decompression with fixation | 9 (22.5) | 5 (12.5) |
| Decompression with fixation with bone graft | 2 (5.0) | 0 |
| Discectomy | 16 (40.0) | 10 (25.0) |
| Discectomy with fixation | 2 (5.0) | 4 (10.0) |
| Discectomy with ligamentum flavum excision | 1 (2.5) | 0 |
| Fixation | 1 (2.5) | 0 |
| Hemilaminectomy | 1 (2.5) | 1 (2.5) |
| Hemilaminectomy with fixation | 0 | 1 (2.5) |
| Intralaminar decompression with undercutting | 0 | 1 (2.5) |
| Laminectomy | 5 (12.5) | 6 (15.0) |
| Laminectomy with discectomy | 1 (2.5) | 4 (10.0) |
| Laminectomy with discectomy with fixation | 0 | 1 (2.5) |
| Laminectomy with fixation | 1 (2.5) | 6 (15.0) |
| Laminectomy with ligament flavum excision | 0 | 1 (2.5) |
| Total | 40 (100) | 40 (100) |

Table 1: Distribution of the study group according to treatment.

In non-Vancomycin group, Discectomy was the main operation performed in 40% of the cases followed by decompression with fixation (22.5%), and Laminectomy (12.5%), In Vancomycin group, discectomy was the common surgery in 25% of the patients followed by laminectomy in 15% of the cases and laminectomy with fixation in 15% of the cases (Table 2) (Figure 1).

| Culture at the time of drain removal from Drain tip | Non Vancomycin n (%) | Vancomycin n (%) |
|---|----------------------|------------------|
| Negative | 36 (90.0) | 40 (100) |
| Positive (<i>E. coli</i>) | 1 (2.5) | 0 |
| Positive (<i>Staph aureus</i>) | 3 (7.5) | |
| Total | 40 (100) | 40 (100) |

χ^2 Value= 4.211; df=2; p value=0.122, NS

Table 2: Distribution of the study group according to bacterial culture from the tip of the drain at the time of drain removal.

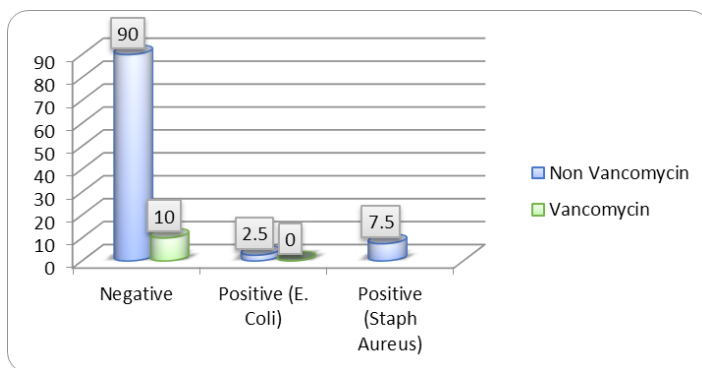


Figure 1: Distribution of the study group according to culture at the time of drain removal from drain tip.

The bacterial culture from the tip of the drain at the time of drain removal was negative in 90% of the study subjects who belonged to non-vancomycin group, 2.5% had positive culture for *E. coli* and 7.5% had positive culture for *Staph aureus*. In vancomycin group no organism was grown in the culture of the drain tip. Values are not statistically significant between the non-vancomycin and vancomycin groups as far as drain tip cultures are concerned (Table 3) (Figure 2).

| Bacterial Culture at the time of drain removal from skin wound | Non Vancomycin n (%) | Vancomycin n (%) |
|--|----------------------|------------------|
| Negative | 36 (90.0) | 40 (100) |
| Positive (<i>E. coli</i>) | 1 (2.5) | 0 |
| Positive (<i>Staph aureus</i>) | 3 (7.5) | |
| Total | 40 (100) | 40 (100) |

χ^2 Value= 4.211; df=2; p value=0.122, NS

Table 3: Distribution of the study group according to bacteria cultured at the time of drain removal from skin wound.

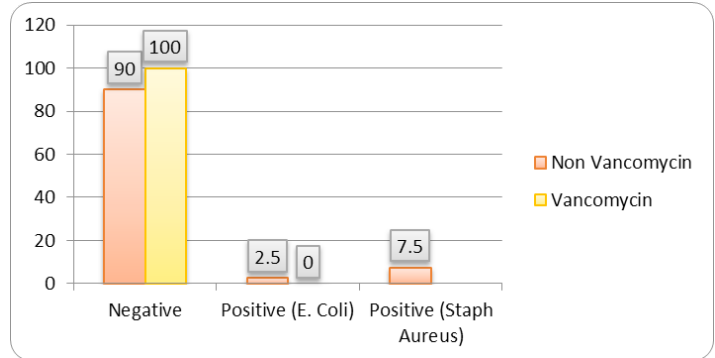


Figure 2: Distribution of the study group according to Bacterial culture at the time of drain removal from skin wound.

The bacterial culture at the time of drain removal from skin wound was negative in 90% of the non-vancomycin cases, positive for *E. coli* in 2.5% of the cases and Positive for *Staph aureus* in 7.5% of the cases. In Vancomycin group, all the patients had negative culture. There was no statistical difference in the culture from the skin wound between non vancomycin and vancomycin groups.

Discussion

Turnbull in 1953 was the first to describe Surgical site infections [11,12]. The incidence of SSIs reported after spine surgery ranges from 0.5 to 18.8% [13,14]. Surgeries of the spine following trauma account for the highest SSI rates, which is approximately 9.4% in one study, tumor surgeries and discitis also have higher infection rates. Surgical site infections may be further sub classified as either superficial or deep. Infections of the Skin and subdermal/subcutaneous layer without fascial involvement and confined to the skin are termed Superficial. Infections beneath the lumbodorsal fascia in posterior lumbar wounds or beneath the deep cervical fascia or the ligamentum nuchae in the cervical spine, discitis and epidural abscesses are classified as Deep. Infections can further be classified into acute or chronic depending on whether they occur before or 3 weeks after the procedure [15]. Higher rates of infection are seen in Extensive surgeries, long operative times [16,17], Instrumentation [18,19], posterior approach [1], extended preoperative hospitalization, larger number of levels to be fused, large volume blood loss, lumbosacral fusion, long duration surgery, tumor excisions, staged and revision procedures [17,20,21]. Imaging modalities like Plain radiography, CT scanning, and MR imaging are of limited value in an internally fixed spine X-rays can show implant loosening, CT bone destruction and Epidural abscesses can be detected by MRI only.

The sources of SSI are by direct inoculation of skin pathogenic bacteria at the time of incision [22], Incision

contamination in the postoperative phase [23] or hematogenous through systemic infection [24] as most post procedural infections occur by direct seeding antibiotics play a crucial role. The primary pathogens in acute infections are gram-positive cocci, specifically *Staphylococcus aureus*, *Staphylococcus epidermidis*, and β -hemolytic *Streptococci*. *S aureus* is the most common organism cultured from acute postoperative infections [1]. Gram negative organisms include *Klebsiella pneumoniae*, *Escherichia coli*, *Pseudomonas aeruginosa*, and *Proteus* [15]. *Propionibacterium acnes* [25] and diphtheroids cause chronic infections of low virulence, especially in intravenous drug abusers [1]. With the use of preoperative prophylactic antibiotics, Keller and Pappas [19] reported a dramatic decrease in infection rates from 2.7% to 0%. Preoperative prophylactic antibiotics brought down the infection rate after lumbar discectomies from 9.3% to 1% [26]. In 2011, Sweet, et al. in 2011, studied the pharmacological properties of Vancomycin and found no adverse local or systemic effects of the substance in wounds [11]; reduction in wound infections in their study was also statistically significant ($P < 0.0001$). O'Neil, et al. (2011) carried out a retrospective review of spinal trauma in 110 patients treated over a period of 2 years with instrumented posterior spine fusions. The difference in infection rates was between 0% in the treatment group vs up 13%, in the control group with a p value of p5.02 with no adverse effect [27]. Scheverin, et al. (2015), retrospectively studied patients with symptomatic lumbar spine stenosis and listhesis who were surgically treated with instrumented spinal fusion. The rate of infection for Vancomycin reduced the infection rate from 4.98% to 1.29% compared to the Control Group. They concluded that the use of vancomycin added to the bone graft in posterior spinal fusion is associated with significantly lower rates of infection [28] Various studies by Suh, et al. (2015), Dennis, et al. (2016) and Gonzalez Ross, et al. (2016) also concluded that the locally used vancomycin powder was safe and effective in preventing SSI.

In our study, 10% of patients in the non-Vancomycin group had positive cultures from the tip of the drain and the skin. In addition, these patients also had redness of skin, edema of the suture line and increased local temperature. *E. coli* was isolated in 2.5% cases and Staph. Aureus in 7.5% cases which indicates both superficial as well as deep infection. 2 patients had superficial stitch abscess which resolved with removal of the stitch and daily dressing. 3 patients developed deep infections which required debridement and resuturing of the wound. All 3 cases were internally fixed with pedicle screws for degenerative synthesis (2) and multilevel spinal canal stenosis (1) No patient developed discitis or epidural abscess. This difference in the two groups is statistically significant. In the Vancomycin group, no patient developed infection, either superficial or deep. There was not a single allergic or adverse reaction to the application of Vancomycin powder at the surgical site locally.

Conclusion

Our study reinforces the view of researchers that Vancomycin powder is safe and effective in Preventing SSI in open spine surgeries, both instrumented and non-instrumented. However, the sample size is small, and variables are limited as all procedures were performed by the same surgeon at a single Centre. There is no standardization or guideline in literature about the dose of Vancomycin to be used locally. We have used 500mg for single level and 1 gm for multilevel surgeries and quantifying level dependent or surgical procedure dependent doses needs further study.

References

1. Levi AD, Dickman CA, Sonntag VK (1997) Management of postoperative infections after spinal instrumentation. Journal of neurosurgery 86: 975-980.
2. Poelstra K, Vaccaro A, Albert T (2007) Gentamicin microspheres for infection prophylaxis in the rabbit spine. 53rd Orthopaedic Research Society (ORS) Meeting. San Diego CA 10-14.
3. Dennis H, Wei DT, Darren KZ, Shantakumar JT, Kumar N, et al. (2016) Is Intraoperative Local Vancomycin Powder the Answer to Surgical Site Infections in Spine Surgery? Spine 2016.
4. Martone WJ, Nichols RL (2001) Recognition, Prevention, Surveillance, and Management of Surgical Site Infections: Introduction to the Problem and Symposium Overview. Clinical Infectious Diseases 33: S67-S68.
5. Bakhsheshian J, Dahdaleh NS, Lam SK, Savage JW, Smith ZA (2015) The use of vancomycin powder in modern spine surgery: Systematic review and meta-analysis of the clinical evidence. World neurosurgery 83: 816-823.
6. Schimmel JJ, Horsting PP, de Kleuver M, Wonders G, van Limbeek J (2010) Risk factors for deep surgical site infections after spinal fusion. Eur Spine J 19: 1711-1719.
7. Klevens RM, Morrison MA, Nadle J, Petit S, Gershman K, et al. (2007) Invasive methicillin resistant *Staphylococcus aureus* infections in the United States. JAMA 298: 1763-1771.
8. Neoh HM, Hori S, Komatsu M, Oguri T, Takeuchi F, et al. (2007) Impact of reduced vancomycin susceptibility on the therapeutic outcome of MRSA bloodstream infections. Ann Clin Microbiol Antimicrob 6: 13.
9. Hanssen AD (2005) Local antibiotic delivery vehicles in the treatment of musculoskeletal infection. Clin Orthop Relat Res 2005: 91-6.
10. Strom RG, Pacione D, Kalthorn SP, Frempong-Boadu AK (2013) Lumbar laminectomy and fusion with routine local application of vancomycin powder: decrease infection rate in instrumented and non-instrumented cases. Clin Neurol Neurosurg 115: 1766-1769.
11. Sweet FA, Roh M, Sliva C (1976) Intra-wound application of vancomycin for prophylaxis in instrumented thoracolumbar fusions: efficacy, Drug levels, and patient outcomes. Spine 36: 2084-288.
12. Tarpada SP, Morris MT, Burton DA (2016) Spinal fusion surgery: A historical perspective, Journal of Orthopedics 14: 134-136.

13. Jimenez-Mejias ME, deDios CJ, Sanchez-Lora FJ, Palomino-NicásJ, Reguera JM, et al. (1999) Postoperative spondylodiscitis: Etiology, clinical findings, prognosis and comparison with non-operative pyogenic spondylodiscitis. *Clin InfectDis* 29: 339-345.
14. Silber JS, Anderson DG, Vaccaro AR, Anderson PA, Mc Cormick P (2002) Management of post procedural discitis. *Spine* 2: 279-287.
15. Bassewitz HL, Fishgurd JS, Herkowitz HN (2000) Postoperative spine infections. *Semin Spine Surg* 12: 203-211.
16. Keller RB, Pappas AM (1972) Infection after spinal fusion using internal fixation instrumentation. *Orthop Clin North Am* 3: 99-111.
17. Massie JB, Heller JG, Abitbol JJ, McPherson D, Garfin SR (1992) Postoperative posterior spinal wound infections. *Clin Orthop* 1992: 99-108.
18. Carragee EJ (1997) Pyogenic vertebral osteomyelitis. *J Bone Joint Surg Am* 79: 874-880.
19. Clark NM, Hershberger E, Zervos MJ, Lynch JP (2003) Antimicrobial resistance among gram-positive organisms in the intensive care unit. *Curr Opin Crit Care* 9: 403-412.
20. Olsen MA, Mayfield J, Laurysen C, Polish LB, Jones M, et al. (2003) Risk factors for surgical site infection in spinal surgery. *J Neurosurg* 98: 149-155.
21. Olsen MA, Nepple JJ, Riew KD, Lenke LG, Bridwell KH, et al. (2008) Risk factors for surgical site infection following orthopaedic spinal operations. *J Bone Joint Surg Am* 90: 62-69.
22. Dryden DM, Saunders LD, Rowe BH, May LA, Yiannakoulias N, et al. (2004) Utilization of health services following spinal cord injury: a 6-year follow-up study. *Spinal Cord* 42: 513-525.
23. LaPorte DM, Hungerford MW, Eck K, Bridwell KW, Lenke LG (2000) Deep wound infection after neuromuscular scoliosis surgery. *Spine* 25: 2461-2466.
24. Heggeness MH, Esses SI, Errico T, Yuan HA (1993) Late infection of spinal instrumentation by hematogenous seeding. *Spine* 18: 492-496.
25. Richards BS, Herring JA, Johnston CE, Birch JG, Roach JW (1994) Treatment of adolescent idiopathic scoliosis using Texas Scottish Rite Hospital instrumentation. *Spine* 19: 1598-1605.
26. Horowitz NH, Curtin JA (1975) Prophylactic antibiotics and wound infections following laminectomy for lumbar disc herniation. *J Neurosurg* 43: 727-731.
27. O'Neill KR, Smith JG, Abtahi AM, Archer KR, Spengler DM, et al. (2011) Reduced surgical site infections in patients undergoing posterior spinal stabilization of traumatic injuries using Vancomycin powder. *The Spine Journal* 11: 641- 646.
28. Scheverin N, Steverlynck A, Castelli R, Soberero D, Kopp NV, et al. (2015) Prophylaxis of surgical site infection with vancomycin in 513 patients that underwent to lumbar fusion. *Coluna/ Columna* 14: 3.