

Case Report

DOI: 10.29011/2575-9760.001216

Lung Cancer Arising in A Segment with an Anomalous Bronchus and Its Occurrence in Japan

Hiroyuki Miura^{1*}, Shinichi Goto², Jun Miura³

¹Department of Thoracic Surgery, Akiru Municipal Medical Center, Tokyo, Japan

²Department of Respiratory Medicine, Akiru Municipal Medical Center, Tokyo, Japan

³Department of Surgery, Kyorin University School of Medicine, Tokyo, Japan

*Corresponding author: Hiroyuki Miura, Department of Thoracic Surgery, Akiru Municipal Medical Center, 78-1 Hikida, Akiruno city, Tokyo 197-0834, Japan. Tel: +81-425580321; Fax: +81-425595734; Email: arowana@akiru-med.jp

Citation: Miura H, Goto S, Miura J (2019) Lung Cancer Arising in A Segment with an Anomalous Bronchus and Its Occurrence in Japan. J Surg 12: 1216. DOI: 10.29011/2575-9760.001216

Received Date: 26 April, 2019; **Accepted Date:** 07 May, 2019; **Published Date:** 13 May, 2019

Abstract

Lung cancer seldom arises from an area that contains an anomalous bronchus. A 79-year-old female patient had p-stage IIIA (T2aN2M0) lung adenocarcinoma. A 3D-CT showed the splitting of the right B1+3 and B2 bronchi. The A1, A2, and A3 were branching individually. Bronchial toilet was needed for three days after the right upper lobectomy. Among the 33 reported patients in Japan, far more patients had dislocated bronchi (n=30) than aberrant bronchi (n=3). The most common split bronchus was the right upper bronchus (n=15). There were two cases of right branching anomaly resembling left bronchial branching and 4 cases of left branching anomaly resembling right bronchial branching. Pulmonary artery abnormality occurred in 5 of these 6 cases. A 3D-CT examination of the lung should be performed preoperatively to avoid accidental amputation of pulmonary vessels. Furthermore, complication management should take into account the displacement of the remaining bronchus.

Keywords: 3D-CT; Anomalous bronchus; Displaced bronchus; Lung cancer

Introduction

Anomalous bronchi are rare conditions and are mostly observed in the right upper lobe. Lung cancers originating from anomalous bronchi are also rare. We should plan the lobectomy for lung cancer associated with an anomalous bronchus after locating the anomalous pulmonary arteries and pulmonary veins. Careful preoperative examinations, including assessment of vascular flow, are needed.

Case Report

A 79-year-old female patient presented with an abnormal shadow on a chest X-ray during an annual checkup. The patient had had an appendectomy at age 30 and oophorectomy for a benign ovarian tumor at age 32. She was a nonsmoker. According to a blood examination including hemogram, she had normal renal and hepatic function, high serum level of Carcinoembryonic Antigen (CEA) (17.0 ng/mL), and normal serum levels of Cytokeratin 19 Fragment (Cyfra) and Pro-Gastrin Releasing Peptide (proGRP).

There were no abnormal findings on electrocardiography. The chest Computed Tomography (CT) showed an ill-defined nodule about 30 mm in diameter with a pleural indentation in the right S3b area. Swelling of one #4R lymph node raised suspicion of metastasis. Fiberoptic bronchoscopy located the right tracheobronchial branch B1+3 at the orifice of the right main bronchus. The right B2 was a branch from the intermediate bronchus. The 3D-CT showed the right B1+3 branching from the orifice of the right main bronchus, the right B2 branching from the intermediate bronchus, and the A1, A2, and A3 branching individually. There was no anomaly of the right pulmonary vein. Pulmonary function was normal. There were no distant metastases. Right upper lobectomy was planned under the diagnosis of cT2a(PL1) N2(single station) M0. The operation was performed under thoracoscopic guidance through a mini thorotomy. Then ND2a-2 lymph nodes dissection was performed. Pathologically, the tumor (30 × 23 × 20 mm) with p11 pleural invasion was characterized as a solid adenocarcinoma. Metastases were observed at the #4R and #12u lymph nodes. The pathological stage was IIIA (T2aN2M0). As the sputum accumulated, bronchial toilet using a bronchoscope was needed for three days after the surgery (Figure 1).

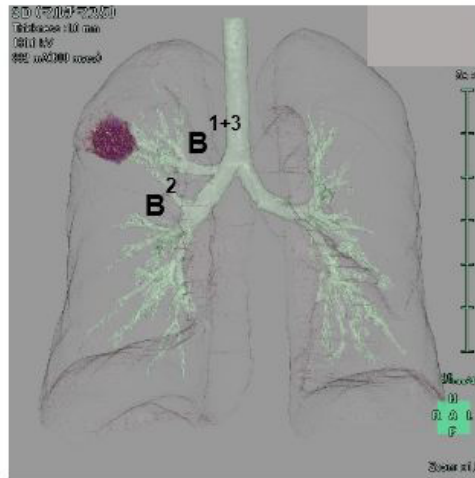


Figure 1: 3D-CT The right B1+3 branching from the orifice of the right main bronchus and the right B2 branching from the intermediate bronchus.

Discussion

Supernumerary bronchi, displaced bronchi, and congenital cystic disease are regarded as bronchial abnormalities by Foster-Carter [1], while others treat the first two as bronchial abnormalities and consider congenital cystic disease as an independent disease. Displaced bronchus has been reported 7.2 times more frequently than supernumerary bronchus [2]. We studied reported cases of cancer arising from a lung segment drained by an anomalous bronchus in Japan [3-5] (Table 1).

Type	Lobes	Dislocated bronchi	OP methods						Total	Vascular a.		
			RUL	RUML	RUsl	S1+3	RLL	S6a		PA	PV	
R	Dis.	Upper	B1,B2+3	5	1	1			7	20	2	1
			B1+3,B2	5			2		7		1	1
			B1-3		1	1			2			
			B4+5 & B1-3 common tr.		2				2		2	
			B1+2,B3			1			1			
	Lower	B6a						1	1			
Sup.	Lower	ACB					2	2	2			
Type	Lobes	Dislocated bronchi	OP methods				Total	Vascular a.				
			LUL	LUdiv	S1+2	LP		PA	PV			
L	Dis.	Upper	B1+2a				1	1	10			
			B1+2	4		1		5			1	
			B4+5		4			4		3		
	Sup.	Upper	B4→S3	1				1	1			

R: Right; OP methods: Operation Methods; RUL: Right Upper Lobectomy; RUML: Right Upper and Middle Lobectomy; RUsl: Right Upper Sleeve Lobectomy; RLL: Right Lower Lobectomy; S6: Right S6 Segmentectomy; Vascular a: Vascular Anomalies; PA: Pulmonary Artery; PV: Pulmonary Vein; tr: truncus; Dis: Displaced Bronchi; Sup: Supernumerary Bronchi; L: Left; LUL: Left Upper Lobectomy; LUdiv: Left Upper Division Segmentectomy; S1+2, S1+2 segmentectomy; LP: Left Pneumonectomy.

In all, 33 lung cancers including 19 adenocarcinomas, 13 squamous cell carcinomas, and one large cell neuroendocrine carcinoma were diagnosed in 19 male and 14 female patients ranging in age from 39 to 83 years (mean 63.9). The tumors occurred on the right side twice as often than on the left side (22 vs 11 cases) and occurred far more often in displaced bronchi than in supernumerary bronchi (30 vs 3 cases). Most of the tumors were located at divided bronchi in the right upper lobe bronchus (n=15). The displaced bronchus in these 15 cases was divided into B1 and B2+3 (n=7) and B1+3 and B2 (n=7). In two cases, the whole right upper lobe bronchus had branched from the trachea. At the left bronchus, the most frequently occurring anomaly was B1+2 branching from the left main bronchus independently (n=5). The right branching anomaly resembling the left lung bronchus, i.e., the upper lobe bronchus and the middle lobe bronchus join into a common trunk, occurred in two cases. On the contrary, the left branching anomaly resembling the right lung bronchus, i.e., the lingual bronchus separates from the lower lobe, occurred in 4 cases. Pulmonary artery abnormality was observed in 5 of these 6 cases. The right pulmonary artery passed behind the right main bronchus, and the left pulmonary artery traveled in front of the left main bronchus. That is, the left bronchus developed the branching pattern of the right bronchus. Therefore, the left pulmonary artery also developed the branching pattern of the right pulmonary artery. The operative method for correcting this right lobe abnormality was right upper and middle bilobectomy, which resembles left upper lobectomy. That of these left abnormalities was segmentectomy, which is similar to right upper lobectomy (Table 1).

The coexistence of vascular anomaly complicates surgery for lung cancer with an anomalous bronchus. To avoid unintended amputation of the pulmonary vessels, a preoperative 3D-CT examination of the lung is recommended. The second problem is lymph flow around the abnormal bronchus. Appropriate lymph nodes dissection is required and should take into account lymph flow. The number of lymph nodes such as at sites of the dislocated bronchi, the right B1+3 and B2, is unknown. The third problem is postoperative complications. As sputum accumulated, our patient needed bronchial toilet. This difficulty with clearing sputum may be due to dislocation of the remaining bronchus.

Conclusions

Anomalous bronchus is often accompanied by pulmonary vessel abnormalities. Therefore, 3D-CT of not only the bronchus but also the pulmonary vessels should be performed preoperatively to avoid unwarranted amputation of the pulmonary vessels. Furthermore, complication management should be implemented and take the displacement of the remaining bronchus into consideration.

References

1. Foster-Carter AF (1946) Broncho-pulmonary abnormalities. *Br J Tuberc* 40: 111-124.
2. Ohta S, Saito Y, Usuda K, Kanma K, Sagawa M, et al. (1986) Trachio-bronchial anomalies: Report of 71 cases. *J Jpn Soc Bronchology* 8: 122-130.
3. Hashimoto O, Yamaguchi A, Fujimoto T (2005) Squamous cell lung cancer associated with an anomaly of the right upper lobe bronchus. *JJLC* 45: 367-372.
4. Fujishita T, Okamoto T, Suzuki Y, Kitahara H, Shimamatsu S, et al. (2014) A rare case of a bronchial anomaly running in the hilar region from the right lower lobe to the middle lobe. *Fukuoka Acta Med* 105: 100-104.
5. Tajima K, Uchida N, Sasamoto H, Okada T, Kohri T, et al. (2016) lung adenocarcinoma with anomalous bronchi and pulmonary veins pre-operatively identified by computed tomography. *Thoracic cancer* 7: 599-601.