

## Image Article

### Hb Bart's Hydrops Fetalis

I-Hsin Lin<sup>1</sup>, Yu-Hui Tsai<sup>1</sup>, Jung-Li Ho<sup>1</sup>, Chi-Man Kuok<sup>2\*</sup>

<sup>1</sup>Department of Clinical Pathology, Far Eastern Memorial Hospital, New Taipei, Taiwan

<sup>2</sup>Department of Pediatrics, Far Eastern Memorial Hospital, New Taipei, Taiwan

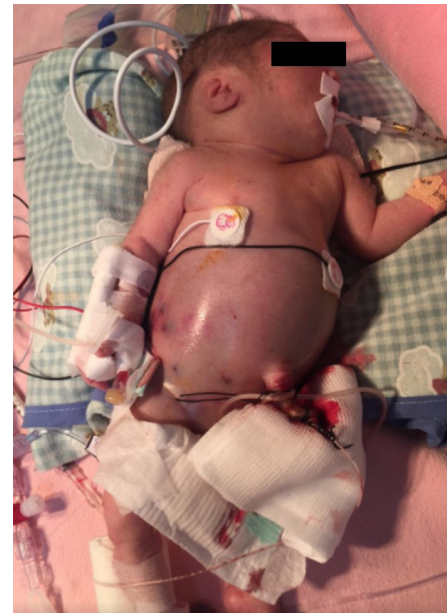\***Corresponding author:** Chi-Man Kuok, Department of Pediatrics, Far Eastern Memorial Hospital, Nanya S. Road, Banqiao, New Taipei City, Taiwan. Tel: +886-289667000; Email: carmentoe@hotmail.com

**Citation:** Lin IH, Tsai YH, Ho JL, Kuok CM (2019) Hb Bart's Hydrops Fetalis. J Urol Ren Dis 11: 1143. DOI: 10.29011/2575-7903.001143

**Received Date:** 23 April, 2019; **Accepted Date:** 03 May, 2019; **Published Date:** 07 May, 2019

#### Case Description

A gestational age 29-week and body weight 1,425-gram baby was born by a 33-year-old mother at her 2nd gestation with acute onset of vaginal hemorrhage. Tocolysis was given but symptoms persisted before preterm labor, and edematous placenta was noticed when delivery. After delivery, baby was no spontaneous crying and no spontaneous respiration. Apgar scores were 1, 1 and 1 at 1, 5 and 10 minutes, respectively. The initial vital signs of the baby under ventilator support were as follow: body temperature 34.7 degree Celsius, heart rate 102 beats per minute respiratory rate 15 cycles per minute and blood pressure 39/29 millimeters of mercury. Generalized cyanosis and edema were noticed found on physical examination (Figure 1). Massive ascites without hepatosplenomegaly was observed with bilateral pleural effusions but no obvious cardiac abnormalities or pericardial effusion by ultrasonography. Ascites and left pleural effusion were tapping. Resuscitation with fluid hydration and inotropic medications as well as intubation was performed due to unstable hemodynamics. However, profound desaturation with metabolic acidosis aggravated and the baby eventually expired approximately 6 hours after birth.



**Figure 1:** The newborn appeared to be generally edematous, particularly in the abdomen.

Reviewing the parents' histories, both parents were found to have microcytic anemia without iron deficiency on laboratory examination. Poikilocytosis with teardrop cells, target cells and ovalocytes was seen in the blood films of both parents. Red cells with HbH inclusion bodies were also found by modified brilliant cresyl blue stain in both parents. The complete blood cell analysis of the baby revealed a hemoglobin level of 9.6 g/dl with mean corpuscular volume of 104.8 fl. The capillary zone electrophoresis of hemoglobin revealed predominant Hb Bart's (86.5%), accompanied with HbH (1.8%), Hb Epsilon 4 (0.7%), Hb Gower 1 (3.4%) and Hb Portland (6.8%) (Figure 2). Furthermore, karyotyping for chromosome abnormalities and genetic studies for alpha globin of the baby were suggested but the parents hesitated and refused. Hb Bart's Hydrops Fatalism (HBHF) was impressed.

## Discussions

HBHF is the most severe form of alpha thalassemia in which all four alpha globins are involved, leading to underproduction and even absence of alpha globins. Thus, Hb Bart's develops from the tetramer formation of gamma globins in HBHF. Although some cases with HBHF could have the hemoglobin level up to 10 g/dl based on the presence of Hb Bart's and Hb Portland [1], they are severely anemic in function and universally unable to survive at birth. Hemoglobin electrophoresis helps in diagnostic establishment of HBHF, in which the predominance of Hb Bart's (up to 80% and more) could be used for differential diagnosis from other alpha thalassemia-associated disorders [2]. In genetic studies, homozygous Southeast Asian (SEA) deletion or SEA deletion accompanied with other deletion type involved with two alpha genes is the most common deletion type of alpha thalassemia in Asian countries [3,4]. Over these decades, development of intrauterine management of transfusion or Hematopoietic Stem Cell Transplantation (HSCT) as well as postnatal HSCT successfully has saved certain cases of HBHF [4,5], although significant growth and neurodevelopmental impairment were complicated in these HBHF survivors [4]. In conclusion, thalassemia survey for both parents with meticulous antepartum surveillance is warranted for prevention of HBHF in prenatal development.

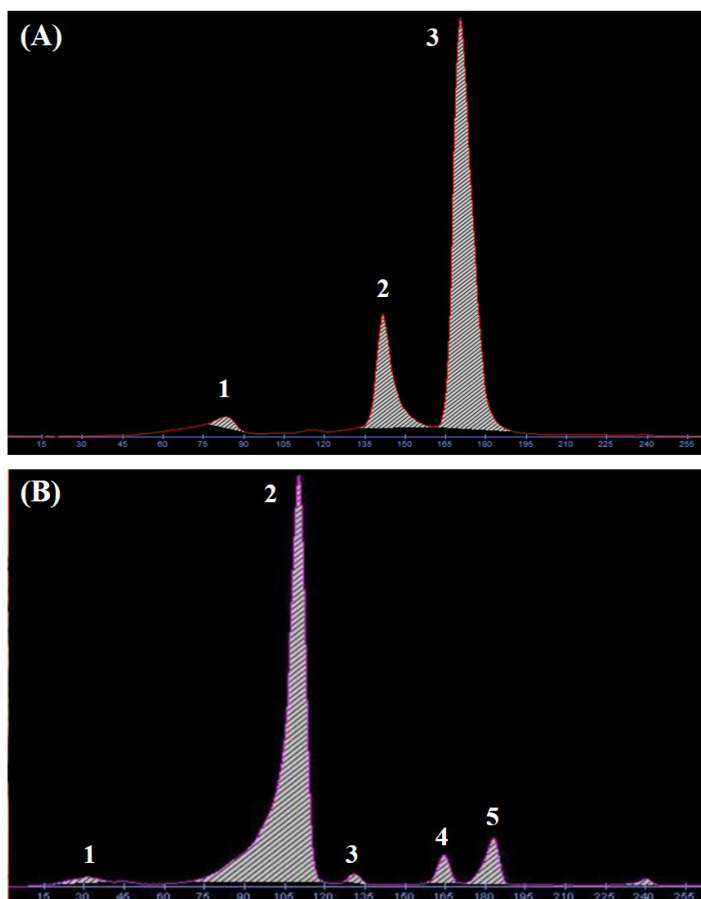
## Author Contribution

I-Hsin Lin and Yu-Hui Tsai contributed to this work equally as co-first authors. Chi-Man Kuok contributed as the corresponding author.

**Conflicts of Interest:** None.

## References

1. Randhawa ZI, Jones RT, Lie-Injo LE (1984) Human hemoglobin Portland II (zeta 2 beta 2). Isolation and characterization of Portland hemoglobin components and their constituent globin chains. *J Biol Chem* 259: 7325-7330.
2. Srivorakun H, Fucharoen G, Sae-Ung N, Sanchaisuriya K, Ratanasiri T, et al. (2009) Analysis of fetal blood using capillary electrophoresis system: a simple method for prenatal diagnosis of severe thalassemia diseases. *Eur J Haematol* 83: 57-65.
3. Songdej D, Babbs C, Higgs DR, BHFS International Consortium (2017) An international registry of survivors with Hb Bart's hydrops fetalis syndrome. *Blood* 129: 1251-1259.
4. Ahmad R, Saleem M, Aloysious NS, Yelumalai P, Mohamed N, et al. (2013) Distribution of alpha thalassaemia gene variants in diverse ethnic populations in malaysia: data from the institute for medical research. *Int J Mol Sci* 14: 18599-18614.
5. Pongtanakul B, Sanpakit K, Chongkolwatana V, Viprakasit V (2014) Normal cognitive functioning in a patient with Hb Bart's hydrops successfully cured by hematopoietic SCT. *Bone Marrow Transplant* 49: 155-156.



**Figure 2:** (A): Normal pattern of the capillary zone electrophoresis of hemoglobin in a newborn. The number 1 to 3 indicated Hb Bart's, Hb A and Hb F in sequence; (B): Predominance of Hb Bart's was shown in hemoglobin electrophoresis of this newborn. The number 1 to 5 indicated Hb H, Hb Bart's, Hb Epsilon 4, Hb Gower 1 and Hb Portland in sequence.