

Case Report

Syndromic Faces

Siccandar Jeelani M.D.S., Reader*, Suresh Babu Suganya B.D.S., Tutor

Department of Oral Medicine and Radiology, Sri Venkateshwara Dental College, India

*Corresponding author: Siccandar Jeelani, Department of Oral Medicine and Radiology, Sri Venkateshwara Dental College, Ariyur, Puducherry, India. Tel: +919943047572; Email: jeelani1978_s@rediffmail.com

Citation: Jeelani S, Suganya SB (2017) Syndromic Faces. J Surg: JSUR-191. DOI: 10.29011/2575-9760.000091

Received Date: 30 November, 2017; Accepted Date: 04 December, 2017; Published Date: 11 December, 2017

Introduction

An "ideal beauty" often involves the interpretation of some entity as being in balance and harmony with nature. The earliest Western theory of beauty can be found in the works of early Greek philosophers from the pre-Socratic period, such as Pythagoras. The Pythagorean School saw a strong connection between mathematics and beauty. In particular, they noted that objects proportioned according to the golden ratio seemed more attractive. Ancient Greek architecture is based on this view of symmetry and proportion. Modern research also suggests that people whose facial features are symmetric and proportioned according to the golden ratio are considered more attractive than those whose faces are not. Symmetry is also important because it suggests the absence of genetic or acquired defects. Although style and fashion vary widely, cross-cultural research has found a variety of commonalities in people's perception of beauty. Large eyes and a clear complexion, for example, are considered beautiful in both men and women in all cultures. Neonatal features are inherently attractive and youthfulness in general is associated with beauty.

However, when the symmetry and proportion are not in balance and harmony with nature then disfigurement results which may be due to various causes of which those resulting from pathology due to syndromes contribute an important reason for loss of beauty. The word Syndrome is derived from Greek language and it literally means Running together. The term syndrome has been applied to collection of signs, to groups of symptoms, and to mixed assortments of signs and symptoms. The term refers to a group of manifestations when cause is poorly understood. Some use the term syndrome for multiple anomalies of genetic origin.

Occasionally, the term syndrome is applied to the more severe end of a spectrum that grades into normal such as the fetal alcohol syndrome. Syndromologists frequently postulate, discuss, and write about "New syndromes". The term has various shades of meaning. A common meaning for a "New syndrome" is a condition that has always existed but has only recently been recognized as an entity. Sometimes the condition is remarkably well described in the older literature unbeknownst to the syndromologist who proposed the "New syndrome". When this happens, the "new syndrome" simply represents a "rediscovered syndrome" Finally, some new syndromes are genuinely new at the time of their discovery, e.g., the thalidomide syndrome; the syndrome per se did not exist prior to the marketing of the drug.

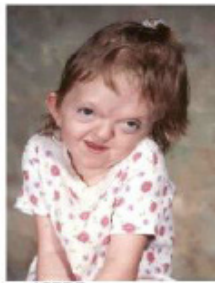Syndromic Faces

Apert's syndrome

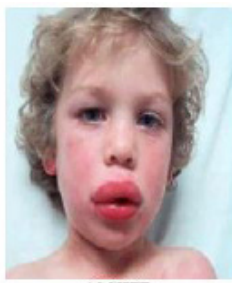It is a rare syndrome which was mentioned as early as 1842 by Baumgartner and Wheaton in 1894, though the eponymic credit is given to Apert for his presentation of the syndrome in 1906. It seems to be transmitted by an autosomal dominant Gene. Several etiologic hypothesis have been proposed which include Virus embryopathy following maternal infection, excessive production of cerebrospinal fluid in embryonic life.

Systemic manifestations: Face: The middle third of the face appears flat and underdeveloped producing the relative prognathism. The nose is small, and parrot shaped. Hypertelorism, strabismus and proptosis of eyes are noted. Skull: The cranium has a characteristic oxycephalic appearance with a high prominent steep forehead. [1,2].

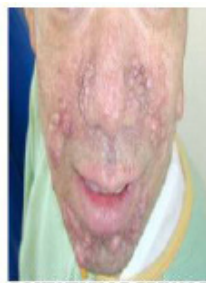Images [3,4,5]



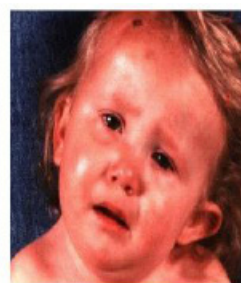APERT



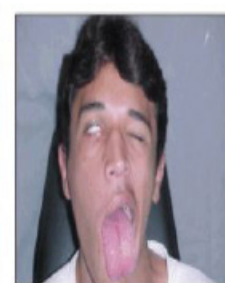ASCHER




BOURNEVILLE-PRINGLE



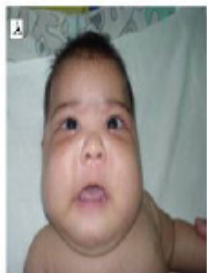KLIPPEL- FEIL



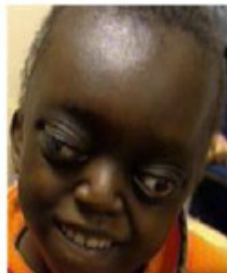MARCUS GUNN



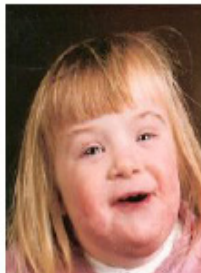PARRY-ROMBERG



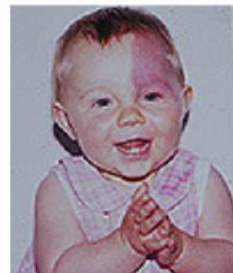CAFFEY - SILVERMAN



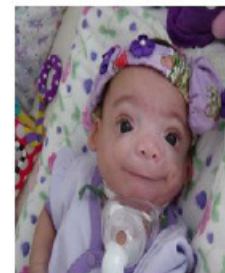CROUZON



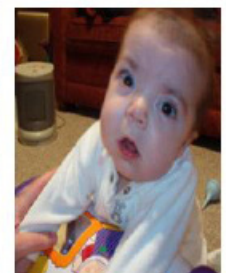
DOWN'S




STURGE-WEBER



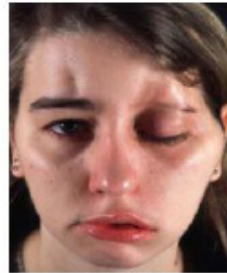
TREACHER COLLINS



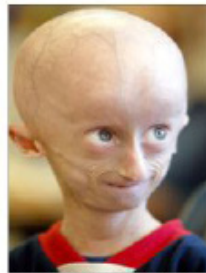HURLER



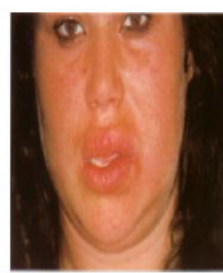
EHLERS-DANLOS



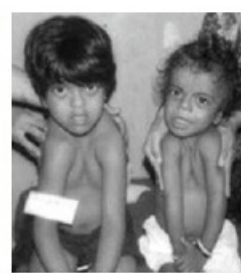CURTIS



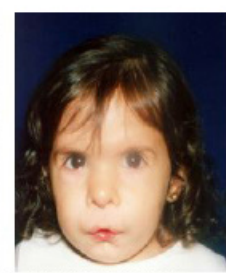HUTCHINSON-GILFORD



MELKERSSON-ROSENTHAL



SCHUTHAUER-MARIE-SAINTON



WHISTLING FACE

Aschers syndrome

This syndrome was first described in 1909 by Laffler as a combination of double lip and blepharochalasis and later in 1920 nontoxic thyroid enlargement was added to this syndrome by Ascher.

Systemic manifestations: Face: (Eyes & Lips): Sagging of upper eyelids. The atrophy and drooping of the eyelid often follow repeated angioneurotic edema like episode. Thyroid: Enlargement of thyroid gland without toxic symptoms usually appear after eyelid involvement

Bourneville-Pringle syndrome (Epiloia, Tuberous sclerosis)

Tuberous sclerosis is a neuro cutaneous syndrome which was first recorded by Von Recklinghausen, however Bourneville and Pringle are credited with the classic description of epilepsy, mental deficiency and adenoma sebaceum. Most patients die before they are 20 years old, but some survive into middle age. It is an autosomal dominant condition possibly related to an effect on chromosome.

Systemic manifestations: Adenoma sebaceum is characteristic of this syndrome. Skin: Subungual fibromas are present. CNS: Intracranial calcifications, seizures are present [1,2].

Caffey - Silverman syndrome (Infantile Cortical Hyperostosis, Smyth's Syndrome)

It was first described in 1930 by Roske, however the clinical and roentgenographic features was brought to attention by Caffey, Silverman and Smith in 1945. It is an autosomal dominant condition and its etiology has been suggested that it was caused by a congenital anomaly of the vessels supplying the periosteum of the involved bone, the hypoxia effecting a focal necrosis of the overlying soft tissues and resulting in new periosteal bone formation. The average onset of this syndrome is 9 weeks. It is characterized by – Bilateral swelling over the mandible or other bones, Roentgenographic evidence of new bone formation in this area, Hyperirritability and Mild fever.

Systemic manifestations: Symmetrical swelling over the face located over the body and ramus of the mandible. Skeletal system:

The most frequently affected bone is mandible. Others involved are clavicle, tibia, ulna. The new periosteal bone formation appears mostly during 9th week and undergoes resolution by around 9 months, however roentgenographic evidence may persist for many years.

Crouzon's syndrome (Craniofacial Dysostosis)

It was first described by Crouzon in 1912. It is an autosomal dominant condition with a suggested etiology that at birth the sutures of the cranial bones were inflamed causing premature closure of fontanelles, early bone synostosis and a latent period of cranial bone growth.

Systemic manifestations: Exophthalmos, Hypertelorism, Hypoplasia of maxilla are present. Large frontal bony swelling is present. The hypoplastic maxilla gives the patient a frog like appearance [1]. Roentgenographically the coronal, sagittal and lambdoid sutures are prematurely synostosed in most of cases. Digits: Syndactyly may be present [1,2].

Down's syndrome (Trisomy 21)

Down syndrome or trisomy 21 is a chromosomal disorder caused by the presence of all or part of an extra 21st chromosome. It is named after John Langdon Down, the British doctor who described the syndrome in 1866. The disorder was identified as a chromosome 21 trisomy by Jérôme Lejeune in 1959. The condition is characterized by a combination of major and minor differences in structure. Often Down syndrome is associated with some impairment of cognitive ability and physical growth as well as facial appearance. Down syndrome can be identified during pregnancy or at birth.

Systemic manifestations: Individuals with Down syndrome tend to have a lower than average cognitive ability, often ranging from mild to moderate learning disabilities. A small number have severe to profound mental disability. The incidence of Down syndrome is estimated at 1 per 800 to 1,000 births, although these statistics are heavily influenced by the age of the mother. Other factors may also play a role. Many of the common physical features of Down syndrome also appear in people with a standard set of chromosomes. They may include a single transverse palmar crease (a single instead of a double crease across one or both palms, also called the Simian crease) Eyes: An almond shape to the eyes caused by an epicanthic fold of the eyelid, upslanting palpebral fissures and brushfield spots. Other Features: Shorter limbs, poor muscle tone, a larger than normal space between the big and second toes [1,2].

Ehlers-Danlos syndrome (Cutis hyper elastica, Indian rubber man)

This syndrome was first described in the 17th century by Van Meekeren, however complete description was given by Ehlers-Danlos (Dermatologist) in 1901. It is an autosomal dominant trait common in males.

Systemic manifestations: Skin: Hyperelastic Skin especially over major joints. After being stretched it returns to its normal position. The skin is also fragile and minimal trauma causes gaping wounds. Musculoskeletal system: Hyperextensibility of joints and habitual dislocation of joints are characteristic [1,2].

Hemifacial or Unilateral hypertrophy (Curtius syndrome / Steiner's syndrome)

It was first noticed by Meckel in 1822, then by Wagner in 1839 however it was recognized as a syndrome by Gessel & Lestrup in 1920. Gessel suggested that it resulted from deviation in the process of twinning. Males are more commonly affected. The asymmetry is almost always evident at birth however in some cases more accentuated at puberty and once developed it appears to be constant.

Systemic manifestations: Face: Facial involvement varies greatly. In some patients only the face is affected. In others unilateral facial enlargement is accompanied by enlargement of half of the body. The degree involvement varies from one that is barely noticeable to one that causes monstrous distortion. Skin: The skin on the involved side is thicker than normal. Skeletal system: The bones have been found to be unilaterally enlarged. Genitourinary system: The kidney and adrenal glands seem to be most frequently enlarged [1,2].

Hutchinson-Gilford syndrome (Progeria)

It was first described by Hutchinson & Gilford. It is a combination of Dwarfism, immaturity and Pseudosenility. Because of a peculiar form of hyper metabolism, persons with this affliction succumb to old age and die of coronary disease during their middle teens.

Systemic manifestations: Face & Appearance: It is disproportionately small giving the head a hydrocephalic appearance. The ears are small without lobules. The nose is beaked giving a bird facies. Eyebrows and occasionally eyelashes are lost. Scalp hair is lost and replaced by a downy fuzz, giving a newly hatched bird appearance. The chest is narrow and the abdomen protruberant [1,2].

Klippel- Feil syndrome (Brevicollis, Congenital Synostosis of Cardiothoracic Vertebrae, Congenital Osseous Torticollis)

It was first described by Klippel and Feil in 1912. It is an autosomal dominant condition more common in females. The suggested etiology is faulty segmentation of the mesodermal somites sometimes between the third and seventh weeks in utero. A defect in maternal intestinal tract and fetal foregut has also been proposed. The syndrome consists of – Fusion of some, or even all, cervical vertebrae; Shortness of neck, with painless limitation of head movement & low posterior hairline.

Systemic manifestations: Face: The whole head seems to sit directly on the thorax, without an interposing neck [3]. The flaring trapezius muscles extend from the mastoid area to the shoulders producing a pterygium like effect. Posteriorly the hairline extends to the shoulders. Musculoskeletal system: Characteristically two or more occasionally all cervical vertebrae are fused into a solid mass. Thoracic vertebrae may be occasionally involved [1,2].

Marcus Gunn's and Inverse Marcus Gunn's syndromes (Jaw-Winking and Winking-Jaw Syndromes Pterygoid-Levator Synkinesis and Corneomandibular Reflex)

Marcus Gunn in 1883, described the syndrome as consisting of (a) unilateral congenital ptosis and (b) rapid exaggerated elevation of the ptotic lid of moving the lower jaw to the contralateral side, stimulated immediate interest in this problem the name "jaw-wink" syndrome is not well chosen for the symptom not a wink but an exaggerated opening of the eye. However, the term has been used so long and extensively that until the cause is clarified, might be best to continue its use. The cause is unknown, but it was originally assumed that the syndrome was based on aberrant innervations of the levator palpebrae superioris from the motor branch of the trigeminal because of the close approximation of the nuclei of the third and fifth cranial nerves. However, a supra nuclear, or at least a combined supra nuclear- nuclear, involvement has also been suggested.

Systemic manifestations: Face: Ptosis of one eyelid. Eyes: The left eye is commonly affected by ptosis. Jaws: Depression or movement of the jaw to the contralateral side results in opening of the ptotic eyelid [1,2].

Parry-Romberg syndrome (Progressive Hemifacial Atrophy)

This syndrome was first described by Parry & Romberg in 1825 & 1846 respectively. It is an autosomal dominant condition. It consists of slowly progressive atrophy of the soft tissues of essentially half the face, accompanied most often by contralateral Jacksonian epilepsy, by trigeminal neuralgia & by changes in hair and eyes. Occasionally there may be associated atrophy of half the body. The suggested etiology irritation in the peripheral trophic sympathetic system [4].

Systemic manifestations: Face: Asymmetry noted [1,2].

Sturge-Weber syndrome (Encephalotrigeminal angiomas)

This syndrome was first described by Sturge and Weber in 1897 & 1922. It consists of – a) Venous angioma of leptomeninges overlying the cerebral cortex with ipsilateral angiomatous lesions of face b) ipsilateral gyriform calcifications of the brain c) epilepsy d) mental retardation e) ocular involvement and f) contralateral hemiplegia.

Systemic manifestations: Brain: Intracranial convolutional gyriform calcifications that develops after second year, which ap-

pears radiographically as double contoured lines – Tram line calcifications which is pathognomonic for this syndrome. Face: Ipsilateral to cerebral angiomatosis a nevus flammeus (portwine stain) commonly occurs on the face. It is present at birth and is mostly unilateral in the course of trigeminal nerve. Nervous system: The seizures are contralateral to angiomatosis and mostly focal.

Treacher Collins' syndrome (Mandibulofacial Dysostosis, Franceschetti-Zwahlen-klein Syndrome, Bilateral Facial Agenesis)

This syndrome was first described by Treacher Collins and Franchetti in 1846 and 1940 respectively. It is an autosomal dominant condition. The suggested etiology is incorrect development of blood relay (from the remains of first aortic arch to stapodial artery to external carotid artery)

Systemic manifestations: Face: Downward sloping palpebral fissures, depressed cheek bones, deformed pinna, receding chin, large fish like mouth, tongue shaped process of hair that extends towards cheek [1,2].

Hurler's syndrome (Mucopolysaccharidosis 1 Gargoylism Hunter- Hurler-Pfaundler Dysostosis Multiplex)

It was first described by Hunter and Thompson in 1900 and then by Hurler in 1919. It is an autosomal recessive and x- linked recessive condition. It consists of – Characteristic grotesque skeletal deformities, mental retardation, hepatosplenomegaly, corneal clouding, deafness and cardiac anomaly.

Systemic manifestations: Face: Large head with a prominent forehead. Hypertelorism, heavy lids, flat nasal bridge, prominent tongue with open mouth and a short broad neck [1,2].

Melkersson-Rosenthal syndrome (Miescher's Cheilitis Granulomatosa, Idiopathic Fibroedema, Recurrent Edema-bound Granulomatosis)

This syndrome was first described by Melkerson in 1928 with a clinical feature of facial paralysis and swelling of the faces. In 1938, Rosenthal added the third clinical sign – lingua plicata. Various etiologies were proposed for the facial swelling such as – angioneurotic phenomenon (disturbance of the regulation of vasomotor nerves); stress factors relating to unstable autonomic nervous system; hematogenously spread toxemia; toxoplasmosis.

Systemic manifestations: Face: Swelling of the lips (usually upper) either unilaterally or bi-laterally is the dominant feature of this syndrome which begins suddenly in most cases prior to but sometimes after or simultaneously with facial paralysis. The edema is reddish brown in colour, non-tender and non-fitting [1,2].

Scheuthauer-Marie-Sainton syndrome (cleidocranial dysostosis)

This syndrome was first described by Scheuthauer, Marie &

Sainton in 1897. It is an autosomal dominant condition. It consists of – Aplasia or Hypoplasia of 1 or both clavicles, exaggerated development of transverse diameter of cranium & delayed ossification of fontanel.

Systemic manifestations: Face: Brachycephalic skull with frontal and parietal bossing. Clavicle: Unilaterally or bilaterally totally aplastic. This bony defect allows the individual to approximate his shoulders in front of his chest [1,2].

Whistling Face syndrome (Freeman Sheldon syndrome)

This syndrome was first described by Freeman & Sheldon. He reported it in children with Microstomia, increased philtrum length, small nose and nostrils, Lips protruding as in whistling, full cheeks and blepharophimosis with hernia [1,2].

References

1. MM Cohen (1989) Syndromology: an updated conceptual overview. Syndromes concepts, designations and population characteristics. Int J Oral Maxillofac Surg 18: 216-222.
2. Robert J Gorlin and Jens J Pindborg (1964) Syndromes of the Head and Neck.
3. Bork Korting, Young (1996) Diseases of Oral mucosa and lip. In: 2nd edition 1996.
4. Color atlas of Oral diseases. George Laskaris. 3rd edition 2003.
5. Color atlas of Oral diseases in children and adolescents. Crispian Scully & Richard Welbury.